

Mucormycosis in COVID 19 Pandemic; New Challenge: A Review Article

Dr. Sunita^{1*}, Dr. Kamlesh Sharma¹¹Department of Community Medicine, Dr. Yashwant Singh Parmar Government Medical College Nahan, Himachal Pradesh, IndiaDOI: [10.36347/sjams.2021.v09i07.015](https://doi.org/10.36347/sjams.2021.v09i07.015)

| Received: 13.06.2021 | Accepted: 18.07.2021 | Published: 23.07.2021

*Corresponding author: Dr. Sunita

Abstract

Review Article

Mucormycosis is a rare but serious life threatening, angioinvasive fungal infection with high mortality rate. In 2nd wave of pandemic it has been increasing as an opportunistic infection in covid 19 recovered patients. The most common organism is *Rhizopus oryzae* and is responsible for 70% of all cases of mucormycosis. India is dealing a double blow as rapid increase in Covid-19 cases and also with this nasty rare fungal infection. More than 70% cases of mucormycosis are from India. The fatality rate in mucormycosis if patient goes untreated is as high as 80%, If treated, it is still 40-50%. Mucormycosis was predominantly seen in males (79%), both in people who were active (59%) or recovered (41%) from COVID-19. Diabetes was present in 80% of cases, while concomitant diabetic ketoacidosis (DKA) was present in 15% and corticosteroid treatment was given for COVID-19 in 76%. DM has been the most common risk factor linked with mucormycosis and India is the diabetes capital of the world although hematological malignancies and organ transplant takes the lead in Europe and the USA. Treatments need to be fast and aggressive, because by the time even the presumptive diagnosis is made, often the patient has suffered significant tissue damage that cannot be reversed. Liposomal Amphotericin B ($\geq 5\text{mg/kg}$) combined with surgery is the first line therapy for mucormycosis. Due to rapidly growing number of cases many Indian state Governments have declared it an epidemic. Himachal government declared mucormycosis as an epidemic for one year on 21st May 2021 after detection of first case on 20th May 2021.

Keywords: Mucormycosis, Covid 19, Pandemic, Epidemic, Diabetes.

Copyright © 2021 The Author(s): This is an open-access article distributed under the terms of the Creative Commons Attribution 4.0 International License (CC BY-NC 4.0) which permits unrestricted use, distribution, and reproduction in any medium for non-commercial use provided the original author and source are credited.

INTRODUCTION

The novel coronavirus 2019 or severe acute respiratory syndrome coronavirus 2 (SARS-CoV-2) first reported in Wuhan, Hubei province in China, quickly spread to other parts of the world forming a global pandemic [1]. It has been associated with a wide range of opportunistic fungal and bacterial infections [2]. Mucormycosis is one of the emerging life-threatening fungal infection in some of these covid 19 patients, It is also called black fungus and previously it was termed as zygomycosis. Mucormycosis is a rare but serious life threatening angioinvasive, non contagious with high mortality rate caused by a group of molds called mucormycetes. These fungi live throughout the environment, particularly in soil and in decaying organic matter, such as rotten wood leaves or compost piles [3].

The most common organism is *Rhizopus oryzae*, belonging to order Mucorales and is responsible for 70% of all cases of mucormycosis [4-6]. India is dealing with double blow due to increase in Covid-19

cases and also due to horrible and rare fungal infection mucormycosis with more than two thirds cases are from India [7].

This article reviews the evolution, disease burden, pathogenesis, clinical features, epidemiology, prevention and management of mucormycosis. The current situation of global and Indian scenario along with basic protective measures against mucormycosis are reviewed in order to follow up research, prevention and treatment, and to provide latest understanding of this emerging life threatening disease.

Evolution

Mucormycosis is rare but life threatening infection affecting less than 1.7/million population each year. First case of mucormycosis was described by Friedrich Kuchenmeister in 1855 [8]. Furbringer first described the disease in lungs in 1876 [9]. In 1884, Lichtheim established the development of the disease in rabbits and described two species which later known as *Lichtheimia* and *Rhizopus*. Arnold Paltauf coined the

term 'Mycosis Mucorina' in 1885. In 1943, its association with poorly controlled diabetes was reported in three cases with severe sinus, brain and eye involvement [8]. In 1953, it was isolated from Indian forest soil [8] and also has also been reported in natural disaster like 2004 Indian ocean Tsunami and 2011 Missouri tornado [10, 11]. This disease has made an another health emergency in India during COVID-19 pandemic. As of 25th May 2021 the Indian Government reported that more than 11,700 people were receiving care for mucormycosis. Due to its rapidly growing number of cases many Indian state governments have declared it an epidemic and number of cases linked to immunosuppressive treatment for Covid19 [12]. In Himachal Pradesh 1st case of mucormycosis came into noticed on 20th May 2021

Disease Burden

Globally, in 2019-2020 the prevalence of mucormycosis is 0.005 to 1.7 per million population, while its prevalence in India is nearly 80 times higher (0.14 per 1000) compared to developed countries [13-15]. In India, Diabetes Mellitus, has been the most common risk factor linked with mucormycosis and India is the diabetes capital of the world [16] although hematological malignancies and organ transplant takes the lead in Europe and the USA [15]. DM is also the leading risk factor associated with mucormycosis globally, with an overall mortality of 46% [17]. The fatality rate in mucormycosis cases is very high. In untreated cases, mortality is high upto 80% and 40-50% in treated cases. Intracranial involvement of mucormycosis increases the fatality rate upto 90% [18]. Delay in diagnosis of disseminated mucormycosis even of 12 hours could be fatal and 50% mucormycosis cases are diagnosed only after post-mortem autopsy [19].

Mucormycosis was seen predominantly in 79% of males, in 80% cases of diabetes mellitus, 15% cases of diabetic ketoacidosis and 3% cases of cancers. For both severe COVID-19 and Mucormycosis, Diabetes mellitus (DM) is one of an independent risk factor. Mucormycosis involving nose and sinuses (90%) was most common followed by rhino-orbital (57 %) and ROCM type (22%) [2].

On May 19, the state of Rajasthan declared a Mucormycosis epidemic. There 8 out of 40 Covid 19 survivors who developed Mucormycosis in the eye lost their eyesight. As of 25th May 2021, the Indian Government reported that more than 11,700 people were receiving care for mucormycosis. Due to its rapidly growing number of cases many Indian state Governments have declared it an epidemic and notifiable disease to the national health authorities [12]. In Himachal Pradesh till 28th May 2021, there were total 8 cases of mucormycosis and 2 of them died. All patients had history of recent covid 19 infection. Himachal government declared mucormycosis as an epidemic and notifiable disease for one year on 21st

May 2021.

Pathogenesis

Characteristic of Mucormycosis infections is extensive angioinvasion that results in vessel thrombosis and subsequent tissue necrosis [20, 21].

This angioinvasion likely contributes to the ability of pathogen to disseminate hematogenously to other target organs. Resulting, damage of and penetration through endothelial cells or proteins lining blood vessels is likely to be a critical step in the pathogenesis of mucormycosis. Therefore, understanding the pathogenesis and mechanisms by which these processes occur may lead to new interventions and approaches to prevent and/or treat mucormycosis [22].

Types of Mucormycosis

- **Cutaneous (skin) mucormycosis-** occurs when there is a break in the skin e.g, after surgery, a burn, or other type of skin trauma.
- **Rhinocerebral (sinus and brain) mucormycosis -** infection in the sinuses that can spread to the brain. This form is most common in people with uncontrolled diabetes and who have had a kidney transplant [23, 24].
- **Pulmonary (lung) mucormycosis -** most common in people with cancer and who have had an organ transplant or a stem cell transplant.
- **Gastrointestinal mucormycosis -** more common among young children, especially premature and low birth weight infants less than 1 month of age.
- **Disseminated mucormycosis-** when the infection spreads through the blood to other part of the body. The infection most commonly affects the brain, but also can affect other organs such as the spleen, heart, and skin [25, 26].

In present covid 19 pandemic, increased cases of rhino-orbital mucormycosis are being recently reported [2].

Clinical features of Mucormycosis [4, 5, 28, 29]

Rhinocerebral (sinus and brain)

mucormycosis include:

- One-sided facial swelling
- Headache
- Nasal or sinus congestion
- Black lesions on nasal bridge or upper inside of mouth that quickly become more severe
- Fever

Pulmonary (lung) mucormycosis include:

- Fever
- Cough
- Chest pain
- Shortness of breath

Cutaneous (skin) mucormycosis

- Blisters or ulcers
- Infected area may turn black.
- Pain, warmth, excessive redness, or swelling around a wound.

Gastrointestinal mucormycosis include:

- Abdominal pain
- Nausea and vomiting
- Gastrointestinal bleeding

Disseminated mucormycosis

- Infection in the brain can develop mental status changes or coma.

Epidemiology**Agent Factors**

Mucormycosis is one of the emerging life-threatening fungal infection. It is also called black fungus [3]. The most common organism is *Rhizopus oryzae*, order Mucorales and is responsible for 70% of all cases of mucormycosis [4-6]. Mucorales have ability to acquire iron from the host that enable the organism to cause disease. Iron is an essential element for many vital processes like growth and development of the cell [29]. Therefore, pathogen uses multiple processes for obtaining iron from the host. The level of available, unbound iron in serum plays a critical factor in predisposing diabetic ketoacidosis patients to mucormycosis [30, 31]

In recent studies, it was found that glucose-regulated protein (GRP78) act as a receptor that mediates penetration through and damage of endothelial cells by Mucorales. It is of interest that increased concentrations of glucose and iron, enhanced surface GRP78 expression, resulting penetration by Mucorales and damage of endothelial cells in a receptor dependent manner. [32].

Other virulence factors of *Rhizopus* are the ability to secrete lytic enzymes, including aspartic proteinases and an active ketone reductase system, which enhance growth in the acidic and glucose-rich environment [33, 34].

Host predisposing factors

- COVID-19 infection
- Malignant hematological disease with or without stem cell transplantation,
- Poorly controlled diabetes mellitus with or without diabetic ketoacidosis
- Metabolic acidosis
- Prolonged and severe neutropenia
- Iron overload
- Prolonged use of corticosteroids
- Major trauma
- Intravenous drug use
- Neonatal prematurity and malnourishment

- Variety of healthcare-associated procedures and devices, such as contaminated wound dressings, Intravenous catheters, tongue depressors, transdermal nitrate patches [4-6, 28, 35, 36].

The combination of Covid 19, uncontrolled diabetes and corticosteroid therapy creates the perfect storm in which mucormycosis takes roots and thrives [37].

Why there is re-emergence of mucormycosis infection during covid-19 pandemic

- Covid 19 raises serum iron and damages airways.
- High and indiscriminate steroid use to treat covid 19 thereby reducing immunity.
- Diabetes worsened by steroids.
- Possible oxygen contamination through humidifier.
- long-term stays in the intensive care unit
- Excessive antibiotic use in covid 19.

Host Defence

Those who have impaired phagocytic function or lack phagocytes and severely neutropenic patients are at higher risk of mucormycosis indicating thereby that neutrophils are important for inhibiting fungal spore proliferation [38].

In presence of hyperglycemia and low PH as in patient of diabetic ketoacidosis (DKA) phagocytes are dysfunctional and have impaired chemotaxis and defective intracellular killing [22]. So they are more vulnerable for mucormycosis. Every day we breathe in the spores of many fungi but our immune systems and lungs, if healthy, generally prevent them from causing an infection [7]. So the ability of sporangiospores to germinate and form hyphae in the host is critical for establishing infection [39].

How does one catch black fungus?

As fungal spores are floating in the environment, most people come in contact with these spores every day, so it's probably impossible to completely avoid coming in contact with these spores. For people with weakened immune systems, breathing in fungal spores can cause an infection in the lungs or sinuses which can spread to other parts of the body. One may also catch fungus through a cut in the skin, burn, or other types of skin trauma [20]. These fungi aren't harmful to most people but if our immune systems and lungs are healthy, generally prevent them from causing an infection [7].

Diagnosis

The diagnosis of mucormycosis is challenging and treatment should start as early as possible in order to decrease mortality [40].

Clinical diagnosis

The prerequisites for the diagnosis of mucormycosis are a high index of suspicion, prompt assessment of clinical manifestations and recognition of host factors [41].

The 1950, Smith and Krichner [42] criteria for the clinical diagnosis of mucormycosis are still considered to be gold standard and include:

- Black, necrotic turbinate's easily mistaken for dried, crusted blood
- Blood-tinged nasal discharge and facial pain, both on the same side
- Soft peri-orbital or peri-nasal swelling with discoloration and induration
- Ptosis of the eyelid, proptosis of the eyeball and complete ophthalmoplegia
- Multiple cranial nerve palsies unrelated to documented lesions.

The list of above signs and symptoms that should be considered to be "red flags" [43]. Another finding on computerized tomography (CT) scan, which seems to indicate the presence of mucormycosis, is the reverse halo sign (RHS) [44].

Lab Diagnosis

Currently no specific diagnostic guidelines for mucormycosis. The culture of the clinical sample and histological examination remain the most useful approaches for diagnosis. Furthermore, alternative methods to the fungal culture are yet to be standardized [45].

Microscopic examination and culture

For diagnosis of mucormycosis analysis of biological specimens from clinically involved sites is mandatory. Every effort should be made to obtain tissue biopsies for histopathology and culture.

Microscopy (direct and histopathology) and culture of various clinical specimens are the cornerstones [41].

Serology

Enzyme-linked immunosorbent assays [46], immunodiffusion tests [47] and immunoblots [48] have been evaluated with variable success.

Molecular assays

Molecular based assays include DNA sequencing of defined gene regions [49, 50] conventional polymerase chain reaction (PCR) [51, 52], restriction fragment length polymorphism analyses (RFLP) and melt curve analysis of PCR products [53]. All assays described above can be used either for identification or detection of Mucorales.

Management

Surgical management

Mucormycoses: an indication of emergency surgery

Treatments for mucormycosis need to be fast and aggressive. The need for speed is because by the time even the presumptive diagnosis is made, often the patient has suffered significant tissue damage that cannot be reversed so early surgical debridement of the infected craniofacial tissues is the cornerstone of successful treatment of Rhino orbital cerebral mucormycosis. An aggressive and fast surgical approach appears to enhance survival [54]. Surgical debridement has to be extensive, involving all necrotic areas of infection and repeated surgical procedures are recommended to achieve local control and improve outcome [55]. Removal of the palate, nasal cavity, or eye structures can be very disfiguring [56].

Medical Management

Medications play an important role. Two main goals are sought at the same time: antifungal medications to slow or halt fungal spread and medications to treat any debilitating underlying diseases [54]. Current guidelines recommend antifungal treatment, surgical debridement, and correction of risk factors [57]. Most patients will require both surgical and medical treatments [58].

Antifungal Treatment

Amphotericin B (initially intravenous) once daily, is the usual drug of choice for antifungal treatment. In addition, posaconazole or isavuconazole may treat mucormycosis. According to study, European Confederation of Medical Mycology/European Society for Clinical Microbiology and Infectious Diseases and European Conference on Infections in Leukemia (ECIL-6) guidelines recommend the use of L-Amb with a daily dosage of at least 5 mg/kg/day for mucormycosis [58] and dosages at 10 mg/kg/day are strongly supported by ECMM/ESCMID for cerebral infections [59].

Prevention of Mucormycosis

- Use masks if you are visiting dusty construction sites and crowded place.
- Daily change the mask either it should be new or has dried up in sunlight for about 2-3 days because mask provides optimum temperature, humidity and darkness for fungal growth.
- Wear shoes, long trousers, long sleeve shirts and gloves while handling soil (gardening), moss or manure
- Maintain personal hygiene, including thorough scrub bath

DOs

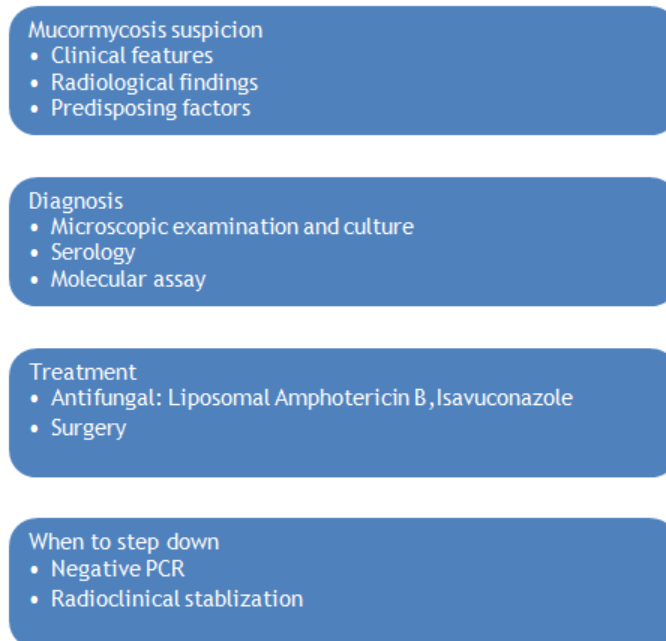
- Control hyperglycemia
- Monitor blood glucose level post-COVID-19 discharge and also in diabetics
- Use steroid judiciously – correct timing,

- correct dose and duration
- Use clean, sterile water for humidifiers during oxygen therapy
- Use antibiotics/antifungals judiciously

Don'ts

- Do not miss warning signs and symptoms
- Do not consider all the cases with blocked nose as cases of bacterial sinusitis, particularly

- in the context of immunosuppression and/or COVID-19 patients on immunomodulators
- Do not hesitate to seek aggressive investigations, as appropriate (KOH staining & microscopy, culture, MALDITOF), for detecting fungal etiology
- Do not lose crucial time to initiate treatment for mucormycosis [59].

**Figure-1: Mucormycosis: from suspicion to treatment****CONCLUSION**

Mucormycosis is an opportunistic infection in covid 19 recovered patients. DM has been the most common risk factor linked with it. Liposomal Amphotericin B ($\geq 5\text{mg/kg}$) combined with surgery is the first line therapy for mucormycosis. Himachal Pradesh Government declared mucormycosis as an epidemic for one year on 21st May 2021.

Funding: No funding sources.

Conflict of interest: None declared.

Ethical approval: Not required.

REFERENCES

1. Farnoosh, G., Alishiri, G., Zijoud, S. H., Dorostkar, R., & Farahani, A. J. (2020). Understanding the severe acute respiratory syndrome coronavirus 2 (SARS-CoV-2) and coronavirus disease (COVID-19) based on available evidence-a narrative review. *Journal of military medicine*, 22(1), 1-11.
2. Singh, A. K., Singh, R., Joshi, S. R., & Misra, A. (2021). Mucormycosis in COVID-19: a systematic review of cases reported worldwide and in India. *Diabetes & Metabolic Syndrome: Clinical Research & Reviews*.
3. Richardson, M. (2009). The ecology of the Zygomycetes and its impact on environmental exposure. *Clinical Microbiology and Infection*, 15, 2-9.
4. Ribes, J. A., Vanover-Sams, C. L., & Baker, D. J. (2000). Zygomycetes in human disease. *Clinical microbiology reviews*, 13(2), 236-301.
5. Spellberg, B., Edwards Jr, J., & Ibrahim, A. (2005). Novel perspectives on mucormycosis: pathophysiology, presentation, and management. *Clinical microbiology reviews*, 18(3), 556-569.
6. Roden, M. M., Zaoutis, T. E., Buchanan, W. L., Knudsen, T. A., Sarkisova, T. A., Schaufele, R. L., ... & Walsh, T. J. (2005). Epidemiology and outcome of zygomycosis: a review of 929 reported cases. *Clinical infectious diseases*, 41(5), 634-653.
7. Monica, S., & Karin, T. (2021). Mucormycosis: the black fungus hitting Covid-19 patients. <https://www.bbc.com › future › article › 2021>.
8. Chander, J. (2018). "26. Mucormycosis". *Textbook of Medical Mycology* (4th ed.). New Delhi: Jaypee Brothers Medical Publishers Ltd. pp. 534-596.
9. Yamin, H. S., Alastal, A. Y., & Bakri, I. (2017). Pulmonary mucormycosis over 130 years: a case

- report and literature review. *Turkish thoracic journal*, 18(1), 15.
10. Dannaoui, E., & Lackner, M. (2020). Mucorales and Mucormycosis. *Journal of Fungi*, 6(1), 6.
 11. Benedict, K., Adebajo, T., Harris, J., Lockhart, S., Peterson, J., McClinton, S., ... & Lo, Y. C. (2011). Notes from the field: Fatal fungal soft-tissue infections after a Tornado---Joplin, Missouri, 2011. *Morbidity and Mortality Weekly Report*, 60(29).
 12. Dev Ankur, W., Pankaj, J., Samarth, S., & Kumar, K.. (2021). *Rajasthan declares black fungus an epidemic; cases pile up in several states, 10 points*. India Today. Retrieved May 20, 2021.
 13. Skiada, A., Pavleas, I., & Drogari-Apiranthitou, M. (2020). Epidemiology and diagnosis of mucormycosis: an update. *Journal of Fungi*, 6(4), 265.
 14. Chander, J., Kaur, M., Singla, N., Punia, R. P. S., Singhal, S. K., Attri, A. K., ... & Guarro, J. (2018). Mucormycosis: battle with the deadly enemy over a five-year period in India. *Journal of Fungi*, 4(2), 46.
 15. Prakash, H., & Chakrabarti, A. (2019). Global epidemiology of mucormycosis. *Journal of Fungi*, 5(1), 26.
 16. International Diabetes Federation. *Idf Diabetes Atlas*. 2019. Available online: <https://diabetesatlas.org/en/resources/> (accessed on May 10, 2021).
 17. Jeong, W., Keighley, C., Wolfe, R., Lee, W. L., Slavin, M. A., Kong, D. C. M., & Chen, S. A. (2019). The epidemiology and clinical manifestations of mucormycosis: a systematic review and meta-analysis of case reports. *Clinical Microbiology and Infection*, 25(1), 26-34.
 18. Deutsch, P. G., Whittaker, J., & Prasad, S. (2019). Invasive and non-invasive fungal rhinosinusitis—a review and update of the evidence. *Medicina*, 55(7), 319.
 19. Maartens, G., & Wood, M. J. (1991). The clinical presentation and diagnosis of invasive fungal infections. *Journal of Antimicrobial Chemotherapy*, 28(suppl_A), 13-22.
 20. Ibrahim, A. S., Edwards, J. E., & Filler, S. G. (2003). Zygomycosis. In: Dismukes, W. E., Pappas, P. G., & Sobel, J. D., eds. *Clinical mycology*. New York, NY: Oxford University Press, 241-251.
 21. Ben-Ami, R., Luna, M., Lewis, R. E., Walsh, T. J., & Kontoyiannis, D. P. (2009). A clinicopathological study of pulmonary mucormycosis in cancer patients: extensive angioinvasion but limited inflammatory response. *Journal of Infection*, 59(2), 134-138.
 22. Ibrahim, A. S., Spellberg, B., Walsh, T. J., & Kontoyiannis, D. P. (2012). Pathogenesis of mucormycosis. *Clinical Infectious Diseases*, 54(suppl_1), S16-S22.
 23. Song, Y., Qiao, J., Giovanni, G., Liu, G., Yang, H., Wu, J., & Chen, J. (2017). Mucormycosis in renal transplant recipients: review of 174 reported cases. *BMC infectious diseases*, 17(1), 1-6.
 24. Ahmed, A., Adelman, D., Fahal, A., Verbrugh, H., van Belkum, A., & de Hoog, S. (2002). Environmental occurrence of *Madurella mycetomatis*, the major agent of human eumycetoma in Sudan. *Journal of clinical microbiology*, 40(3), 1031-1036.
 25. Vallabhaneni, S., & Mody, R. K. (2015). Gastrointestinal mucormycosis in neonates: a reviewexternal icon. *Current Fungal Infect Rep*.
 26. Francis, J. R., Villanueva, P., Bryant, P., & Blyth, C. C. (2018). Mucormycosis in children: review and recommendations for managementexternal icon. *J Pediatric Infect Dis Soc*, 7(2), 159-164.
 27. Petrikos, G., Skiada, A., Lortholary, O., Roilides, E., Walsh, T. J., & Kontoyiannis, D. P. (2012). Epidemiology and clinical manifestations of mucormycosis. *Clinical Infectious Diseases*, 54(suppl_1), S23-S34.
 28. Lewis, R. E., & Kontoyiannis, D. P. (2013). Epidemiology and treatment of mucormycosisexternal icon. *Future Microbiol*, 8(9), 1163-1175.
 29. Howard, D. H. (1999). Acquisition, transport, and storage of iron by pathogenic fungi. *Clin Microbiol Rev*, 12, 394-404.
 30. Artis, W. M., Fountain, J. A., Delcher, H. K., & Jones, H. E. (1982). A mechanism of susceptibility to mucormycosis in diabetic ketoacidosis transferrin and iron availability. *Diabetes*, 31(12), 1109-1114.
 31. Boelaert, J. R., de Locht, M., Van Cutsem, J., Kerrels, V., Cantinieaux, B., Verdonck, A., ... & Schneider, Y. J. (1993). Mucormycosis during deferoxamine therapy is a siderophore-mediated infection. In vitro and in vivo animal studies. *The Journal of clinical investigation*, 91(5), 1979-1986.
 32. Liu, M., Spellberg, B., Phan, Q. T., Fu, Y., Fu, Y., Lee, A. S., ... & Ibrahim, A. S. (2010). The endothelial cell receptor GRP78 is required for mucormycosis pathogenesis in diabetic mice. *The Journal of clinical investigation*, 120(6), 1914-1924.
 33. Farley, P. C., & Sullivan, P. A. (1998). The *Rhizopus oryzae* secreted aspartic proteinase gene family: an analysis of gene expression. *Microbiology*, 144(8), 2355-2366.
 34. Anand, V. K., Alemar, G., & Griswold Jr, J. A. (1992). Intracranial complications of mucormycosis: an experimental model and clinical review. *The Laryngoscope*, 102(6), 656-662.
 35. Antoniadou, A. (2009). Outbreaks of mucormycosis in hospitals. *Clin Microbiol Infect*, 15(Suppl 5), 55-59.
 36. Cheng, V. C., Chan, J. F., Ngan, A. H., To, K. K., Leung, S. Y., Tsoi, H. W., ... & Yuen, K. Y. (2009). Outbreak of intestinal infection due to *Rhizopus microsporus*. *Journal of clinical microbiology*, 47(9), 2834-2843.
 37. [https://www.healio.com/news/ophthalmology/May 25, 2021](https://www.healio.com/news/ophthalmology/May-25-2021).
 38. Sugarm, A. M. (2005). Agents of mucormycosis and related species. In: Mandell, G. L., Bennett, J. E., Dolin, R., eds. *Principles and practice of infectious diseases*. 6th ed. Philadelphia, PA: Elsevier, 2979, S20.
 39. Chinn, R. Y., & Diamond, R. D. (1982). Generation of chemotactic factors by *Rhizopus oryzae* in the presence and absence of serum: relationship to hyphal damage mediated by human neutrophils and effects of

- hyperglycemia and ketoacidosis. *Infection and Immunity*, 38(3), 1123-1129.
40. Chamilos, G., Lewis, R. E., & Kontoyiannis, D. P. (2008). Delaying amphotericin B-based frontline therapy significantly increases mortality among patients with hematologic malignancy who have zygomycosis. *Clinical Infectious Diseases*, 47(4), 503-509.
 41. Skiada, A., Lass-Floerl, C., Klimko, N., Ibrahim, A., Roilides, E., & Petrikos, G. (2018). Challenges in the diagnosis and treatment of mucormycosis. *Medical mycology*, 56(suppl_1), S93-S101.
 42. Smith, H. W., & Kirchner, J. A. (1950). Cerebral mucor-mycosis: A report of 3 cases. *Arch Otolaryng (Chicago)*, 68:715-726.
 43. Corzo-León, D. E., Chora-Hernández, L. D., Rodríguez-Zulueta, A. P., & Walsh, T. J. (2018). Diabetes mellitus as the major risk factor for mucormycosis in Mexico: Epidemiology, diagnosis, and outcomes of reported cases. *Medical mycology*, 56(1), 29-43.
 44. Legouge, C., Caillot, D., Chrétien, M. L., Lafon, I., Ferrant, E., Audia, S., ... & Dalle, F. (2014). The reversed halo sign: pathognomonic pattern of pulmonary mucormycosis in leukemic patients with neutropenia?. *Clinical infectious diseases*, 58(5), 672-678.
 45. Garcia-Hermoso, D. (2013). Laboratory diagnosis of mucormycosis. *Medecine Sciences: M/S*, 29, 13-18.
 46. Sandven, P. E. R., & Eduard, W. (1992). Detection and quantitation of antibodies against *Rhizopus arrhizus* antigens. *Journal of clinical microbiology*, 25(2), 358-363.
 47. Jones, K. W., & Kaufman, L. (1978). Development and evaluation of an immunodiffusion test for diagnosis of systemic zygomycosis (mucormycosis): preliminary report. *Journal of Clinical Microbiology*, 7(1), 97-101.
 48. Wysong, D. R., & Waldorf, A. R. (1987). Electrophoretic and immunoblot analyses of *Rhizopus arrhizus* antigens. *Journal of clinical microbiology*, 25(2), 358-363.
 49. Nyilasi, I., Papp, T., Csernetics, Á., Krizsán, K., Nagy, E., & Vágvölgyi, C. (2008). High- affinity iron permease (FTR1) gene sequence- based molecular identification of clinically important Zygomycetes. *Clinical Microbiology and Infection*, 14(4), 393-397.
 50. Springer, J., Lackner, M., Ensinger, C., Risslegger, B., Morton, C. O., Nachbaur, D., ... & Loeffler, J. (2016). Clinical evaluation of a Mucorales-specific real-time PCR assay in tissue and serum samples. *Journal of medical microbiology*, 65(12), 1414-1421.
 51. Hsiao, C. R., Huang, L., Bouchara, J. P., Barton, R., Li, H. C., & Chang, T. C. (2005). Identification of medically important molds by an oligonucleotide array. *Journal of clinical microbiology*, 43(8), 3760-3768.
 52. Nagao, K., Ota, T., Tanikawa, A., Takae, Y., Mori, T., Udagawa, S. I., & Nishikawa, T. (2005). Genetic identification and detection of human pathogenic *Rhizopus* species, a major mucormycosis agent, by multiplex PCR based on internal transcribed spacer region of rRNA gene. *Journal of dermatological science*, 39(1), 23-31.
 53. Kasai, M., Harrington, S. M., Francesconi, A., Petratis, V., Petratiene, R., Beveridge, M. G., ... & Walsh, T. J. (2008). Detection of a molecular biomarker for zygomycetes by quantitative PCR assays of plasma, bronchoalveolar lavage, and lung tissue in a rabbit model of experimental pulmonary zygomycosis. *Journal of clinical microbiology*, 46(11), 3690-3702.
 54. Charles, P. D., & Mary, D. N. (2021). Mucormycosis (Zygomycosis) *Medicine Medically Reviewed on 5/10/2021*.
 55. Vironneau, P., Kania, R., Herman, P., Morizot, G., Garcia-Hermoso, D., Lortholary, O., ... & French Mycosis Study Group. (2014). Local control of rhino-orbito-cerebral mucormycosis dramatically impacts survival. *Clinical Microbiology and Infection*, 20(5), O336-O339.
 56. "MedlinePlus Medical Encyclopedia: Mucormycosis". Retrieved May 19, 2008.
 57. Tissot, F., Agrawal, S., Pagano, L., Petrikos, G., Groll, A. H., Skiada, A., ... & Herbrecht, R. (2017). ECIL-6 guidelines for the treatment of invasive candidiasis, aspergillosis and mucormycosis in leukemia and hematopoietic stem cell transplant patients. *haematologica*, 102(3), 433-444.
 58. Cornely, O., Arian- Akdagli, S. E. V. T. A. P., Dannaoui, E., Groll, A. H., Lagrou, K., Chakrabarti, A., ... & Petrikos, G. (2014). ESCMID and ECMM joint clinical guidelines for the diagnosis and management of mucormycosis 2013. *Clinical Microbiology and Infection*, 20, 5-26.
 59. Cornely, O., Arian- Akdagli, S. E. V. T. A. P., Dannaoui, E., Groll, A. H., Lagrou, K., Chakrabarti, A., ... & Petrikos, G. (2014). ESCMID and ECMM joint clinical guidelines for the diagnosis and management of mucormycosis 2013. *Clinical Microbiology and Infection*, 20, 5-26.