

## Study of Incidence of Wormian Bones in Eastern Haryana - A Prospective Observational Study

Dr. Manoj Somani<sup>1\*</sup>, Dr. Sangram Singh Yadav<sup>1</sup>, Dr. Sunil Kumar<sup>1</sup>, Dr. Virkant Kumar<sup>1</sup><sup>1</sup>PG Resident, BPS GMCW, Khanpur Kalan, Sonipat, Haryana IndiaDOI: [10.36347/sjams.2021.v09i08.003](https://doi.org/10.36347/sjams.2021.v09i08.003)

| Received: 26.06.2021 | Accepted: 29.07.2021 | Published: 05.08.2021

\*Corresponding author: Dr. Manoj Somani

## Abstract

## Original Research Article

**Introduction:** Wormian bones are the bones which found in the cranium having no regular relation to their normal ossification centres. They can be falsely observed as a fracture skull. The present study was conducted to evaluate the percentage of skulls where wormian bones were present, anatomical distribution of wormian bones, side specific distribution of wormian bones, and range of observed wormian bones. **Materials and Methods:** The present study was conducted in the Department of Forensic Medicine in Government Medical College of Eastern Haryana over a period of one year from January 2019 to January 2020. A total number of 188 cases brought for post-mortem examination were studied. 135 male and 53 female dead bodies were studied. Location of wormian bones along the coronal, sagittal and lambdoid suture on ectocranial surface was noted. **Results:** The overall incidence of wormian bones was 29.78%. 41 wormian bones (21.8%) were observed in males and 15 (7.97%) in females. Wormian bones were most commonly located in lambdoid suture that is in 40 (21.28%) cases. Out of 40 wormian bones observed around lambdoid suture, 25 (62.5%) were found on left half of the skull and 6 (15%) were on right half of the skull. **Conclusion:** The knowledge of wormian bones may help the doctors in their daily practice in timely diagnosis and management of diseases or fractures in relation to the wormian bones. Knowledge of wormian bones is clinically important for forensic experts, neurosurgeons and radiologists because many a time's wormian bones may be misinterpreted for fractures in head injuries.

**Keywords:** Wormian Bones Eastern Haryana Incidence.

Copyright © 2021 The Author(s): This is an open-access article distributed under the terms of the Creative Commons Attribution 4.0 International License (CC BY-NC 4.0) which permits unrestricted use, distribution, and reproduction in any medium for non-commercial use provided the original author and source are credited.

## INTRODUCTION

Wormian bones are also known as Schaltknochen Supernumerary ossicles, Intercalary, and Sutural & Intrasutural bones [1]. Wormian bones are those bones which are found in the cranium having no regular relation to their normal ossification centres. They occur frequently and generally occupy the sutures and fill fontanelles of neonatal skull [2]. They are named after Olaus Worm, a Danish anatomist who described them in a letter to Thomas Bartholin in 1643. Subsequently, Bartholin named them as Ossa Wormiana, their present name. They are formed due to alterations in the normal formation of the flat skull bones and are usually regarded as normal variants. Sometime they can be considered as an abnormal anatomical variant because they are frequently found in certain bone dysplasia conditions including osteogenesis imperfecta, rickets, cleidocranial dysostosis, and pycnodysostosis [3, 4]. Etiology about prevalence and mechanisms of wormian bones formation in the skull are still unknown [5]. The formation of sutural bones is assumed to be controlled

by genetic factors [6]. Knowledge of these bones is important for anthropologists, forensic experts, radiologists, orthopedicians and neurosurgeons to avoid deception for fractures of the skull [7, 8]. In the present study our objective was to evaluate the percentage of skulls where wormian bones were present, anatomical distribution of wormian bones, side specific distribution of wormian bones and the range of observed wormian bone.

## MATERIAL AND METHODS

The present study was conducted in the Department of Forensic Medicine in Government Medical College of Eastern Haryana over a period of one year from January 2019 to January 2020. A total number of 188 cases brought for post-mortem examination were studied. 135 male and 53 female dead bodies were studied. Skulls of both sexes with deformed or diseased or fractured skull were excluded from the study population. Scalp was reflected anteriorly to a level 1-2 cm above the supra orbital ridge and posteriorly to a level just above the external

occipital protuberance [9]. Temporal muscles were dissected and the periosteum was denuded. Location of wormian bones along the coronal, sagittal and lambdoid suture on ectocranial surface was noted. In our study, only the bones surrounded by apparent sutures were recorded as wormian bones and only the obvious ones were considered.

### Observations and Results

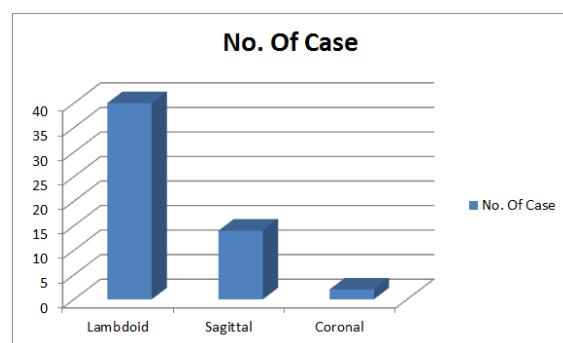
In present study the incidence of wormian bones was 29.78% (56/188). Out of these 41 (21.80%) male skulls and 15 (7.97%) female skulls showed wormian bones (Table 1).

Wormian bones were most commonly located in lambdoid suture (40/188, 21.28%), followed in order of frequency by sagittal suture (14/188, 10.77%). Only two case showed wormian bone in coronal suture (1.06%, 2/188) (Graph 1).

Out of 40 wormian bones, 25 (62.5%) were found on left half of the skull and 6 (15%) were on right half of the skull in the lambdoid suture. Nine cases

(22.5%) showed wormian bones on both right and left side of lambdoid suture. Only 2 (1.06%) cases showed wormian bone in coronal suture, one on right side and one on both sides of coronal suture (Table 2).

There is occurrence of a single wormian bone in 18 (9.57%) skulls only while multiple wormian bones were observed in 38 (20.21%) cases (Table 3).



**Graph-1: Graphical representation of incidence of Wormian bones in different sutures**

**Table-1: Overall Incidence of Wormian bones in total subjects**

Wormian bones	Male	Female	Total
Present	41 (30.37%)	15 (28.30%)	56 (29.78%)
Absent	94 (69.62%)	38 (71.70%)	132 (70.21%)
Total	135 (100%)	53 (100%)	188 (100%)

**Table-2: Incidence of Wormian bones at different Locations**

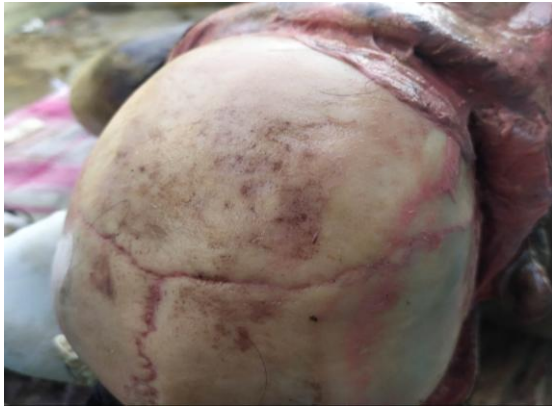Location of wormian bone	Right side	Left side	Both right and left side
Coronal Suture	1	0	1
Lambdoid Suture	6	25	9

**Table-3: Range of observed wormian bones**

No. of wormian bones	No. of cases
Single	18 (9.57%)
Multiple	38 (20.21%)

**Table-4: Comparison of incidence of Wormian bones in various studies**


Sr. No	Study	Year	Region	No. of Cases	Percentage
1	Saxena et al. [13]	1985	Nigeria	40	2.5
2	Masih et al. [8]	2013	Rajasthan	150	4.7
3	Marti et al. [4]	2013	France	605	53
4	Ghosh et al. [10]	2016	West Bengal	120	45
5	Reddy et al. [14]	2018	Telangana	100	48
6	Natsis et al. [12]	2018	Greece	166	74.7
7	Goyal et al. [11]	2018	Haryana	147	35.37
8	Present study	2020	Eastern Haryana	188	29.78



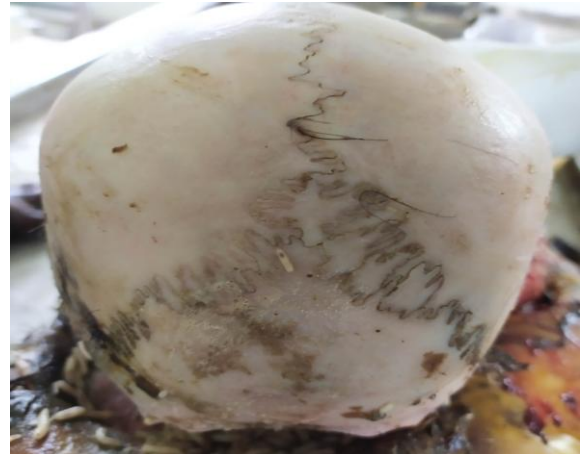**Fig-1: Wormian bone in right coronal suture**



**Fig-2: Wormian bones in bilateral lambdoid sutures**



**Fig-3: Wormian bone in sagittal suture**



**Fig-4: Wormian bones in sagittal and lambdoid suture**

## DISCUSSION

Wormian bones are very common finding seen in human skulls. We are known of wormian bones for a very long time [8, 10, 11]. In our study, incidence of the wormian bones was found to be 29.78%. The incidence of wormian bones varies in the literature. A study in Greek presented over 124 skulls (74.7%) having wormian bones out of total 166 skulls [12]. In a study done by Saxena *et al.* in Nigeria incidence of wormian bones was 2.5% which was very less as compared to our study [13]. Marty *et al.* studied the incidence of wormian bones in France on 605 CT brains scans from normal child population excluding constitutional bone diseases, found an incidence of 53% which was higher as compared to our study [4]. In another study from West Bengal on 120 unknown adult skulls found the incidence of wormian bones being 45% [10]. In a study done by Goyal *et al.* in Haryana over 147 subjects, overall incidence of wormian bones was seen in 52 skulls (35.3%) [11]. The variation may be due sample size and place of study. The incidence of according to various studies is depicted in Table 4.

In our study the most common site of wormian bone was at lambdoid suture (21.28%), this observation was supported by Natsis *et al.*, who in their study over 166 human skulls also observed the higher incidence of wormian bone in the lambdoid suture (44.6%) [12]. Anitha *et al.* also observed higher incidence of wormian bone in the lambdoid suture, in their study conducted over 50 skulls [15]. Similarly, Marti *et al.* and Goyal *et al.* in their respective studies also showed maximum incidence of wormian bones along with lambdoid suture [4, 11]. In the present study, the second most common site of wormian bone was at sagittal suture (10.77%). Only 2 (1.06%) cases showed wormian bone in coronal suture. Tewari *et al.* did not find any wormian bones in the coronal or sagittal sutures [16].

We observed that wormian bones were present on left side of skull in 25(62.5%) of cases and 6(15%) on right side of skull which was consistent with the study done by Patel et al. who observed wormian bones on the left half of skull in 48.1% of cases and 37.03% on right half of skull. [7] Present study depicts wormian bones in nine cases (22.5%) on both right and left side of lambdoid suture. Only 2(1.06%) cases showed wormian bone in coronal suture in our study. The study done by Natsis et al. also showed incidence of wormian bones in one case (0.6%) only [12].

The presence of wormian bone was observed more in males 41 (21.8%) than in females 15 (7.97%) in present study. Observations made by Masih et al. in the study conducted at Rajasthan were in concordance with our study results. Incidence of wormian bone was higher in males as compared to females in their study [8]. However, study conducted by Natsis et al. showed no gender wise difference in the incidence of Wormian bones [12].

The present study showed the occurrence of a single wormian bone in 18 (9.57%) skull only. Multiple wormian bones were observed in 38 (20.21%) cases. Study done by Saxena et al. showed occurrence of single wormian bone in one skull only. Multiple wormian bones were observed in four skulls in their study [13]. Ghosh et al. also observed in their study that 18 (15%) skulls had a single wormian bone and 36 (30%) skulls had multiple wormian bones [10].

## CONCLUSION

Knowledge of wormian bones is clinically important for forensic experts, neurosurgeons and radiologists because many a time's wormian bones may be misinterpreted for fractures in head injuries. Our study shows that wormian bones may be found even in coronal and sagittal suture in addition to the usual site in lambdoid suture. The knowledge of wormian bones may help the doctors in their daily practice in timely diagnosis and management of diseases or fractures in relation to the wormian bones. Sometime wormian bones may fall in decomposed bodies which give rise to appear as entry or exit gunshot wound.

## REFERENCES

- Nayak, S. B. (2008). Multiple Wormian bones at the lambdoid suture in an Indian skull. *Neuroanatomy*, 7, 52-53.
- Srivastava, H. C. (1992). Ossification of the membranous portion of the squamous part of the occipital bone in man. *Journal of anatomy*, 180(Pt 2), 219.
- Gonzalez-Reinoso, M., Pimentel, H., Fermin-Delgado, R., & Stoeter, P. (2014). Unusually large anterior fontanellar bone and diffuse capillary malformation with overgrowth in a three-month-old child: a computed tomography case report. *The neuroradiology journal*, 27(5), 613-615.
- Marti, B., Sirinelli, D., Maurin, L., & Carpentier, E. (2013). Wormian bones in a general paediatric population. *Diagnostic and interventional imaging*, 94(4), 428-432.
- Reveron, R. R. (2017). Anatomical classification of sutural bones. *MOJ Ana Physiol.*–2017, 3(4), 130-131.
- El-Najjar, M., & Dawson, G. L. (1977). Photographic regional atlas of bone disease. *Am J Phys Anthropol*, 46, 155-60.
- Patel, D., Chauhan, K., & Patil, D. (2015). Morphological study of wormian bones in dried human skulls. *Natl. J. Med. Res*, 5(3), 222-225.
- Masih, W. F., Gupta, S., Chand, A. E., Jaiswal, P., & Saraswat, P. K. (2013). Incidence of wormian bone in human skulls in Rajasthan. *Journal of Evolution of Medical and Dental Sciences*, 2(9), 1001-1005.
- Ludwig, J. (2002). *Handbook of autopsy practice*. 3rd ed. New Jersey: Humana Press.
- Ghosh, S., Biswas, S., Sharma, S., & Chakraborty, S. (2017). An anatomical study of wormian bones from the eastern part of India: is genetic influence a primary determinant of their morphogenesis?. *Anatomical science international*, 92(3).
- Goyal, N., Garg, A., & Kumar, Y. (2019). Incidence and medicolegal significance of wormian bones in human skulls in North India Region. *International Journal of Applied and Basic Medical Research*, 9(3), 165.
- Natsis, K., Piagkou, M., Lazaridis, N., Anastasopoulos, N., Nousios, G., Piagkos, G., & Loukas, M. (2019). Incidence, number and topography of Wormian bones in Greek adult dry skulls. *Folia morphologica*, 78(2), 359-370.
- Saxena, S. K., Chowdhary, D. S., & Jain, S. P. (1986). Interparietal bones in Nigerian skulls. *Journal of anatomy*, 144, 235.
- Shankar, S., Chawla, H., Kumar, R., Tyagi, A., Vashishtha, B., & Panchal, J. (2020). Study of incidence of wormian bones in southern Haryana-A prospective observational study.
- Anitha, V., Jalharish, G., Rishi, S.M., Rishwanth, V.H. (2017). Wormian Bones -An Original Research Article. *Int J Sci Res*, 6(10):782–4.
- Tewari, P. S., Malhotra, V. K., Agarwal, S. K., & Tewari, S. P. (1982). Preinterparietal bone in man. *Anatomischer Anzeiger*, 152(4), 337-339.