

Interesting Case of Hernia of Canal of Nuck in Elderly Female

Dr. S.T. Bhondave*¹, Dr. Niranjan Dash², Dr. Mrs. V.J. Thipse³, Dr. J.M. Gadekar⁴

¹Postgraduate student, ^{2,3}Professor, ⁴Professor and Head of department

Department of General Surgery, DVVPPF's Medical College and Hospital, Ahmednagar, Maharashtra, India

Case Report

*Corresponding author

Dr. S.T. Bhondave

Article History

Received: 15.19.2017

Accepted: 24.11.2017

Published: 30.11.2017

DOI:

10.21276/sasjs.2017.3.11.4



Abstract: In females, inguinal hernia is rare as compared to males. Females have well built inguinal anatomy. We report a 60 years old female patient who presented to our hospital with swelling in the right groin. She was investigated and diagnosed clinically as right indirect inguinal hernia. She underwent repair with Lichtenstein's mesh technique and had smooth postoperative course. There was no recurrence during 1 year of follow up.

Keywords: inguinal hernia, Lichtenstein's mesh technique

INTRODUCTION

Inguinal hernia is uncommon in females. 1.9% is the incidence rate of female inguinal hernia, while 7:1 is the Male: Female ratio of inguinal hernia [1, 2]. In 1691, Anton Nuck (de) first described the canal of Nuck being an abnormal patent pouch of peritoneum extending into labia majora of female. Patent processus vaginalis being its male analogue. Failure of obliteration of canal of Nuck results in female inguinal hernia [3]. In our case we have encountered an old lady with right indirect inguinal hernia which was managed successfully by hernioplasty.

CASE REPORT

A 60-year-old female patient, presented to the surgical department in DVVPPF's Medical college and Hospital with swelling in the groin since 6 months. There was no history of trauma or altered bowel habits. Past medical history was insignificant. Tubal ligation was done 20 years back and abdominal hysterectomy, 5 years back.

On examination, the swelling was reducible. Expansile cough impulse was present and deep ring occlusion test was positive revealed indirect inguinal hernia. (Fig.1). The examination of rest of the abdomen and flank was normal. Ultrasonography revealed a defect measuring 3x3 cm in the anterior abdominal wall on the right side revealing inguinal hernia. There was herniated bowel loop showing normal vascularity and peristalsis as the content. A diagnosis of reducible right inguinal hernia was made and patient was taken up for

surgery. Open Lichtenstein's hernia repair was done after reducing the contents, ligating and excising the sac. (Fig.2, 3)The immediate postoperative was uneventful. Oral feeds were started after 6 hours. The patient recovered satisfactorily and was discharged after removal of skin sutures on 8th postoperative day. During the follow-up visit after one month, the operative scar was found to be well healed and the patient was absolutely asymptomatic. No recurrence during last 1 year of follow up.

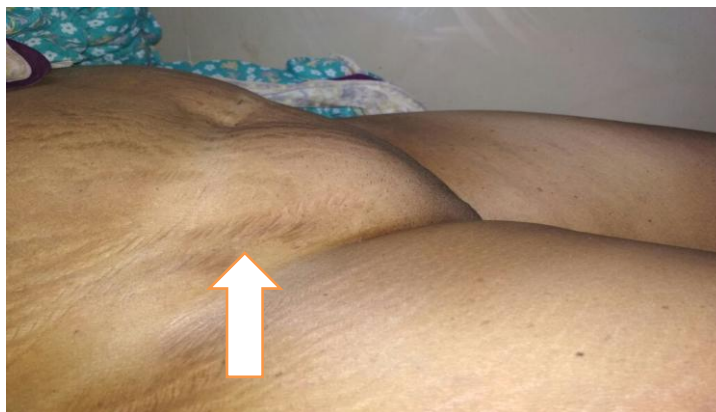

Fig-1: External appearance of right inguinal hernia

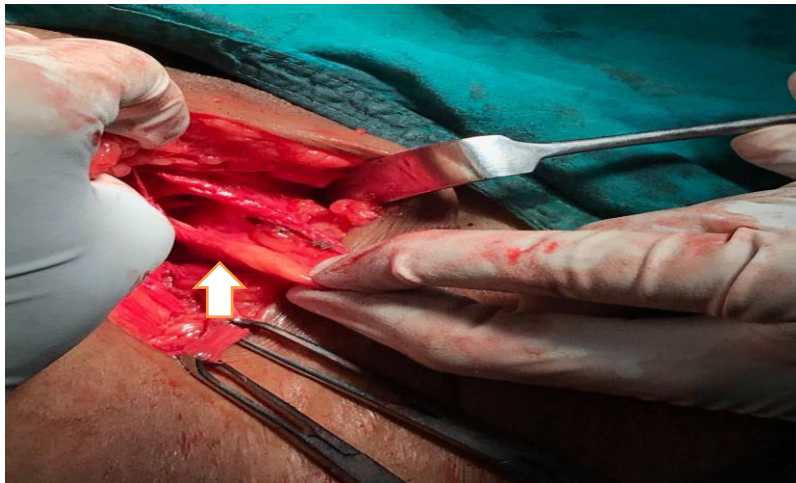


Fig-2: Intraoperative sac dissection

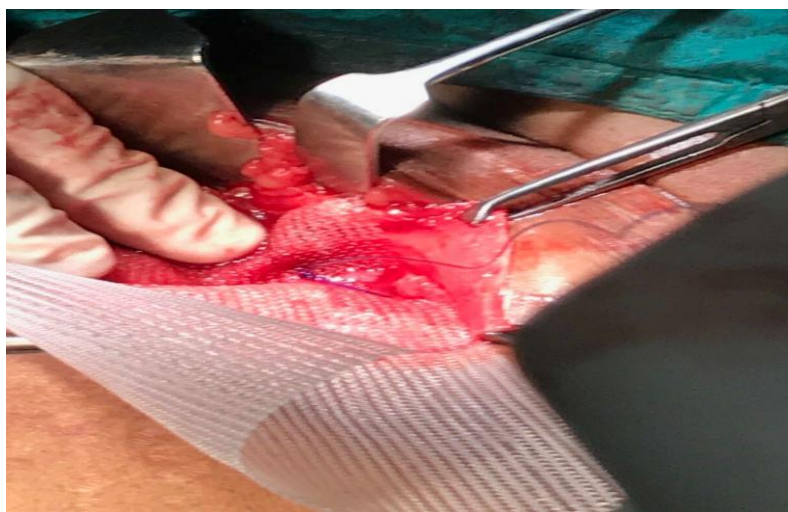

Fig-3: Intraoperative mesh fixation

DISCUSSION

Females have 3% life time risk of having inguinal hernia, which rarely occurs in them [4]. The reported incidence of its occurrence is 2.9% in elderly, 30% in adolescents or women in reproductive age group and 71% in children under 5 years [5]. In 68.1%, inguinal hernias are present on the right side, while in 23.4% it is present on the left side and bilateral in 8.5%. In elderly women, inguinal hernias occur during the age 40-60 and indirect are more common as compared to direct hernias [6].

Inguinal hernias present as painless bulge in the groin, with mild to severe abdominal-pelvic pain. They should be promptly evaluated due to possible strangulation of organs, including the ovary and fallopian tube. Entrapment of adnexa in an indirect inguinal hernia is rare in adult women. In our case, patient was 60 years old, female and the inguinal hernia occurred on the right side which was uncomplicated.

Hernia of canal of Nuck is an abnormal extension of peritoneal fold extending into labia majora through the inguinal canal, which accompanies the

round ligament of uterus. This peritoneal fold disappears by 8th intrauterine life, but its persistence may lead to formation of hydrocele of canal of nuck or inguinal hernia [7]. Controlled strenuous activities strengthen the musculo-pectineal orifice of Fruchaud in females which is a weak spot from where hernia can occur. Positive family history, constipation and previous surgeries are the risk factors for female inguinal hernia [8]. In our case, patient had previous operative surgery.

Most common differential diagnosis of the hernia of canal of Nuck is hydrocele of canal of Nuck. Bartholin's cyst, lipoma, cold abscess, post traumatic haematoma and lymphadenopathy are common differential diagnosis of hernia canal of Nuck [9].

The diagnosis of female inguinal hernia is based on history, physical examination and ultrasonography of the abdomen for the contents [10]. In our case, it was clinically indirect inguinal hernia and ultrasonography showing small bowel as the content.

Bilateral female inguinal hernia raises the surgeon's opinion about the child's nuclear sex, because

of absence of androgen responsiveness i.e. androgen insensitivity syndrome [11]. Our case was elderly female and there was no such finding.

In our case, the right inguinal hernia sac contained small bowel loops. The reduction of contents was done with excising the redundant sac and transfixing the base of sac. Further, mesh repair was done.

CONCLUSION

Unusual contents of inguinal hernia sac are rare, but may be encountered in one's surgical career during hernia repair, as it is most commonly performed surgeries. Depending on the age and sex of the patient, it is difficult to comment on appropriate management for hernia repair which should be individualized, for better outcome in these patients.

Ethical approval

Written informed consent was obtained from the patient for publication of this case report and accompanying images. A copy of written consent is available for review by the Editor-in-Chief of this journal.

REFERENCES

1. V. M. J. Sherman and F. C. Brunicaudi, "Inguinal hernias," in *Schwartz's Principles of Surgery*, McGraw-Hill, New York, NY, USA, 2015;10:1495-1519.
2. Dr.Arvind Kumar Prabhat, Dr.Niranjan Dash, Dr. J.M.Gadekar, Dr.Mrs.V.J.Thipse. A rare case of bilateral hernia of canal of Nuck. *Journal of Medical and Science and Clinical Resarch* 2017;5(9): 28166-69.
3. Gurudutt Bhaskar Basrur, Bilateral inguinal hernias containing ovaries,clinics and practice 2015;5:708.
4. Gould J. Laparoscopic versus open inguinal hernia repair.*Surg Clin N Am.* 2008;88:1073-81.
5. Dr Sumita A Jain,Sliding Inguinal Hernia in Elderly Female With Ovary as its Content;ARC *Journal of Clinical Case Reports* 2015;1:21-23.
6. Devlin HB. Inguinal hernia in babies and children. In: Dudley H, Walter P, Carter D, eds. *Rob & Smith operative surgery*. Oxford: Butterworths, 1983;4:449-54.
7. Jedrzejewski G, Stankiewicz A, Wieczorek AP. Uterus and ovary hernia of the canal of Nuck. *Pediatr Radiol* 2008;38:1257-58.
8. Huang CS, Luo CC, Chao HC, Chu SM, Yu YJ, Yen JB. The presentation of asymptomatic palpable movable mass in female inguinal hernia. *Eur J Pediatr* 2003;162:493-95.
9. Poenaru D, Jacobs DA, Kamal I. Unusual findings in the inguinal canal: A report of four cases. *Pediatr Surg Int.* 1999;15:515-16.
10. Artas H, Gurbuzer N. Inguinal hernia containing both ovaries and the uterus in an infant. *J Ultrasound Med.* 2012;31:1137.
11. Siddaiah B. XY female with complete androgen insensitivity syndrome with bilateral inguinal hernia. *J Indian Med Assoc.* 2013;111:480-81.