

## Surgical Outcome of Closed Bi-Malleolar Fracture in adult, Bangladesh Perspective

Dr. Ataul Haque<sup>1\*</sup>, Dr. Md. Munzur Rahman<sup>2</sup>, Dr. Abdul Awal<sup>3</sup>, Dr. Md. Munzur Rahman Sarkar<sup>4</sup>, Dr. Md. Mahfuzzaman<sup>5</sup>, Dr. Md. Abdullah Al Maruf<sup>6</sup>

<sup>1</sup>Medical Officer, (Orthopaedic Surgery), Modernized District Hospital, Joypurhat, Bangladesh

<sup>2</sup>Assistant Professor Department of Orthopaedic Surgery, Rajshahi Medical College, Rajshahi, Bangladesh

<sup>3,4</sup>Junior Consultant Department of Orthopaedic Surgery, Rajshahi Medical College, Rajshahi, Bangladesh

<sup>5</sup>Consultant, Department of Orthopaedic and Traumatology, SIBL Foundation Hospital, Dhaka, Bangladesh

<sup>6</sup>Clinical Staff, Department of Orthopaedic Surgery, Asgar Ali Hospital, Dhaka, Bangladesh

DOI: [10.36347/sjmcr.2021.v09i08.007](https://doi.org/10.36347/sjmcr.2021.v09i08.007)

| Received: 01.07.2021 | Accepted: 04.08.2021 | Published: 10.08.2021

\*Corresponding author: Dr. Ataul Haque

### Abstract

### Original Research Article

Treating of ankle injuries is challenging due to swelling, risk of infection and skin necrosis in the postoperative period. After subside of swelling closed displaced bi-malleolar fracture in adult. Above the age of 18 years are treating with a one-third tubular plate for lateral malleolus and distal threaded cancellous screw or tension band wiring for medial malleolar fracture, which can be evaluated clinically and radiologically. This multicenter, nonrandomized, experimental comparative study has been carried out in Rajshahi Medical College Hospital, Rajshahi and Sador Hospitals Joypurhat in Bangladesh. From June 2017 to December 2020 in this study. Total 30 patients were split into two groups: 'A,' consists of a one-third tubular plate and distal threaded cancellous screw and another group 'B' ORIF with Small DCP or one-third tubular plate with tension band wiring for medial malleolus. The mean surgery injury interval was 11.6 days. The mean hospital stay was 4.2 days. We have assessed all patients with The Olerud C and Molander H functional score system. There were excellent practical results in 11 cases in the partially threaded vice with one-third tubular plate (73.3 percent), In 3 cases good (20%), in one case fair (6,7%) good. There were also very good functional results in 6 cases (40%), good (5%), fair in 4 cases in tension bowing wiring with one-third tubular plate (26.7 percent). The p-values were >0.05. We have classified all patients with the Danis-Weber classification system, operated Type A, B, and C categorized patients. We have used a syndesmotic screw in 10 patients that have been removed at the end of 12 weeks. All implants were removed within 2.5 years in both groups. Both the operational techniques used in the study produce excellent union rates and functional results. The study was limited in samples small and lacked long-term follow-ups in both groups.

**Keywords:** Bimalleolar ankle fracture, Functional outcome, third tubular plate, partially threaded screw, Tension band wiring.

Copyright © 2021 The Author(s): This is an open-access article distributed under the terms of the Creative Commons Attribution 4.0 International License (CC BY-NC 4.0) which permits unrestricted use, distribution, and reproduction in any medium for non-commercial use provided the original author and source are credited.

## INTRODUCTION

Ankle fractures are one of the most common lower limb fractures [1]; they account for 9 percent of all fractures [2], representing a significant portion of the trauma workload [3]. The annual incidence of ankle fracture is between 107 and 184 per 100,000 persons [4,6], and around 2 percent of ankle fractures are open fractures [4]. Ankle fractures usually affect young men and older women [7]; however, below 50, ankle fractures are common in men. After this age, females become predominant. Alcohol and slippery surfaces are each involved in nearly a third of the cases [6]. Twisting and falling wounds, followed by sports injuries, are the leading causes of knee fractures [4,5].

Diabetes and obesity in middle-aged and Older adults are associated with fractures [5]. The magnitude and direction of the deformation force applied to the ankle joints correlate directly to the fracture pattern [8]. The ankle joint consists of a hinged articulation, the lower end of the tibia and its medial malleolus, and the fibula's side malt, and the tibiofibular ligament of the lower end form deep recesses (mortissus) to articulate with the body of the talus. The side varnish of the lower fibular tibio is usually considered a syndrome. The ankle joint is supplied from the front and back tibial and fibular arteries in its blood. Branches of deep fibular, sapphire, sural and tibili nerves are internalizing the joint [8].

The medial and lateral complexes of ligaments, tibiofibular ligaments, tendons crossing the joint, classic contours, and capsular attachments are the main reason for passive stability. Gravity, muscle action, and ground reaction forces usually confer dynamic stability. Stability requires the continuous action, leaning forward, and leaning backward of soleus aided by gastrocnemius [8]. The back malleolus acts as a restriction against the subsequent translation of the talus. To divide lesions into unimalleolar (70 percent), bimalleolar (23 percent), and trimalleolar, Sir Percival Potts developed the first classification system for ankle fractures, which described fractures in terms of the number of malleolus (7 percent) [4]. Here are two other classification systems commonly used, i.e., Danis-1949 Weber's classification, Weber's 1966 change of A.O. Group, and the 1950 Lauge-Hansen classification, both due to the dissections of experimentally produced fractures and as a result of clinical and radiological testing. I was introduced to the Lauge-Hansen group [9]; the basis is the foot and the deforming force at the time of the injury.

The ankle injuries gained importance, as the body's weight is transmitted via this joint, and its stability depends on the locomotive. It must be understood that ankle damage is mixed, ligament and corporal failures due to deformation forces, and thus the complete restoration of anatomy is the primary aim of treatment. Despite the extensive discussion of malleolar fractures, the opinions in the handling of such fractures vary widely due to auxiliary classifications, reduction techniques, and subjective symptoms. Many of these fractures have been managed through manipulation reduction and prudent treatment. Breakdown and fixation are necessary for injuries such as unstable syndesmotism distasis, tri- or bimalleolar fractures.

## AIM OF THE STUDY

The closed bimalleolar ankle fractures. Treated with open reduction and internal fixation in adults over 18 years old can be assessed clinically and radiologically.

## MATERIALS AND METHODS

In Rajshahi Medical College Hospital and Sador Hospitals in Rajshahi Division Joypurhat Bangladesh. From June 2017 to December 2020, a multicenter, nonrandomized quasi-experimental study has been conducted. To assess the displaced bi-platinum ankle fracture clinically and radiologically in adults older than 18 years, treated with a third, partially threaded tube long, tubular tuber, and one-third, tension bending cord long. The study duration was two years, with a minimum of six months follow-up and a maximum 1-year follow-up. (Fifteen months on Avg). In this study, the total number of patients evaluated is 30

### Inclusion Criteria

- i. All closed ankle injury
- ii. Danis-Weber Type A, B, and C
- iii. Age over 18 and under 70 years;

### Exclusion criteria for case

- i. Danis-Weber Type A fractures
- ii. All open fractures
- iii. Age below 18 years
- iv. Old injury more than three weeks
- v. Patients who were unfit for surgery

### Management in Casualty/OPD

The patients have been thoroughly clinically evaluated upon arrival at the Casualty/OPD. The cause of the injury has been examined; vital parameters have been checked; associated head, neck, thorax, etc., have been investigated. Distal neurovascular compromising and any indications of sharing syndrome were found in local skin conditions, including fracture blasters, haemarthrosis, open or closed skin. The patient was sent for an x-ray anti positive view lateral view of the extremity involved and noticed any other related limb injuries or bony injuries. Intravenous access was sought intravenous fluids were provided according to the general condition and vital parameters. Additional osseous injuries were properly treated and immobilized. For temporary immobilization of the ankle fracture, a posterior plate was applied beneath the knee. When patients were admitted, they were again clinically thoroughly evaluated. The patients had been prepared for operations and were sent all routine investigations.

### Operative procedures

Open reduction and internal fixation were submitted to the operating procedures. A partially threaded screw and a third tube plate or tension band cord with the third tubular plate were fixed. Anesthesia was performed (spinal or general).

### Positioning

In the supine position, the patient has been retained, and the limb affected has been maintained on the operating table and externally rotated. A thigh has been applied as required to a tourniquet.

### Draping

Soap scrub and providing iodine (10 percent) solutions were used for skin over the ankle region with leg and leg. The operating field was draped with sterile sheets, and the towel clips were placed so that a later image did not overlap the fracture.

### Fixation of the fibula with one-third tubular plate

As the entire fibula's bimalleolar case is first fixed, a skin incision behind the malleol was given as the j shaped incision for lateral malleolus exposure. The incision started approximately 5 cm above the tip and extended 2.5 to 3.5 cm below it downwards and further downwards. The incision was proximally prolonged if

necessary. The hematoma and soft tissue were removed after exposure to the fracture site, and a curette was used to clean the surface. The fracture was reduced to align with the support of bone supports. Depending on the type of fracture, the one-third tubular plate was used for 5 or 6 holes. The bone was boiled with a 2.8 mm drill with a drill guide, and a 3.5 mm cortical tap was taped. The fracture had to be fixed with the cortical 3,5 mm screws.

**Fixation of medial malleolus with partially threaded screws**

An anteromedial incision has been made over the medial squirrel that begins about 2 cm near the dividing line, extends slightly backward and distally, and ends about 2 cm away at the end of the medial squirrel. The skin was retracted before and after with the underlying subcutaneous tissue—a prior retraction of the large saphenous vein and its accompanying nerve. The fracture site was exposed, and the fragments of the fracture were retracted to remove any loosely osseous or chonds. The detached fragrances were brought to normal position with a bone holder clamp or towel clip and fixed internally by two 1,5mm smooth Kirschner wires perforated as temporary fixation devices across the fracture site. A 2.8mm drill was drilled on the fracture fragments if the reduction was satisfactory, and a 4mm partially threaded screw with a 4mm screwdriver was inserted, and one Kirschner wire was removed. A second screw was then similarly placed, and the second K-wire was removed. After confirmation of fixation, A traumatically, the wound was irrigated and closed, usually with unabsorbable skin sutures that were interrupted. A back was applied after skin closure under the knee plaster slab.

**Fixation of medial malleolus by tension band wiring**

The medial malleolus was similarly incised to expose the medial malleolus, and a towel clip was used after the fragment had been cut to hold it up. Two k-wires were passed through the fragments parallel to each other. Then a rear pinhole was built up in the tibia, over 3 cm above the fracture, and less steel was crossed through the hole with a stain of 20 or 22 gauge in length. The end was crossed, and one end was tightened and twisted with a figure of 8 on the 2 k- drills and ends. The wound was closed in layers after irrigation, and Paris knee plaster was applied below.

**Postoperative management**

The ankle had been immobilized and elevated in the neutral position in the posterior plaster shapes with the ankle. Before and after surgery, a cephalosporin antibiotic was given for 24 to 48 hours and oral antibiotics for another five days. The suture was taken on the 10th day, and patients were either released. The patients had been released, and the 10th day after the OPD operation, they were called for suture removal. Regular OPD inspection was performed in months, and A.P. and lateral radiographs were obtained for one year after that. Once a wound has been cured, range-of-motion exercises began. Weight loss was limited for six weeks, and then a partial weight loss began when the fracture cured well. Depending on X-ray data of fracture consolidation, full weight-bearing was permitted. [43].

**Functional assessment**

The results were assessed with the functional score system of Olerud C and Molander H. 44 C. Olerud and H. Molander: Score scale following ankle fracture evaluation of symptoms as shown below:

	Wrapping Stick or Crutch	0
9. Work, Activities of daily life	Same as before injury	20
	Loss of tempo	15
	Change to a simple job/ part-time job	10
	Severely impaired work capacity	0

Parameters	Degree	score
1. pain	None	25
	While walking on uneven surface	20
	While walking on even surface	10
	While walking indoors	50
2. Stiffness	Constant and severe	50
	None	100
3. Swelling	Stiffness	10
	Only evening	50
4. Stair Climbing	Constant	10
	No problem	50
5. Running	Impaired	50
	Impossible	50
6. Jumping	Possible	50
	Impossible	50
7. Squatting	Possible	50
	Impossible	50
8. Supports	Possible	50
	Impossible	105

**Total Score = 180**

<b>Fair:</b>	<b>31% - 60%.</b>
Good:	61% - 90%.
Excellent:	91% - 100%.

## STATISTICAL ANALYSIS

The fullness and consistency of the data have been checked. SPSS V.21 was used to enter and analyze data as age, sex, fracture, injury mode, fracture age, operating time, weight-bearing, union time, and functional performance for windows (IBM Inc). Through Independent T-test and Chi-Square, the data were comparable between the two groups being studied. The difference when the p-value was < 0.05 was considered significant.

## RESULTS

Age, sex, fracture side distribution, mode of injury, fracture age, operational time, weight-bearing, time of union, complications, and functional results were analyzed in the following variables of each patient record. The following variables were recorded during the following follow-up: knee motion range, patient complaints about their day-to-day activities, and signs of a union. Symptoms. The results were assessed using the functional score system Olerud C and Molander H [44].

The average age of patients with a third tubular plate group with a threaded screw was 37,13 years in our present study, with a range of 18-65 years and with a third plate tubular group with tension band wiring, a medium age of 37,40 years in patients (S.D.  $\pm 12,822$ , with a range of 18-65 years in the current study. The tension band wiring for a third of the tube plate group included 8 males (53.3 percent), 7 females (46.7 percent), and the male to female ratio was 1.14:1. The tension band wiring was 1.5:2. In Kulloli SS *et al.* 45 and 1.6:1 in Shams N and *al*47, men were mainly involved in groups comparable to the male-to-female relationship of 1.44:1.

There were 9 (60.0%) fractures on the left and six on the right (40.0%) with a threaded screw with a third group of plates, and 8 (53.3%) fractures on the left-hand side of the tension band with a third group of tubular plates (46.7 percent). Fractures at the left were mainly involved in both of the groups, which in Kullali SS *et al.* [45] were comparable to 55% on the left and 45% on the right.

The most common injury in our study was in 5 (33.3%) instances of slipping/falling, followed by 4 (26.7%) and 3 (20%) sports injuries with one-third group tube plate (RTA) threaded shrinkage. In 3 cases, slippage/stumps were observed. Slipping/tumbling caused a fracture in 6 cases (40%), follows by an RTA in 4 cases (26.7%), slipping in 3 cases (20%), and sports injuries in 2 cases during tension band wiring

with one-third tubular plates (13.3 percent). The most common type of injury in both groups was slip/stumble (falling from the same level), comparable to 40% in Kulloli SS *et al.* [45]. The average time of thick-tubulated screw fracture was 5.13 days ( $\pm 1.959$ ) with tension band wiring of one-third of the tubular plate group ( $\pm 1.773$ ) and was five days ( $\sim 1.773$ ). Neither was operated as an emergency with fractures. The average fracture age was 4.8 days for Shams N *et al.* in our study [47]. We believe that it is technically a bit easier to operate the first week after the injury.

Operation time ran from 35 to 50% in a threaded tubular plate, with an average operating time of 43.00 minutes and a standard deviation of 4.551, while operating time ran from 30 to 45 mins in a threaded screw with a third tubular plate group. Operation time ran from 35 to 50% in a threaded tubular plate, with an average operating time of 43.00 minutes and a standard deviation of 4.551, while operating time ran from 30 to 45 mins in a threaded screw with a third tubular plate group.

It took less time to operate with a tension band wire with a 3rd tubular plate attachment than a 3rd tubular plate threaded vector. Statistically, significantly different was the duration of operation ( $p < 0.05$ ). We need to drill two times with the near Cortex of the 3.5 mm boiling bit in the threaded screw with the 3rd tubular plate fastener, and a second time for the distant Cortex with a 2.5 mm boiling bit while we drilled only once with a 2.50 mm boiling bit in the tension belt, we had with a 3rd tubular plate fastener [15,41].

The average hospital stays in the fully-filtered vibration group was 8.40, ranging from 5 to 12 days, and the average hospital stay in a partly threaded vessel group was 8.07 ( $\pm 2.187$ ) days, ranging from 6 to 12 days. A statistically minor comparison was made ( $p > 0.05$ ). This cannot be compared with other studies, as some patients have been discharged two or three days after surgery for stitch removal in the OPD, and some patients have been discharged following removal from the stitch. The average hospital stays in the fully-filtered vibration group was 8.40, ranging from 5 to 12 days, and the average hospital stay in a partly threaded vessel group was 8.07 ( $\pm 2.187$ ) days, ranging from 6 to 12 days. A statistically minor comparison was made ( $p > 0.05$ ). This cannot be compared with other studies, as some patients have been discharged two or three days after surgery for stitch removal in the OPD, and some patients have been discharged following removal from the stitch.

Clinically, the average union time of a third tube tubular plate group with a standard 1.302 deviation was 7.47 weeks (range 5 - 10 weeks). The strain tandem wires of a third tubular plate group with a standard deviation were 8.00 weeks (range 6-12 weeks) with a standard 1 558. The difference was insignificant

between the two groups ( $p>0.05$ ). Radiologically the meantime of threaded vent union with a third tubular plate group was 11.80 weeks (range 8-15 weeks), with 2.210 standard deviation, and 12.93 weeks (range 9-18 weeks) with a standard 2.251 standard deviation, whereas the tension band wire with a third tubular plate group. The difference between them was insignificant

It takes more time for bony band cable connectors to be clinically and radiologically fixed to a third tubular plate than a threaded tubular fixation. This is because there is a bicortical purchase in the threaded screw with one-third tubular plate mounting, a stiffer tension builds as well as an extended thread mounting length that offers excellent and strong mounting compared to one-third tubular plate mounting in the tension belt wiring [43,44,42], the differences between. The two groups were not very important in this study ( $p>0,05$ ).

Depending on the fracture union clinically detected, weight-bearing was restricted, and partial weight-bearing was permitted. The mean time for limited weight-bearing was [7,47] weeks (5-10 weeks) with a standard deviation of 1,302, while the voltage belt wiring with one-third of the tubular plates was 8,00 weeks (6-12 weeks range), and the Standard Deviation was 1,558. After the fracture had radiologically united, unrestricted weight-bearing was allowed. Meanwhile, with a standard deviation of 2.210 in voltage b, unrestricted weight-bearing with a third tubular plate group was 11.80 weeks (range 8-15 weeks)

The standard deviation of 12.93 weeks (9 to 18 weeks) is 2.251. The patient needed less time after an operation with a threaded screw with a third tubular plate group to maintain unrestricted weight-bearing than a tension belt wiring with a third tubular plate group. Still, there were statistically little differences between the two groups ( $p>0.05$ ). This was similar in Kulloli SS *et al.* [45]. To the mean unlimited 13-week weight ratio. The range moved by the tubes with a third group was

100% dorsal, 93.3% 0-50 oscillating, 80% os-20 oscillating and 86.3% oscillating, and 86.3% oscillating, while the tensile strip wire with a third group of the tubules was 100% dorsalis, 86.6% oscillating and/or 80% in oscillating, 80% in 0-20 oscillating, and 85% in the dorsal stripe, respectively 80% in the tension belt with a third tubular strip group. Comparing the movement range parameters for both groups, Patients with a good motion of a three-fold tubular plate group were found to have a good range in a threaded screw but were statistically insignificant ( $p>0,05$ ) than tension strip wiring with the third tubular plate group. In addition, 90% of the patients were thread-based with 1 3rd tube plate group and 86% with 1 3rd tubular plate group with a voltage belt wiring. In Al-Lamy WA *et al.*, that is comparable to 86% [46]. In patients who began mobilization early after surgery, the range of ankle movement was better.

Excellent functional outcomes in 11 cases (73.3%), good in 3 cases (20%), and fair in 1 case were found for the threaded screw with a third tube plate group (6.7 percent). In the voltage tape wearing of one-third of the tubular plate group, the functional outcome was excellent in 9 cases (60%), good in 4 (26.7%), and fair in 2 cases (13.3 percent). In both groups, there were no bad results. In a threaded tubular screw with one-third tubular plate group, the functions were better compared to patients with tension belt wiring with one-third tubular plate group, but statistically, the difference between them was minor ( $p>0.05$ ). In our study, 93 % of patients achieved excellent to good results in threaded screw with one-third tubular plate fixation and 86.7 % of patients achieved excellent to good results in tension band wiring with one-third tubular plate fixation. This was comparable with other studies which achieved 80 % in Al-Lamy WA *et al.* [46], 80 % in Shams N *et al.* [32], 90 % in Maruthi CV *et al.* [33], and 79 % in Ebraheim NA *et al.* [49] There were no major intraoperative or postoperative complications in both the groups.

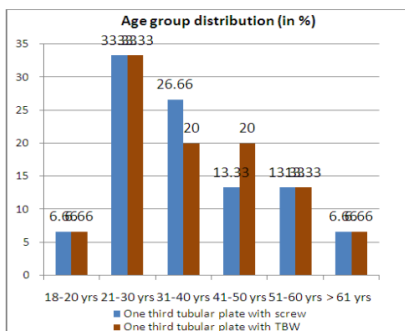


Table-1: Showing age group distribution

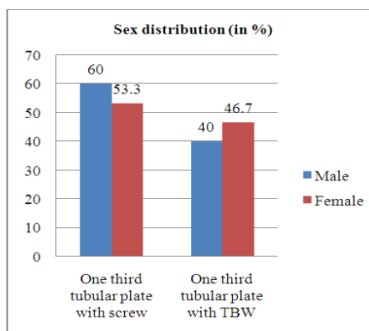


Table-2: Showing sex distribution

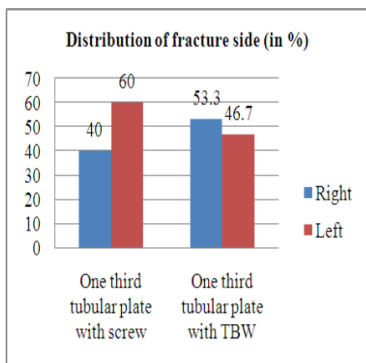


Table-3: Showing distribution of fracture side

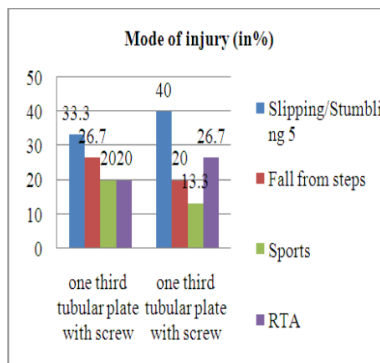


Table-4: Showing mode of injury

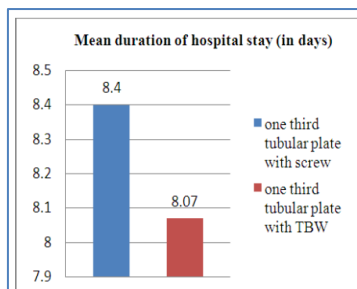


Table-5: Showing mean duration of Hospital stays (in days)

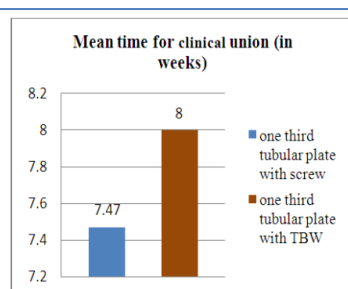


Table-6: Showing mean time for clinical union (in weeks)

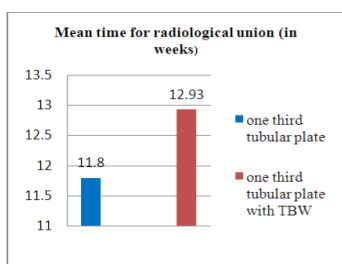


Table-7: Showing mean radiological union

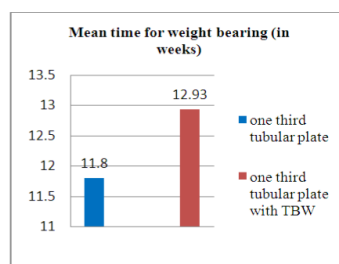


Table-8: Showing mean time for weight bearing

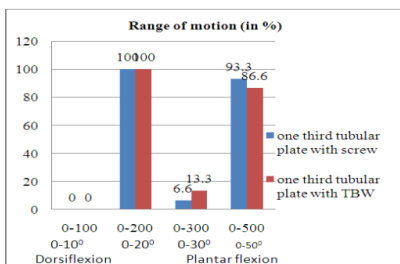


Table-9: Showing ROM dorsiflexion and planter flexion

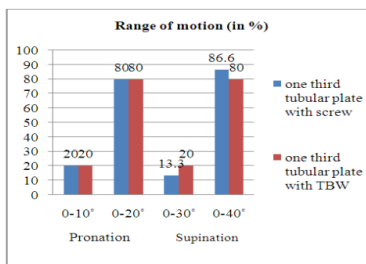
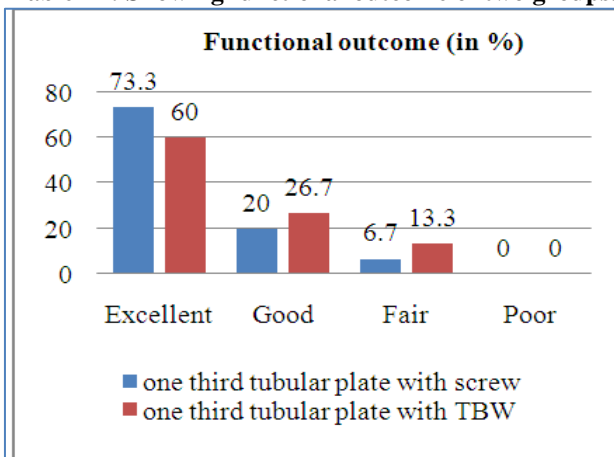
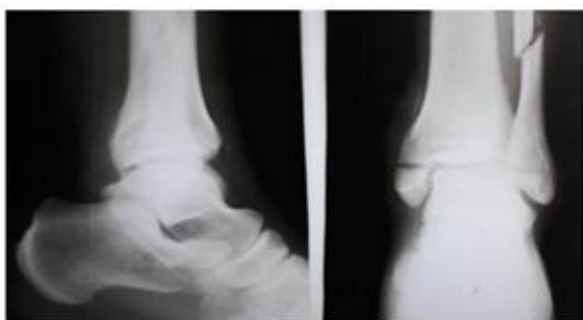

Table-10: Showing ROM pronation and supination

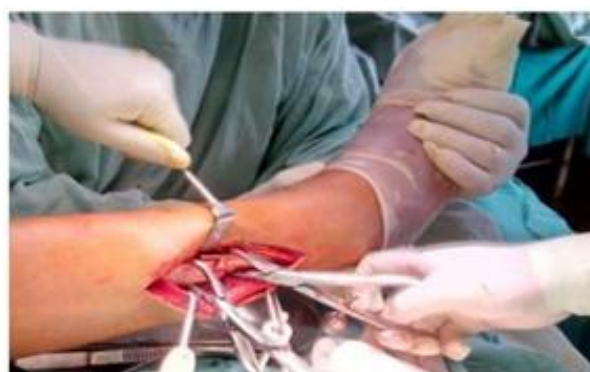**Table-11: Showing functional outcome of two groups.**



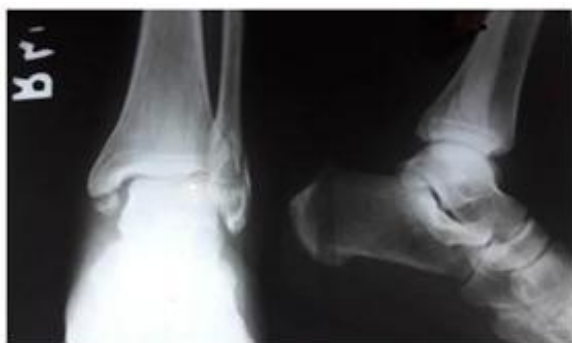**Pre-operative, Intra-operative, Postoperative and Follow up Figures**



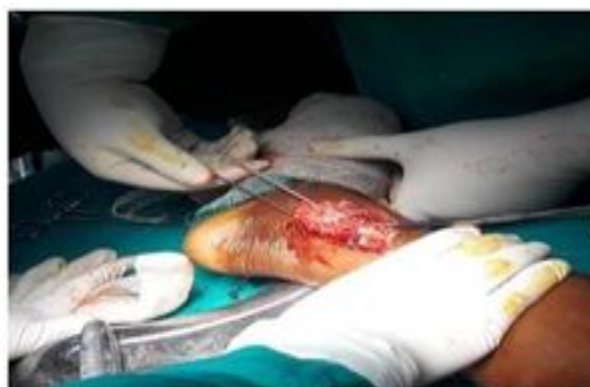**Fig-1: Pre-operative x-ray for threaded screw one third tubular plate**



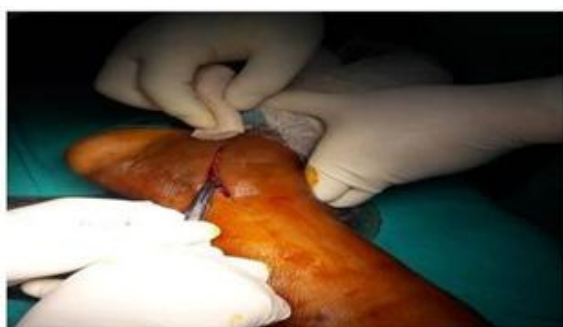**Fig-4: Fracture site exposed**



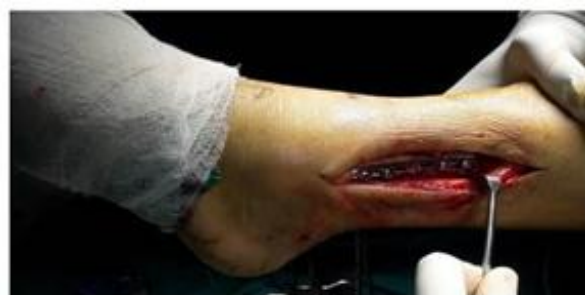**Fig-2: Pre-operative x-ray for tension band wiring with one third tubular plate**



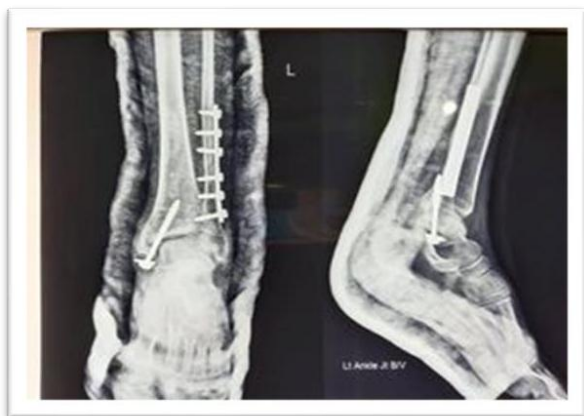**Fig 5: Fracture stabilization with K-wire**



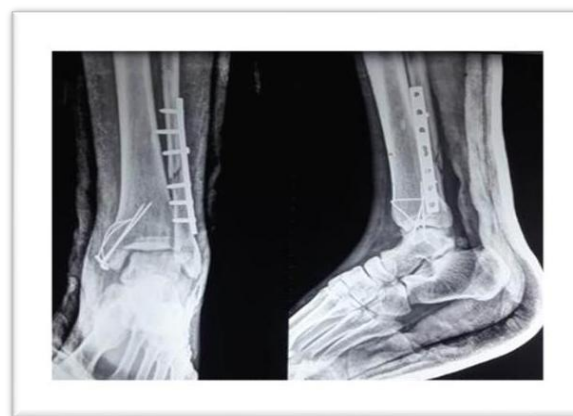**Fig-3: Skin incision**



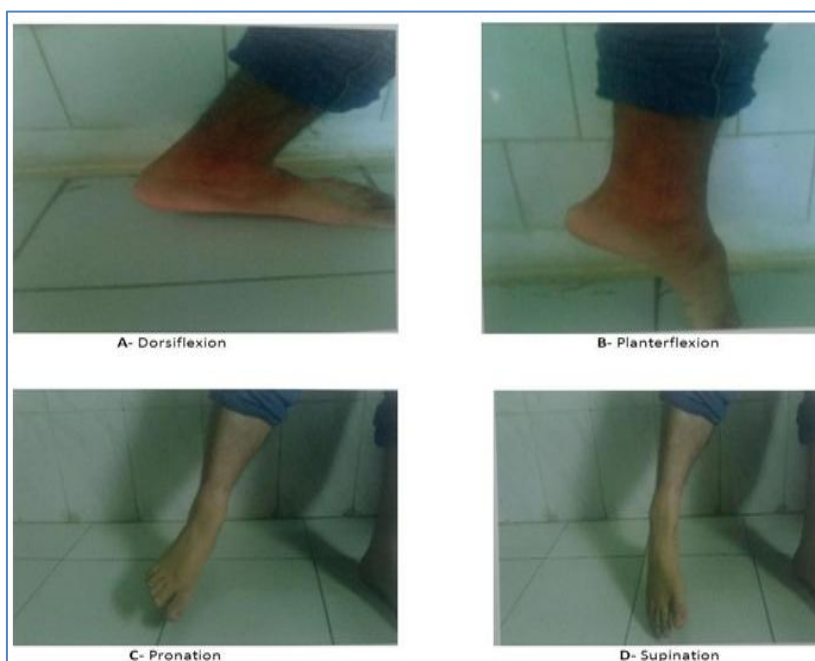
**Fig-6: Fracture fixed with screw and plate**



**Fig-7: Postoperative x-rays (Threaded Screw)**



**Fig-8: Postoperative x-rays (Tension band wiring)**



**Fig-9: Threaded Screw with one-third tubular plate: ROM**

### Complications

In our study in both groups, there were no intraoperative complications. A superficial infection on the operating site was noted in a threaded screw with a third tubular plate group. There is one case of superficial wound infection in the tension belt wiring with one-third tubular plate group that does not involve the bone.

### CONCLUSION

In this interventional study, we studied the results of a threaded spring with one-third tubular plate fixing and one-third tubular plate fixation wiring, but there were definite advantages with threaded spring with one-third tubular plate fixation with the stress belt cabling, the range of motion, weight carrying and functional outcome. The union rate for both groups was 100% unsuccessful. In the meantime, the time required for the tension band cabling with a third plate fixing was significantly reduced compared to the time needed

for a block of threaded tubular. Platinum with a third tube. Our study showed 93 percent excellent to good results with threaded screw with a 3rd tubular plate mounting and 86.7 percent excellent to good results with the voltage belt mounting of a 3rd tubular plate mount. In other studies, 80% were reported in Al-Lamy WA and al [46], 80% were reported in Shams N and al [47], 90% were reported in Maruthi CV et al. and 79% were replaced with other bimalleolar fracture fixations.

### ACKNOWLEDGMENTS

All my teachers and resident physicians who have been involved and all patients who have taken part in this study

### REFERENCES

1. Lash, N., Horne, G., Fielden, J., & Devane, P. (2002). Ankle fractures: functional and lifestyle



- outcomes at 2 years. ANZ journal of surgery, 72(10), 724-730.
2. Rudolph, D. (2017). Workers, dignity, and equitable tolling. *Nw. UJ Int'l Hum. Rts.*, 15, 126.
  3. White, To, Thordarson, D.B., Bugler, K.E. (2012). Concentrate on fractures of the ankles. *J of Bone, Joint Surg. Court-Brown J and Wilson G, McBirnie*, 94; 1107-12
  4. Ankle fractures for adults, J. (1998). A growing problem? *Scandinavian 1998 Orthopedic Acta*; 69:43-7.
  5. Daly, P. J., Fitzgerald, R. H., Melton, L. J., & Lstrup, D. M. (1987). Epidemiology of ankle fractures in Rochester, Minnesota. *Acta Orthopaedica Scandinavica*, 58(5), 539-544.
  6. Jensen, S. L., Andresen, B. K., Mencke, S., & Nielsen, P. T. (1998). Epidemiology of ankle fractures: a prospective population-based study of 212 cases in Aalborg, Denmark. *Acta Orthopaedica Scandinavica*, 69(1), 48-50.
  7. Donken, C. C., Al- Khateeb, H., Verhofstad, M. H., & van Laarhoven, C. J. (2012). Surgical versus conservative interventions for treating ankle fractures in adults. *Cochrane Database of Systematic Reviews*, (8).
  8. Clare, M. P. (2008). A rational approach to ankle fractures. *Foot and ankle clinics*, 13(4), 593-610.
  9. Daly, P. J., Fitzgerald, R. H., Melton, L. J., & Lstrup, D. M. (1987). Epidemiology of ankle fractures in Rochester, Minnesota. *Acta Orthopaedica Scandinavica*, 58(5), 539-544.
  10. Jensen, S. L., Andresen, B. K., Mencke, S., & Nielsen, P. T. (1998). Epidemiology of ankle fractures: a prospective population-based study of 212 cases in Aalborg, Denmark. *Acta Orthopaedica Scandinavica*, 69(1), 48-50.
  11. Donken, C. C., Al- Khateeb, H., Verhofstad, M. H., & van Laarhoven, C. J. (2012). Surgical versus conservative interventions for treating ankle fractures in adults. *Cochrane Database of Systematic Reviews*, (8).
  12. Michael, P., Clare, M.D. (2008). *Cochrane database. A Rational Fracture Approach. Clinics Foot & Ankle*; 13(4):593-610 *Clinics*.
  13. Forrester, D.M., Arimoto, H.K. (1980). Ankle fractures classification: an algorithm. *American Rotgenology Journal*, 135:1057-63.
  14. Harper, M. C. (1992). Ankle fracture classification systems: a case for integration of the Lauge-Hansen and AO-Danis-Weber schemes. *Foot & ankle*, 13(7), 404-407.
  15. Taweel, N. R., Raikin, S. M., Karanjia, H. N., & Ahmad, J. (2013). The proximal fibula should be examined in all patients with ankle injury: a case series of missed maisonneuve fractures. *The Journal of emergency medicine*, 44(2), e251-e255.
  16. The development of the evidence-based algorithm is a result of Polzer H., Kanz K., PRANZW. *Diagnosis and therapy of acute skin lesions. 4e 5 of the 2012 Orthopaedic Review*.
  17. Van Dijk, C. N., Lim, L. S. L., Bossuyt, P. M. M., & Marti, R. K. (1996). Physical examination is sufficient for the diagnosis of sprained ankles. *The Journal of bone and joint surgery. British volume*, 78(6), 958-962.
  18. *Rules of the Ankle of Ottawa. (1996). Family physicist of Canada*, 42; 478-480.
  19. Bachmann, E., Collector, E., Koller, M.T., Steurer, J., Riet, G. (2003). *Ottawa Ankle Rules for Excluding Ankle and Mid-Foot Fractures: Systemic assessment. WJO*, 326-417.
  20. Spooner, C.H., Dowling, S., Liang, Y. (2009). *Ottawa Ankle Rules for the Exclusion of Ankle and Midfoot fractures in children: a meta-analysis. Emergency Medicine Academic*, 1; 277-287.
  21. Stiell, I.G., Greenberg, G.H., McKnight, R.D., McDowel, I., Nair, R.C., Worthington, J.R. (1992). A study on the development of clinical decisions in Acute Ankle Injuries for the use of radiography. 21; 384-90.
  22. Bachmann, E., Collector, E., Koller, M.T., Steurer, J., Riet, G. (2003). *Ottawa Ankle Rules for Excluding Ankle and Mid-Foot Fractures: Systemic assessment. WJO*, 2003, 326-417.
  23. Dowling, S., Spooner, C. H., Liang, Y., Dryden, D. M., Friesen, C., Klassen, T. P., & Wright, R. B. (2009). Accuracy of Ottawa Ankle Rules to exclude fractures of the ankle and midfoot in children: a meta- analysis. *Academic Emergency Medicine*, 16(4), 277-287.
  24. Stiell, I. G., Greenberg, G. H., McKnight, R. D., Nair, R. C., McDowell, I., & Worthington, J. R. (1992). A study to develop clinical decision rules for the use of radiography in acute ankle injuries. *Annals of emergency medicine*, 21(4), 384-390.
  25. Brandser, E. A., Berbaum, K. S., Dorfman, D. D., Braksiek, R. J., El-Khoury, G. Y., Saltzman, C. L., ... & Clark, W. A. (2000). Contribution of individual projections alone and in combination for radiographic detection of ankle fractures. *American Journal of Roentgenology*, 174(6), 1691-1697.
  26. Egol, K.A., Amirtharajah, M., Teywani, N.C., Capla, E.L. (2004). Ankle stress test for surgical determination of fibular fractures isolated. *Bone and Joint Surgical Journal*, 86-A: 2393-8. Chapter 3 — *Foot and Ankle Imaging, Coughlin MJ, Saltzman CL*
  27. *Eds., Foot, & Ankles, Eighth Edition, Elsevier Mosby, 2006 68-96: Coughlin, M.J., Mann, R.A. and Saltzman, C.L.*
  28. Nomoto, E.K., Hoshino, C.M., Norheim, E.P., Harris, T.G. (2012). Weightbearing correlation Radiography and stress stability Positive ankle fractures. *International Foot & Ankle*, 33; 92-8.
  29. Gardner, M.J., D.D., Briggs, S.M., D.D. Holfe, D. (2006). Ability to predict Ligament injury and mechanism in Ankle fractures for the Lauge-Hansen classification: an MRI study. *J Orthelien trauma*, 20; 365-365.

30. Nielson, J. H., Gardner, M. J., Peterson, M. G., Sallis, J. G., Potter, H. G., Helfet, D. L., & Lorich, D. G. (2005). Radiographic measurements do not predict syndesmotom injury in ankle fractures: an MRI study. *Clinical Orthopaedics and Related Research (1976-2007)*, 436, 216-221.
31. Chen, C., & Tang, S. L. (2006). Hsu CC and Tseai WC. Chen CP. Ultrasonographic Inversion Sprains Associated with Osseous Injuries Inversion Test. *U.S. Physical Medicine & Rehabilitation Journal*, 85:785-92.
32. Salai, M., Novicov, I., Salai, M. (2000). The Ankle Fractures Epidemic in the Elderly—Do you warrant surgical treatment? *Orthopedic and Trauma Surgical Archives*, 120; 511-3.
33. Kher, K., Moseley, A.M., Kher, Lin, C.W., Donkers, N.A., Refshauge, K.M., Becken, kamp, P.R. (2012). Ankle fractures in adults rehabilitation. *Systematic Reviews 2012 11 Database of Cochrane*, ID of Article: CD005595.
34. Bimalleolar fracture studies treated with an open and closed method TBW, K- wire, CC screw, and semitubular plate. (2014). Dalal BY, ChaudhriKj, Bhesaniya RR. *Bimalleolar fractures*. Oct, 3(10): 322-3 Oct 2014;
35. Ramana, S.S.V., Vittal, M.P.R. (2015). Internal bimalleolar fracture attachment research. Oct 14(10):01-4. *IOSR-JDMS*.
36. Maruthi, C.V., Venugopal, N., Nanjundappa, H.C., Swamy, M.K.S. (2014). Bimalleolar ankle joint fracture controlled by tension strip cable technology: a prospective study. *B.J. Apartment Med Sci*, 2(1D).
37. Alamgir, M. H. M., Islam, M., Islam, M. N., & Kader, A. (2013). Open reduction and internal fixation of displaced fractures of lateral malleolus by tension and wiring and plating in bimalleolar fractures in adults. *Journal of Shaheed Suhrawardy Medical College*, 5(2), 81-83.
38. Federici, A., Sanguineti, F., & Santolini, F. (1993). The closed treatment of severe malleolar fractures. *Acta orthopaedica belgica*, 59(2), 189-196.
39. Kim, A., Dailey, T., Singh, S., Tsai, C.H. (2010). Open dislocated bimalleolar ankle fracture of the illizorov diabetic: early ambulation case report and stabilization. *J. Feb*; 3(2); 2 *Foot and Ankle*.
40. Early mobilization of operated on fractures of the ankle: Prospective, controlled study, 40, *Acta Orthopodica Scandinavica*, 64:1, 95-99 DOI: 10.3109/175369308994541
41. TorbjörnAhl, Nils, D., Arne, L., & Carin, B. (1993). Shah ZA, Arif U Shah ZA. Bimalleolar ankle surgical management. *J M H S Jun*, 6(2); 51-1562;
42. Motwani, G. N., Shah, H. D., Chavli, V. H., Daveswar, R. N., Parmar, H., & Suthar, P. P. (2015). Results of open reduction and internal fixation in closed bimalleolar Pott's Fracture of Ankle in Adults. *Int J Med Sci Public Health*, 4(7), 893-900.
43. Kullooli, S.S., Naik, N.P., Magdum, P.B. (2012). Ankle joint malleolar fractures management. *Management*. Nov-Dec 2012 *IOSR JDMS*, 3(3);27-31
44. Singh, S., Rangdal, S., Joshi, N., Soni, A., Sarkozy, R. (2012). Functional result of biodegradable implant-treated ankle fractures. *J*, 18(3); 153-6 *Foot and ankle*.
45. Wei, S. Y., Okereke, E., Winiarsky, R., & Lotke, P. A. (1999). Nonoperatively treated displaced bimalleolar and trimalleolar fractures: a 20-year follow-up. *Foot & ankle international*, 20(7), 404-407.
46. Parker, L., Garlick, N., McCarthy, I., Grechenig, S., Grechenig, W., & Smitham, P. (2013). Screw fixation of medial malleolar fractures: a cadaveric biomechanical study challenging the current AO philosophy. *The bone & joint journal*, 95(12), 1662-1666.
47. Fowler, T. T., Pugh, K. J., Litsky, A. S., Taylor, B. C., & French, B. G. (2011). Medial malleolar fractures: a biomechanical study of fixation techniques. *Orthopedics*, 34(8), e349-e355.
48. Smitham, P., Parker, L., Garlick, N., McCarthy I. (2012). Is it better to have a short screw? Trends in fixation of medial malleolus fractures and higher efficiency of shorter cancellular, fully threaded tissues. *J Bone Surg Joint Br*, 94- B(58):134–6.
49. Kullooli, S. S., Magdum, P. B., & Naik, N. P. (2012). Evaluation of management of malleolar fractures of ankle joint. *IOSR J Dent Med Sci*, 3, 27-31.
50. Comparative study of internal fixation using malleolar screw against the tension-band wiring of a moved closed fracture. *J Med*, 2(4); 308-18.
51. Shams, N., & Ahmed, I., Hegde, A., Shams, N., & Ahmed, A. (2014). A study on ankle fracture surgery – 21 cases are included in a clinical study. *Biomedical and Advance Research International Journal*, 5(4); 190-2.
52. Maruthi, C.V., Siddalingaswamy, M.K., Venugopal, N., Nanjundappa, H.C. (2014). Bimalleolar ankle joint fracture managed by wiring technique for the tension band: a prospective study. *B.J. Apartment Med Sci*, 2(1D).
53. Ludwig, T., Weston, J.T., Carroll, T., Liu, J. (2014). Comparison of 111 medial maleolar fractures of surgical techniques classified by geometric fracture. *Ankle Foot Int*, 35(5); 471-7.
54. Tian, Li, T.S, Chu, J.J., Xiong, M.Y., Du, H., Tian, X.X. (2011). Closed reduction and percutaneous internal fixation of medial malleolus fractures. *01/12/19/2011;24(9)*; 788-90.