

## Lipobrachioplasty for Lipodystrophy of the Arms – A Series of 3 Cases

Surya Rao Rao Venkata Mahipathy<sup>1\*</sup>, Alagar Raja Durairaj<sup>2</sup>, Narayanamurthy Sundaramurthy<sup>3</sup>, Anand Prasath Jayachandiran<sup>4</sup>, Suresh Rajendran<sup>5</sup>

<sup>1</sup>Professor & Head, Dept. of Plastic & Reconstructive Surgery, Saveetha Medical College & Hospital, Thandalam, Kanchipuram Dist. 602105, Tamilnadu, India

<sup>2</sup>Professor, Dept. of Plastic & Reconstructive Surgery, Saveetha Medical College & Hospital, Thandalam, Kanchipuram Dist. 602105, Tamilnadu, India

<sup>3</sup>Associate Professor, Dept. of Plastic & Reconstructive Surgery, Saveetha Medical College & Hospital, Thandalam, Kanchipuram Dist. 602105, Tamilnadu, India

<sup>4</sup>Assistant Professor & Head, Dept. of Plastic & Reconstructive Surgery, Saveetha Medical College & Hospital, Thandalam, Kanchipuram Dist. 602105, Tamilnadu, India

<sup>5</sup>Senior Resident, Dept. of Plastic & Reconstructive Surgery, Saveetha Medical College & Hospital, Thandalam, Kanchipuram Dist. 602105, Tamilnadu, India

DOI: [10.36347/sasjs.2021.v07i08.012](https://doi.org/10.36347/sasjs.2021.v07i08.012)

| Received: 18.07.2021 | Accepted: 23.08.2021 | Published: 25.08.2021

\*Corresponding author: Dr. Surya Rao R V M

### Abstract

### Case Report

Bulky upper arms with skin and fat excess have become a common problem with aging and especially after the massive weight reduction. Arm contouring procedures can be divided into three groups, those dealing with skin redundancy, lipodystrophy, and a combination of both which may require only skin excision, liposuction or both. Lipobrachioplasty is a method to address these issues safeguarding the vascular, lymphatic and neural tissue and hence reduces the rate of complications but resulting in a good contour. Here, we present three cases of bilateral lipodystrophy managed with lipobrachioplasty with good outcomes.

**Keywords:** Contour, Lipodystrophy, Lipobrachioplasty, Complication, Outcome.

**Copyright © 2021 The Author(s):** This is an open-access article distributed under the terms of the Creative Commons Attribution 4.0 International License (CC BY-NC 4.0) which permits unrestricted use, distribution, and reproduction in any medium for non-commercial use provided the original author and source are credited.

## INTRODUCTION

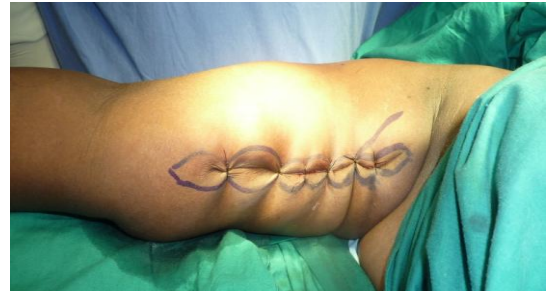Thorek first described brachioplasty as a surgical procedure to improve arm shape and over years many surgeons have used many techniques to correct skin deformity, achieve good aesthetic results and reduce the incidence of postoperative complications [1-5]. The increasing incidence of bariatric surgery and the massive weight loss (MWL) has resulted in various body deformities, therefore the increasing need for body contouring surgery [2, 6]. The issues of skin excess and ptosis of the arms, abdomen, hips, and thighs are significant enough to cause functional impairments, skin inflammation, and infections as well as considerable psychological impairment [7, 8]. The arms are usually the first body part to be treated at it is the most visible area, compromising body harmony. Brachioplasty is a commonly performed procedure but the rate of postoperative complications such as hematomas, lymphedema, or skin sensitivity disorders still remains high because of the well vascularised and neurotised surgical field, with increased lymphatics [8-13]. Illouz in 1980 has been combining liposuction with body contouring techniques [14]. Liposuction can be

used in the arm either alone in the case of mild skin laxity and ptosis or in conjunction with surgical resection where it is used to refine arm contouring [15].

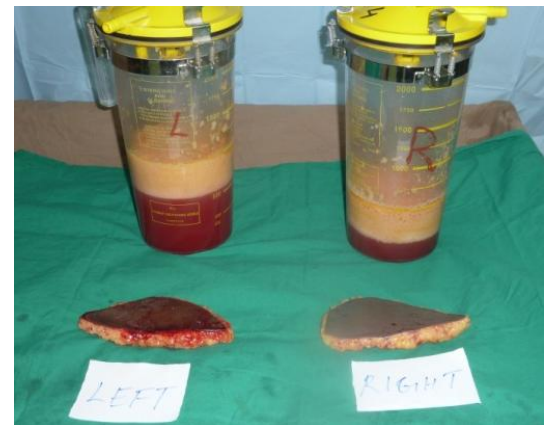## CASE REPORTS

22 year old female presented with bilateral bulky arms since 6 years. It started spontaneously and gradually increased to the present size. There was no history of pain or ulceration. She gives history of occasional skin rashes in the skin folds. There were no other co-morbid illnesses present. On examination, the patient was obese with a BMI of 29kg/m<sup>2</sup>. The arms were bulky especially in the posteromedial and posterolateral aspects of the arm. There was an increased skin fold thickness and subcutaneous fat present. A clinical diagnosis of lipodystrophy was made and we planned for bilateral lipobrachioplasty. (Fig. 1) The areas were marked pre-operatively for liposuction and skin excess in the standing position with the shoulders abducted at 90 degrees. (Fig. 2) Under general anaesthesia, 500ml of tumescent fluid was infiltrated in each arm with an infusion cannula. Liposuction was done and 500ml of liquefied fat was aspirated from each arm. (Fig. 3) The area for reduction

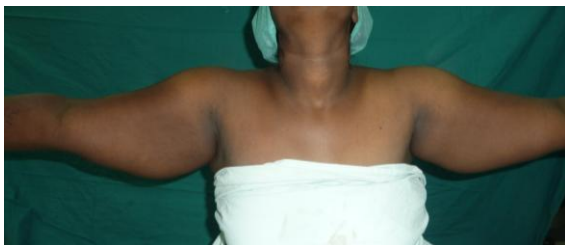brachioplasty was re-confirmed. Mock reduction was done by reducing the area with interrupted sutures and amount of skin flap to be excised was confirmed in the medial aspect. (Fig. 4) The marked area was excised sequentially and a total of 700gm of skin and subcutaneous adipose tissue on each side was removed. (Fig. 5) Haemostasis was secured and the incision was closed in layers with 2-0 polyglactin and 3-0 nylon sutures over a suction drain. Compression dressings applied. Post-operative was uneventful and sutures were removed on the 14<sup>th</sup> post-operative day. (Fig. 6) Compression garments was advised for a period of three months. Another two more cases, a 38 year old female with a BMI of 26kg/m<sup>2</sup> and a 32 year old female with a BMI of 27kg/m<sup>2</sup> came with similar complaints and bilateral lipobrachioplasty was done for both the patients with good results (Fig. 7, 8). One patient had seroma formation which was evacuated and managed conservatively.



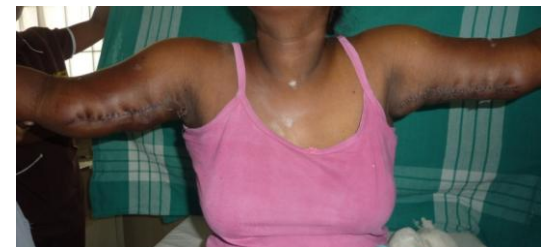**Fig-4: Mock reduction brachioplasty done**



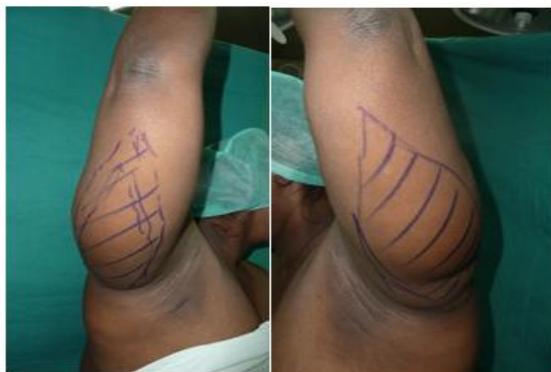**Fig-5: Aspirate and skin excision specimens**



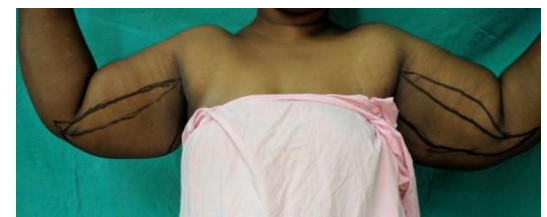**Fig-1: Pre-operative photograph of patient 1 showing bilateral lipodystrophy of the arms**



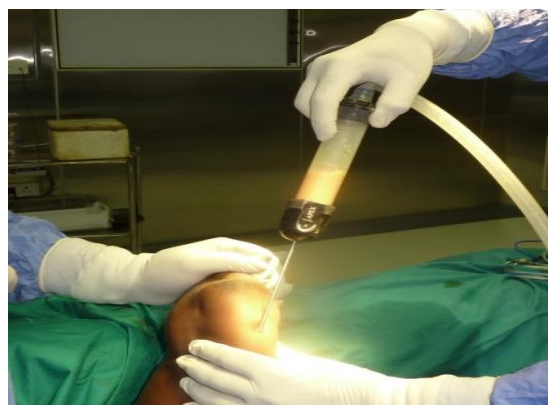**Fig-6: Early post-operative picture**




**Fig-2: Picture showing the areas marked for liposuction**



**Fig-7: Patient 2 with bilateral lipodystrophy**



**Fig-3: Liposuction being done**



**Fig-8: Early post-operative photograph**

## DISCUSSION

Brachioplasty is a procedure to treat lipodystrophy and ptosis caused by massive weight loss after bariatric surgery. This procedure has many complications such as hematoma, seroma, paresthesia and scar as nerves, blood vessels, and lymphatics of the

arm are located just beneath the area of resection Strauch *et al.* [9-13] proposed to place the scar in the posterior part of the arm where lymphatic vessels are fewer but there was an increased risk of damaging the subcutaneous placed posterior branch of the medial cutaneous antebrachial nerve [13, 16]. Few surgeons who prefer the medial arm scar argue that posterior scars are prone for hypertrophy and difficult to camouflage [17, 18]. The arms of these patients present with two types of problems, excess volume due to residual fat and excess skin which are both addressed by lipobrachioplasty [19]. Brachioplasty combined with liposuction was described by Pascal and Le Louarn in 2005 [20]. Gusenoff *et al.* in his study stated that brachioplasty could be safe if combined with other procedures, and Bossert *et al.* [9] mentioned that the complication rate of the patient who underwent brachioplasty with medial scar alone was the same as that of the patient who underwent brachioplasty and liposuction of the posterior arm [12, 21]. Aly sustained that combination of liposuction and brachioplasty is not safe because tissue edema makes correction more difficult resulting in over- or under-resection [22]. Gilliland and Lyos have advocated circumferential para-axillary liposuction in the superficial and/or subdermal planes to improve skin retraction. These authors also demonstrated the reliability of liposuction to effect skin retraction in the posteromedial and posterolateral aspects of the arm [23, 24]. The overall aesthetic result is satisfactory for the lipobrachioplasty procedure, especially with the absence of drains and external sutures, in addition to decreased axillary sweating which is disabling in obese patients.

## CONCLUSION

Lipobrachioplasty is surgical procedures where the unsightly arms of a massive weight loss reduction patient are addressed resulting in a good aesthetic outcome. This is associated with low complications compared to brachioplasty alone and now it has become the procedure of choice.

## REFERENCES

- Illouz, Y. G. (1990). Study of subcutaneous fat. *Aesthetic plastic surgery*, 14(1), 165-177.
- Cosmetic Surgery National Data Bank Statistics. (2016). *Aesthet Surg J*, 13; 1–29.
- Juri, J., Juri, C., & Elfas, J. C. (1979). Arm dermolipectomy with a quadrangular flap and "T" closure. *Plastic and reconstructive surgery*, 64(4), 521-525.
- Lockwood, T. (1995). Brachioplasty with superficial fascial system suspension. *Plastic and reconstructive surgery*, 96(4), 912-920.
- Lillis, P.J. (1999). Liposuction of the arms. *Dermatol Clin*, 13; 783–97.
- American Society of Plastic Surgeons. (2015). [Accessed June 19, 2015] Plastic Surgery Trends 2015.
- Koller, M., Schubhart, S., Hintringer, T. (2013). Quality of life and body image after circumferential body lifting of the lower trunk: A prospective clinical trial. *Obes Surg*; 13: 561–6.
- Van der Beek, E. S., Geenen, R., de Heer, F. A., van der Molen, A. B. M., & van Ramshorst, B. (2012). Quality of life long-term after body contouring surgery following bariatric surgery: sustained improvement after 7 years. *Plastic and reconstructive surgery*, 130(5), 1133-1139.
- Teimourian, B., & Malekzadeh, S. (1998). Rejuvenation of the upper arm. *Plastic and reconstructive surgery*, 102(2), 545-51.
- Symbas, J. D., & Losken, A. (2010). An outcome analysis of brachioplasty techniques following massive weight loss. *Annals of plastic surgery*, 64(5), 588-591.
- Zomerlei, T. A., Neaman, K. C., Armstrong, S. D., Aitken, M. E., Cullen, W. T., Ford, R. D., ... & VanderWoude, D. L. (2013). Brachioplasty outcomes: a review of a multipractice cohort. *Plastic and reconstructive surgery*, 131(4), 883-889.
- Bossert, R. P., Dreifuss, S., Coon, D., Wollstein, A., Clavijo-Alvarez, J., Gusenoff, J. A., & Rubin, J. P. (2013). Liposuction of the arm concurrent with brachioplasty in the massive weight loss patient: is it safe?. *Plastic and reconstructive surgery*, 131(2), 357-365.
- Knoetgen III, J., & Moran, S. L. (2006). Long-term outcomes and complications associated with brachioplasty: a retrospective review and cadaveric study. *Plastic and reconstructive surgery*, 117(7), 2219-2223.
- Thorek, M. (1930). *Esthetic surgery of the pendulous breast, abdomen and arms in the female*.
- Song, A. Y., Jean, R. D., Hurwitz, D. J., Fernstrom, M. H., Scott, J. A., & Rubin, J. P. (2005). A classification of contour deformities after bariatric weight loss: the Pittsburgh Rating Scale. *Plastic and reconstructive surgery*, 116(5), 1535-1544.
- Strauch, B., Greenspun, D., Levine, J., & Baum, T. (2004). A technique of brachioplasty. *Plastic and reconstructive surgery*, 113(3), 1044-1048.
- Vogt, P. A., & Baroudi, R. (1994). Brachioplasty and brachial suction-assisted lipectomy. *Mastery of Plastic and Reconstructive Surgery. Boston: Little, Brown*, 2219-2236.
- Hurwitz, D. J., & Holland, S. W. (2006). The L brachioplasty: an innovative approach to correct excess tissue of the upper arm, axilla, and lateral chest. *Plastic and Reconstructive Surgery*, 117(2), 403-411.
- Labardi, L., Gentile, P., Gigliotti, S., Marianetti, M., Colicchia, G. M., Pascali, M., ... & Cervelli, V. (2012). Medial thighplasty: horizontal and vertical procedures after massive weight loss. *Journal of cutaneous and aesthetic surgery*, 5(1), 20.

20. Pascal, J. F., & Le Louarn, C. (2005). Brachioplasty. *Aesthetic plastic surgery*, 29(5), 423-429.
21. Gusenoff, J. A., Coon, D., & Rubin, J. P. (2008). Brachioplasty and concomitant procedures after massive weight loss: a statistical analysis from a prospective registry. *Plastic and reconstructive surgery*, 122(2), 595-603.
22. Bossert, R. P., Dreifuss, S., Coon, D., Wollstein, A., Clavijo-Alvarez, J., Gusenoff, J. A., & Rubin, J. P. (2013). Liposuction of the arm concurrent with brachioplasty in the massive weight loss patient: is it safe?. *Plastic and reconstructive surgery*, 131(2), 357-365.
23. Gilliland, M. D., & Lyos, A. T. (1997). CAST liposuction of the arm improves aesthetic results. *Aesthetic plastic surgery*, 21(4), 225-229.
24. Gilliland, M. D., & Lyos, A. T. (1997). CAST liposuction: An alternative to brachioplasty. *Aesthetic plastic surgery*, 21(6), 398-402.