

Pulmonary Nocardiosis in an Immunocompetent Patient: - A Rare Case Report from A Tertiary Care Hospital in Tripura

Dr. Ashmita Banik¹, Dr. Tapan Majumdar^{2*}

¹Post Graduate Trainee, Dept of Microbiology, AGMC & GBP Hospital, Agartala, Tripura India

²Professor & HOD, Dept of Microbiology, AGMC & GBP Hospital Tripura India

DOI: [10.36347/sjmcr.2021.v09i08.015](https://doi.org/10.36347/sjmcr.2021.v09i08.015)

| Received: 02.07.2021 | Accepted: 05.08.2021 | Published: 29.08.2021

*Corresponding author: Dr. Tapan Majumdar

Abstract

Case Report

Nocardiosis has become a recent emerging pathogen in the backdrop of increasing number of immuno-compromised patients, but it's diagnosis cannot be overlooked in immunocompetent patients. We represented a case of 67 year old non diabetic non hypertensive female who was suffering from fever with chills, cough, exertional dyspnea, loss of weight for 2 months who was misdiagnosed as a case of presumptive pulmonary tuberculosis and was treated with Cat-I anti-TB drugs. Later when symptoms worsen, a thorough microbiological investigation was done for both aerobic, anaerobic bacteria and multidrug resistant mycobacteria and Nocardia spp was diagnosed.

Keywords: Nocardiosis Immunocompetent Pulmonary.

Copyright © 2021 The Author(s): This is an open-access article distributed under the terms of the Creative Commons Attribution 4.0 International License (CC BY-NC 4.0) which permits unrestricted use, distribution, and reproduction in any medium for non-commercial use provided the original author and source are credited.

INTRODUCTION

Nocardiosis, a neglected tropical disease, caused by gram-positive, weakly acid-fast, filamentous aerobic actinomycetes. Being an opportunistic pathogen, it is a possible cause of pulmonary and systemic infection in immunocompromised patients. However it can be isolated in otherwise immunocompetent patients. At least 15% of the Nocardial infections occur in patients without a definable predisposing condition [1]. Nocardia can infect multiple organs, pulmonary nocardiosis being the commonest manifestation.

Nocardia has varied geographical presence and a wide spectrum of clinical presentations. Annually 500–1,000 cases are reported in the USA [2] and 90–130 in Italy [3]. It is also prevalent in various parts of the world including tropical areas like India, Pakistan, Iran, and also Canada, Spain, and Australia in significant numbers [4]. The incidence of nocardiosis seems to be increasing every year due to increases in the population and immunocompromised patients [4]. Clinical diagnosis of pulmonary nocardiosis is difficult due to the similarity of its presentation with other respiratory pathogens that include other actinomycetes members and mycobacterium tuberculosis. Due to difficulty in disease recognition, the reported cases are few and the literatures are limited [5]. Here we report a case of pulmonary nocardiosis that resembled

tuberculosis without any definable predisposing condition.

CASE REPORT

A 67 years old female from a rural area, non-hypertensive, non-diabetic, was suffering from fever with chills, productive cough, exertional dyspnea, loss of weight & appetite since 2 month. She was clinically examined and treated with Tab Azithromycin 500mg once daily for 3 days at local primary Health centre. Patient was unresponsive to initial treatment, following which; she was treated with Tab Amoxycilin calulanate, 625mg thrice daily for 5 days. As patient was still unresponsive, she was advised for a chest X-ray & sputum smear microscopy. Her chest X-ray PA view was showing multiple nodular lesions around hilar region. Sputum smear microscopy was negative for acid fast bacilli on Ziehl-Neelsen (ZN) stain with 25% H₂SO₄. She was clinically diagnosed as a case of pulmonary tuberculosis and was put on Cat-I anti-TB regime in the nearest directly observed treatment short course (DOTS) centre, in her home town. She had completed the whole 6 months course. But symptoms did not subside and cough persisted. Second sample of sputum was sent to Dept of Microbiology, AGMC, and Tripura. Sample was processed for smear microscopy with gram staining, ZN staining, CBNAAT, Liquid culture for MTB & aerobic & anaerobic culture on blood agar, chocolate agar, nutrient agar and

Saboraud's Dextrose Agar for growth of other organisms.

Gram stain of the sputum smear showed pus cells, epithelial cells, and filamentous gram positive bacilli. CBNAAT gave negative result for MTB. Modified ZN stain of sputum smear with 1% H₂SO₄ decoloriser showed nonacid fast bacilli. Sample was inoculated on BHI agar and incubated at 37° C, in anaerobic gas jar for 72 hours. However no anaerobic microbes were grown. For aerobic culture, sample was inoculated on SDA, blood agar, nutrient agar, BHI agar & Middle brook 7H9 (for growth of mycobacterium tuberculosis), and incubated at 37° C. Growth appeared after 10 days. Creamy, wrinkled, moist, opaque colony

appeared on nutrient agar media, non-haemolytic, greyish white, small colony appeared on blood agar. Growth appeared on Middle brook 7H9 also in the form of flakes. Motility was tested by hanging drop method. It was a non-motile bacillus. Gram staining from the colony showed gram positive filamentous bacilli. ZN staining from the growth with 25% H₂SO₄ showed non acid-fast bacilli & with 1% H₂SO₄ showed acid-fast bacilli. Based on colony morphology, gram stain & other biochemical tests, nocardia species was diagnosed. Based on antibiotic sensitivity test, she was advised to take cotrimoxazole & imipenem for 6 months. Following that, the patient made an uneventful recovery.

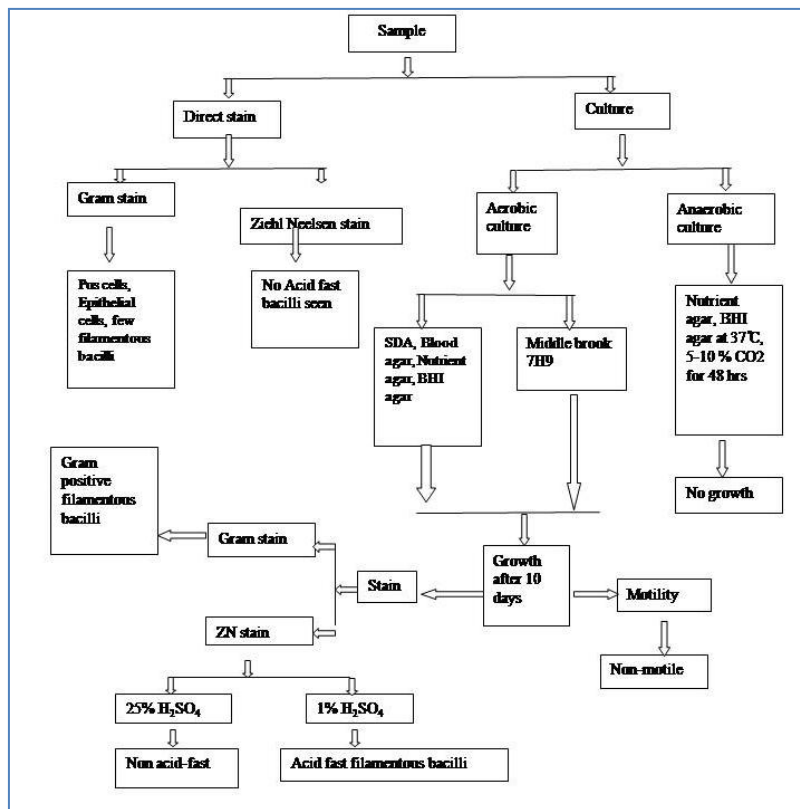


Fig-1: Diagnostic Algorithm for pulmonary nocardiosis

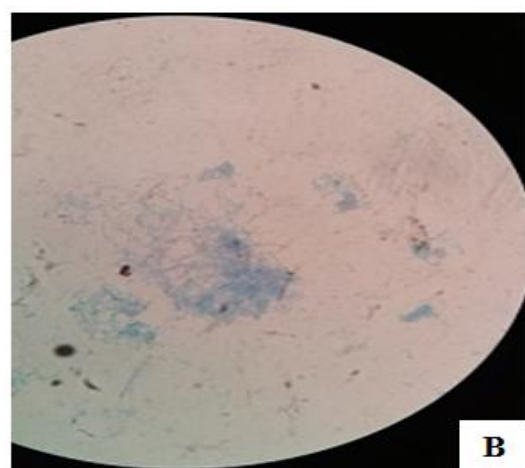
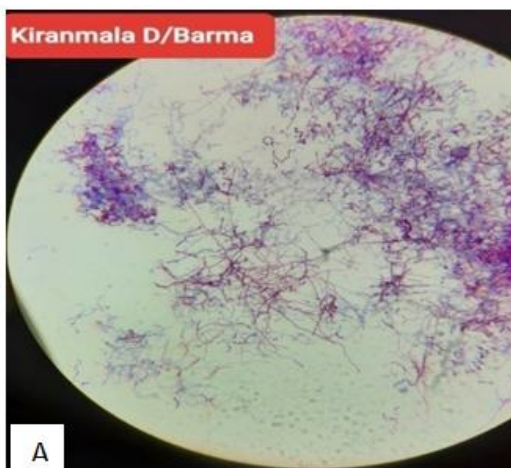
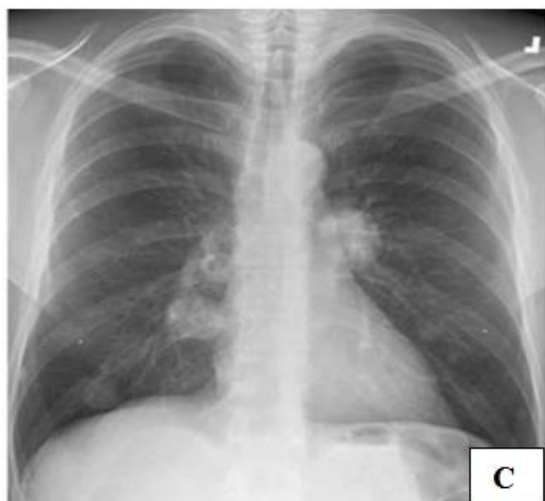



Fig-2: A. Acid Fast bacilli with 1% H₂SO₄ as decoloriser. B. Non Acid- Fast bacilli with 25% H₂SO₄ as decolorizer C. Chest X-Ray PA View showing nodular opacity around the hilar region

DISCUSSION

Nocardiosis is an infectious disease affecting either the lungs (pulmonary nocardiosis) or the whole body (systemic nocardiosis). It is due to infection by bacterium of the genus *Nocardia*, most commonly *Nocardia asteroides* or *Nocardia brasiliensis*. *Nocardia* are thin, gram-positive, weak acid-fast, aerobic branching, filamentous, slow-growing, soil-borne bacteria. Speciation of *Nocardia* is difficult from a laboratory standpoint, as the taxonomy continues to evolve with new species identification which shows variability in their biochemical properties & antimicrobial susceptibilities [6]. It is a global problem, though more common in the tropics; disease frequency is increasing due to increase in traveling and immunocompromised patients. Pulmonary nocardiosis is the commonest presentation but no part of the body is exempted [6]. A Canadian study done over 2 decades revealed an increase in the annual incidence of *Nocardia* infection/colonization from 0.33 (1997–1998) to 0.87 (2007–2008) per 100,000 inhabitants ($p = 0.001$) [11], whereas a multicentric European study found no increase in hospitalization rates due to pulmonary nocardiosis between 2005 and 2011 [6].

Nocardiosis is usually an opportunistic infection. The majority of patients with clinically recognized disease have predisposing conditions like diabetes mellitus, hematologic & other malignancies, transplantation & AIDS. Majority of primary cases present as pulmonary disease, although traumatically induced local abscesses occur as well [7]. But it can be isolated in otherwise immunocompetent patients that consisted at least 15% of the infections in patients without a definable predisposing condition [8]. In this case, the patient had no predisposing immunocompromised state. The onset of symptoms may be subacute to more chronic and can include

productive or non-productive cough, shortness of breath, chest pain, hemoptysis, fever, night sweats, weight loss, and progressive fatigue [9]. In this study patient complained of fever with chills & productive cough, exertional dyspnea, weight loss and loss of appetite. The chest radiograph can be variable, displaying focal or multifocal disease with nodular and/or consolidation infiltrate as well as cavitory lesions [9]. Her chest X-ray showed multiple nodules at hilar region, suggestive of focal pulmonary fibrosis. Clinical presentation of pulmonary nocardiosis is variable & non-specific with a chronic course.

CONCLUSION

This case highlights that pulmonary nocardiosis should be kept in mind in immunocompetent patients, especially in suspected case of tuberculosis as the clinical manifestations resembled the signs & symptoms of tuberculosis and not responding to antitubercular therapy and showing no acid-fast bacilli on ZN-staining of direct smear or the smear prepared from culture.

In TB endemic countries most of the time if symptoms are attributed to pulmonary tuberculosis, initiation of anti-tubercular therapy is advised. So to exclude nocardiosis or other infection along with mycobacterial culture, bacteriological culture (aerobic & anaerobic) and antibiotic sensitivity test should be done. One should always consider pulmonary nocardiosis in the differential diagnosis of pneumonia & also in immuno-competent patients not responding to empirical treatment and when radiological features are atypical. Rapid diagnostic tools are in urgent need for early diagnosis & treatment initiation.

REFERENCE

1. Yaşar, Z., Acat, M., Onaran, H., Özgül, M. A., Fener, N., Talay, F., & Çetinkaya, E. (2014). An unusual case of pulmonary nocardiosis in immunocompetent patient. *Case reports in pulmonology*, 2014.
2. Beaman, B. L., Burnside, J., Edwards, B., & Causey, W. (1976). Nocardial infections in the United States, 1972–1974. *Journal of Infectious Diseases*, 134(3), 286-289.
3. Farina, C., Boiron, P., Ferrari, I., Provost, F., & Goglio, A. (2001). Report of human nocardiosis in Italy between 1993 and 1997. *European journal of epidemiology*, 17(11), 1019-1022.
4. Fatahi-Bafghi, M. (2018). Nocardiosis from 1888 to 2017. *Microbial pathogenesis*, 114, 369-384.
5. Baburao, A., Prasad, S., Prakash, S., & Narayanswamy, H. (2019). Pulmonary nocardiosis: Report of two cases from a tertiary care hospital. *Indian Journal of Pathology and Microbiology*, 62(1), 153.
6. Saubolle, M. A., & Sussland, D. (2003). Nocardiosis: review of clinical and laboratory

- experience. *Journal of clinical microbiology*, 41(10), 4497-4501.
7. Diioia, A., Kalra, L., & Krop, L. C. (2021). Stroke like presentation of disseminated CNS *Nocardia beijingensis* infection in an immunocompetent patient: Case report and review of the literature. *IDCases*, e01223.
 8. Duggal, S. D., & Chugh, T. D. (2020). Nocardiosis: a neglected disease. *Medical Principles and Practice*, 29(6), 514-523.
 9. Mazumder, S.A., Bronze, M.S. (2021). Nocardiosis Workup Updated. March 09 2021. Accessible at <https://emedicine.medscape.com/article/224123-workup>, accessed on 25-07-21
 10. Wilson, J.W. (2012). Nocardiosis: updates and clinical overview. *Mayo Clin Proc*, 87(4); 403-7.
 11. Tremblay, J., Thibert, L., Alarie, I., Valiquette, L., & Pépin, J. (2011). Nocardiosis in Quebec, Canada, 1988–2008. *Clinical microbiology and infection*, 17(5), 690-696.