

## Root Resorption with Tads

Sharath Kumar Shetty<sup>1</sup>, Bibi Ameena<sup>2\*</sup>, Mahesh Kumar Y<sup>3</sup>, Vijayananda K. Madhur<sup>4</sup>

<sup>1</sup>Professor & HOD, Department of Orthodontics and Dentofacial Orthopaedics, K. V. G. Dental College and Hospital, Sullia, Karnataka, India

<sup>2</sup>Post Graduate Student, Department of Orthodontics and Dentofacial Orthopaedics, K. V. G. Dental College and Hospital, Sullia, Karnataka, India

<sup>3</sup>Professor, Department of Orthodontics and Dentofacial Orthopaedics, K. V. G. Dental College and Hospital, Sullia, Karnataka, India

<sup>4</sup>Reader, Department of Orthodontics and Dentofacial Orthopaedics, K. V. G. Dental College and Hospital, Sullia, Karnataka, India

DOI: [10.36347/sjds.2021.v08i07.012](https://doi.org/10.36347/sjds.2021.v08i07.012)

| Received: 30.06.2021 | Accepted: 31.07.2021 | Published: 30.08.2021

\*Corresponding author: Bibi Ameena

### Abstract

### Review Article

Apical root resorption is an undesirable, but frequent side effect of orthodontic treatment, Orthodontic tooth movement involves a series of biologic reactions after force application, which makes teeth vulnerable to root resorption. It develops when the natural protection of the predentine and odontoblasts in the root canal, or the precementum and cementoblasts on the root surface are damaged or removed. Orthodontic forces are just one of several aetiological factors that have been implicated in external root resorption.

**Keywords:** orthodontic treatment, tooth movement, biologic reactions, Tads.

Copyright © 2021 The Author(s): This is an open-access article distributed under the terms of the Creative Commons Attribution 4.0 International License (CC BY-NC 4.0) which permits unrestricted use, distribution, and reproduction in any medium for non-commercial use provided the original author and source are credited.

## INTRODUCTION

Apical root resorption is a common idiopathic problem associated with orthodontic treatment and has recently received considerable attention because of medicolegal exposure. External apical root resorption (EARR) is a wellknown sequelae of orthodontic treatment. The concentration of forces on the root apex during tooth movement is a mechanical effect that seems to trigger biologic events associated with apical root resorption especially in deviated root shapes. Excessive orthodontic loading can lead to more destruction of cementoblasts by compression of these cells and the periodontal blood vessels, increasing tooth root vulnerability to the resorption process. Root resorption is frequently thought to be an iatrogenic consequence of orthodontic treatment. Several treatment factors have been investigated and related to loss of root length— e.g., retraction and intrusion—which were considered the main causes of apical resorption. The growing demand for orthodontic treatment methods that require minimal compliance and maximal anchorage control, particularly by adults, has led to the expansion of implant technology. Miniscrews have been introduced as temporary anchorage devices for various purposes: canine retraction, anterior retraction, en-masse anterior retraction, molar uprighting, distalization, and protraction.

## Factors affecting root resorption

### Biologic factors

#### Genetics

Several studies strongly suggest a genetic component for shortened roots. Although no definite genetic conclusion was found, autosomal dominant, autosomal recessive, and polygenic modes of inheritance are possible.

#### Systemic Factors

According to Becks, endocrine problems including hypothyroidism, hypopituitarism, hyperpituitarism, and other diseases are related to root resorption. This hypothesis, based on basal metabolic rates, has not been examined by updated blood analyses. hyperparathyroidism, hypophosphatemia, and Paget disease have been linked to root resorption in a few anecdotal case reports.

#### Nutrition

Marshall TM advocated that malnutrition can cause root resorption. Becks demonstrated root resorption in animals deprived of dietary calcium and vitamin D. It was later suggested that nutritional imbalance is not a major factor in root resorption during orthodontic treatment.

**Chronologic age**

All tissues involved in the root resorption process show changes with age. The periodontal membrane becomes less vascular, aplastic, and narrow, the bone more dense, avascular, and aplastic, and the cementum wider. These changes are reflected by a higher susceptibility to root resorption seen in adults.

**Gender**

Treated and untreated random samples showed no correlation between gender and root resorption. According to other studies, females are more susceptible to root resorption. The idiopathic root resorption ratio was 3.7:1 females to males, respectively. Apical root material loss was greater in treated females (0.73 mm) compared with treated males (0.67 mm).

**Habits**

Nail-biting, tongue thrust associated with open bite, and increased tongue pressure have been statistically related to increased root resorption.

**Tooth structure**

Deviating root form is more susceptible to post orthodontic root resorption. Convergent apical root canal is considered to be an indicative of high root resorption potential. The degree of root resorption in teeth with blunt- or pipette-shaped roots was significantly higher than in teeth with normal root form.

**Previously traumatized teeth**

Traumatized teeth can exhibit external root resorption without orthodontic treatment. Orthodontically moved traumatized teeth with previous root resorption are more sensitive to further loss of root material.

**Endodontically treated teeth**

A higher frequency and severity of root resorption of endodontically treated teeth during orthodontic treatment was reported. However, it has been suggested that endodontically treated teeth are more resistant to root resorption because of an increased dentin hardness and density.

**Alveolar bone density**

Controversial reports on root resorption and alveolar bone density appear in the literature. Becks and Lager related increased root resorption to bone architecture resulting from hormonal and nutritional imbalance during growth. According to Reitan, a strong continuous force on less dense alveolar bone causes the same root resorption as a mild continuous force on highly dense alveolar bone. Lamellar bone is more difficult to resorb with orthodontic pressure than bundle bone.

**Mechanical factors****Appliances**

It is often stated that the degree of root damage is a function of the appliance used.

**Fixed versus removable:**

Only one study compared root resorption resulting from fixed and removable appliances, concluding that the use of fixed appliances is more detrimental to the roots. Ketcham claimed that normal function is disturbed by the splinting effect of orthodontic fixed appliances over a long period that can cause root resorption. Stuteville, on the other hand, suggested that the jiggling forces caused by removable appliances are more harmful to the roots.

**Begg versus edgewise**

It is often stated that the light wire Begg technique causes less root resorption than edgewise, although maxillary incisor root resorption during the Begg third stage has been documented. Malmgren *et al.* suggested that there is no difference between these techniques, but found that the frequency of root resorption was significantly higher (48%) in traumatized maxillary incisors when intruded by the Begg technique compared with edgewise technique (43%).

**Magnets**

It is suggested that the increase in force as space closes with time (attraction) can stimulate a more physiologic tissue response, and thus decrease the potential for root resorption.

**Miniscrew**

Miniscrew anchorage allows for greater maxillary en-masse anterior retraction in severe Class II cases. But the time needed for this greater retraction with miniscrew anchorage would be longer and dispose the patient to more apical root resorption.

**Intermaxillary Elastics**

Linge and Linge found significantly more root resorption on the side where elastics were used and suggested that jiggling forces the result of function combined with elastics are responsible for the incisors root resorption. It was reported that Class III elastics used for anchorage preparation increased mandibular first molar distal root resorption.

**Extraction versus nonextraction**

McFadden and Vonder he found no difference in the extent of root resorption in patients treated with or without extractions.

**Orthodontic movement type**

It seems that there is no safe tooth movement. Intrusion is probably the most detrimental to the roots involved, but tipping, torque, bodily movement, and palatal expansion can also be implicated.

## Orthodontic force

### Degree of force

Harry and Sims found the distribution of resorbed lacunae was directly related to the amount of stress on the root surface and the rate of lacunae development was more rapid with increasingly applied forces. They concluded that higher stress causes more root resorption. According to Schwartz, applied force exceeding the optimal level of 20 to 26 gm/cm<sup>2</sup> causes periodontal ischemia, which can lead to root resorption.

### Continuous versus intermittent forces

The pause in treatment with intermittent forces allows the resorbed cementum to heal and prevents further resorption.

### Combined biologic and mechanical factors

#### Treatment duration

Most studies report that the severity of root resorption is directly related to treatment duration Levander and Malmgren found that 34% of examined teeth showed root resorption after 6 to 9 months of treatment, whereas at the end of active treatment, lasting 19 months, root resorption increased to 56%.

Root resorption detected radiographically during orthodontic treatment. Minor resorption or an irregular root contour seen after 6 to 9 months indicates an increased risk of further root resorption. No severe resorption was detected at the end of treatment in teeth without resorption after 6 to 9 months

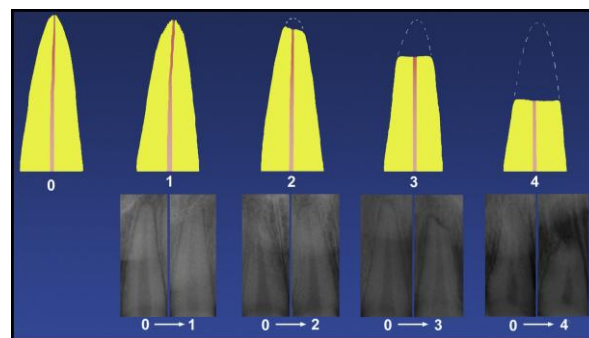
### Relapse

Reitan claims that forces of relapse are not strong enough to cause root resorption. However, Ten Hove and Mulie believe that the teeth are prone to additional root loss during relapse as a result of light muscles forces.

### Clinical diagnostic aids to root resorption

Radiographs are commonly used as a diagnostic aid for root resorption. Radiographic detection of apical root shortening requires a certain degree of resorption. Tooth movement makes it more difficult to assess the exact amount of root loss especially when the tooth is torqued or tipped. Commonly used radiographs are ineffective in assessing buccal and lingual root resorption. Several radiographic techniques used include periapical bisecting angle, periapical paralleling, orthopantomogram, cephalogram. The periapical technique provides less distortion and superimposition errors compared with the orthopantomogram or the lateral head film. The true cephalometric lateral skull can be used to assess incisor root length, but not for detailed diagnosis of external root resorption. In order to correctly assess the degree of external root resorption care should be taken to employ the radiographic technique that ensure geometrically accurate images. In some instance it may be necessary to take more than one radiograph.

## Scoring System



### Score system of Levander and Malmgren

Grade 0: absence of root resorption;

Grade 1: mild resorption, root with its normal length and only an irregular contour

Grade 2: moderate resorption, small area of root loss with the apex exhibiting an almost straight contour

Grade 3: accentuated resorption, loss of almost one third of root length;

Grade 4: extreme resorption, loss of more than one third of the root length.

## CONCLUSION

Apical root resorption is a most common sequale of orthodontic treatment. It usually associated with many biologic and mechanical factors which increases the vulneribility of root resorption. A proper maintainance of these factors will reduces the root resorption.

Miniscrew anchorage allows for greater retraction. But the time needed for this greater retraction with miniscrew anchorage would be longer and dispose the patient to more apical root resorption.

## REFERENCES

- Barros, S. E., Janson, G., Chiqueto, K., Baldo, V. O., & Baldo, T. O. (2017). Root resorption of maxillary incisors retracted with and without skeletal anchorage. *American Journal of Orthodontics and Dentofacial Orthopedics*, 151(2), 397-406.
- Brezniak, N., & Wasserstein, A. (1993). Root resorption after orthodontic treatment: Part 2. Literature review. *American Journal of Orthodontics and Dentofacial Orthopedics*, 103(2), 138-146.
- Janson, G. R., de Luca Canto, G., Martins, D. R., Henriques, J. F. C., & de Freitas, M. R. (2000). A radiographic comparison of apical root resorption after orthodontic treatment with 3 different fixed appliance techniques. *American journal of orthodontics and dentofacial orthopedics*, 118(3), 262-273.
- de Freitas, M. R., Beltrão, R. T. S., Janson, G., Henriques, J. F. C., & Chiqueto, K. (2007). Evaluation of root resorption after open bite

treatment with and without extractions. *American Journal of Orthodontics and Dentofacial Orthopedics*, 132(2), 143-e15.

- Liou, E. J., & Chang, P. M. (2010). Apical root resorption in orthodontic patients with en-masse maxillary anterior retraction and intrusion with miniscrews. *American Journal of Orthodontics and Dentofacial Orthopedics*, 137(2), 207-212.
- Wang, Q., Chen, W., Smales, R. J., Peng, H., Hu, X., & Yin, L. (2012). Apical root resorption in maxillary incisors when employing micro-implant and J-hook headgear anchorage: A 4-month radiographic study. *Journal of Huazhong University of Science and Technology [Medical Sciences]*, 32(5), 767-773.
- Iglesias-Linares, A., Sonnenberg, B., Solano, B., Yañez-Vico, R. M., Solano, E., Lindauer, S. J., & Flores-Mir, C. (2017). Orthodontically induced external apical root resorption in patients treated with fixed appliances vs removable aligners. *The Angle Orthodontist*, 87(1), 3-10.
- Remington, D. N., Joondeph, D. R., Årtun, J., Riedel, R. A., & Chapko, M. K. (1989). Long-term evaluation of root resorption occurring during orthodontic treatment. *American Journal of Orthodontics and Dentofacial Orthopedics*, 96(1), 43-46.
- Beck, B. W., & Harris, E. F. (1994). Apical root resorption in orthodontically treated subjects: analysis of edgewise and light wire mechanics. *American Journal of Orthodontics and Dentofacial Orthopedics*, 105(4), 350-361.
- Brin, I., Tulloch, J. C., Koroluk, L., & Philips, C. (2003). External apical root resorption in Class II malocclusion: a retrospective review of 1-versus 2-phase treatment. *American Journal of Orthodontics and Dentofacial Orthopedics*, 124(2), 151-156.
- Blake, M., Woodside, D. G., & Pharoah, M. J. (1995). A radiographic comparison of apical root resorption after orthodontic treatment with the edgewise and Speed appliances. *American Journal of Orthodontics and Dentofacial Orthopedics*, 108(1), 76-84.
- Segal, G. R., Schiffman, P. H., & Tuncay, O. C. (2004). Meta analysis of the treatment-related factors of external apical root resorption. *Orthodontics & craniofacial research*, 7(2), 71-78.
- McNab, S., Battistutta, D., Taverne, A., & Symons, A. L. (2000). External apical root resorption following orthodontic treatment. *The Angle Orthodontist*, 70(3), 227-232.
- Yao, C. C. J., Lai, E. H. H., Chang, J. Z. C., Chen, I., & Chen, Y. J. (2008). Comparison of treatment outcomes between skeletal anchorage and extraoral anchorage in adults with maxillary dentoalveolar protrusion. *American Journal of Orthodontics and Dentofacial Orthopedics*, 134(5), 615-624.
- Upadhyay, M., Yadav, S., Nagaraj, K., & Patil, S. (2008). Treatment effects of mini-implants for en-masse retraction of anterior teeth in bialveolar dental protrusion patients: a randomized controlled trial. *American Journal of Orthodontics and Dentofacial Orthopedics*, 134(1), 18-29.
- Liou, E. J., & Chang, P. M. (2010). Apical root resorption in orthodontic patients with en-masse maxillary anterior retraction and intrusion with miniscrews. *American Journal of Orthodontics and Dentofacial Orthopedics*, 137(2), 207-212.
- de Freitas, M. R., Beltrão, R. T. S., Janson, G., Henriques, J. F. C., & Chiqueto, K. (2007). Evaluation of root resorption after open bite treatment with and without extractions. *American Journal of Orthodontics and Dentofacial Orthopedics*, 132(2), 143-e15.
- Estelita, S., Janson, G., Chiqueto, K., & Garib, D. (2012). Mini-implant insertion based on tooth crown references: a guide-free technique. *International journal of oral and maxillofacial surgery*, 41(1), 128-135.
- Estelita, S., Janson, G., Chiqueto, K., Janson, M., & de Freitas, M. R. (2009). Predictable drill-free screw positioning with a graduated 3-dimensional radiographic-surgical guide: a preliminary report. *American journal of orthodontics and dentofacial orthopedics*, 136(5), 722-735.
- Leach, H. A., Ireland, A. J., & Whaites, E. J. (2001). Radiographic diagnosis of root resorption in relation to orthodontics. *British dental journal*, 190(1), 16-22.
- Sabarudin, A., & Tiau, Y. J. (2013). Image quality assessment in panoramic dental radiography: a comparative study between conventional and digital systems. *Quantitative imaging in medicine and surgery*, 3(1), 43-48.
- Razali, N. M., & Wah, Y. B. (2011). Power comparisons of shapiro-wilk, kolmogorov-smirnov, lilliefors and anderson-darling tests. *Journal of statistical modeling and analytics*, 2(1), 21-33.
- Smale, I., Årtun, J., Behbehani, F., Doppel, D., van't Hof, M., & Kuijpers-Jagtman, A. M. (2005). Apical root resorption 6 months after initiation of fixed orthodontic appliance therapy. *American Journal of Orthodontics and Dentofacial Orthopedics*, 128(1), 57-67.
- Levander, E., & Malmgren, O. (1988). Evaluation of the risk of root resorption during orthodontic treatment: a study of upper incisors. *The European Journal of Orthodontics*, 10(1), 30-38.
- Levander, E., Malmgren, O., & Stenback, K. (1998). Apical root resorption during orthodontic treatment of patients with multiple aplasia: a study of maxillary incisors. *The European Journal of Orthodontics*, 20(4), 427-434.
- Harris, E. F., & Butler, M. L. (1992). Patterns of incisor root resorption before and after orthodontic correction in cases with anterior open bites. *American Journal of Orthodontics and Dentofacial Orthopedics*, 101(2), 112-119.

- Linge, B. O., & Linge, L. (1983). Apical root resorption in upper anterior teeth. *The European Journal of Orthodontics*, 5(3), 173-183.
- Linge, L., & Linge, B. O. (1991). Patient characteristics and treatment variables associated with apical root resorption during orthodontic treatment. *American Journal of Orthodontics and Dentofacial Orthopedics*, 99(1), 35-43.
- McFadden, W. M., Engstrom, C., Engstrom, H., & Anholm, J. M. (1989). A study of the relationship between incisor intrusion and root shortening. *American Journal of Orthodontics and Dentofacial Orthopedics*, 96(5), 390-396.
- Mirabella, A. D., & Årtun, J. (1995). Risk factors for apical root resorption of maxillary anterior teeth in adult orthodontic patients. *American Journal of Orthodontics and Dentofacial Orthopedics*, 108(1), 48-55.