

## Neurofibromatosis Revealed By Exophthalmos: A Case Report and Literature Review

M. Ranib<sup>1\*</sup>, F. Amenzouy<sup>1</sup>, H. El Mortaji<sup>1</sup>, B. Boutakioute<sup>1</sup>, M. Ouali Idrissi<sup>1</sup>, N. Cherif Idrissi El Ganouni<sup>1</sup>

<sup>1</sup>Department of radiology, ARRAZI hospital, CHU Mohammed VI, Cadi Ayyad University, Marrakech, Morocco

DOI: [10.36347/sjmcr.2021.v09i09.004](https://doi.org/10.36347/sjmcr.2021.v09i09.004)

| Received: 22.07.2021 | Accepted: 27.08.2021 | Published: 03.09.2021

\*Corresponding author: M. Ranib

### Abstract

### Case Report

Neurofibromatosis (NF) is a neurocutaneous disorder, which involves many organs in the body. There are two types: NF-1 and NF-2. Orbital manifestation is a rarity in NF-1, and it involves dysplasia of the sphenoid bone resulting in herniation of the temporal lobe and subarachnoid space into the orbit culminating in exophthalmos. In this presentation, we report the case of 18 years old boy, admitted for exophthalmos dating back to the age of 5 years. we performed a cerebral and oculo-orbital MRI which has objectified a sphenoid agenesis (confirmed by CT scan) associated with a neurofibroma of the external canthus of the right eye, we have also objectified multiple signal abnormalities of cerebral white matter corresponding to FASI (focal areas of signal intensity), a more detailed clinical examination was carried out a posteriori which revealed multiple café-au-lait spots, all of these lesions suggestive of neurofibromatosis with cerebral and spheno-ocular involvement.

**Keywords:** Exophthalmos, neurofibromatosis, imaging, MRI, CT scan.

**Copyright © 2021 The Author(s):** This is an open-access article distributed under the terms of the Creative Commons Attribution **4.0 International License (CC BY-NC 4.0)** which permits unrestricted use, distribution, and reproduction in any medium for non-commercial use provided the original author and source are credited.

## INTRODUCTION

Neurofibromatosis (NF) includes two autosomal dominant diseases: neurofibromatosis type 1 (NF1) or Von Recklinghausen disease and neurofibromatosis type 2 [1]. The NF1 is the most common, with an incidence of approximately one case per 3500 births [2] worldwide. It is a genetic autosomal dominant disease, whereas de novo mutations affect 50% of patients [1]. The mutation of the NF1 genes is located at the pericentromeric region of chromosome 17 [1, 2].

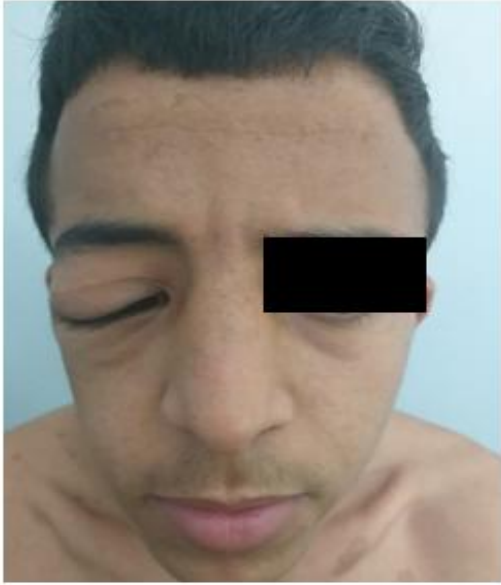Beginning in early childhood, patients with neurofibromatosis type 1 have multiple café-au-lait spots, which are flat patches on the skin that are darker than the surrounding area. These spots increase in size and number, as the individual grows older. Freckles in the underarms and groin typically develop later in childhood [3].

Apart from optic glioma, which can present with ocular symptoms, sphenoid wing dysplasia with

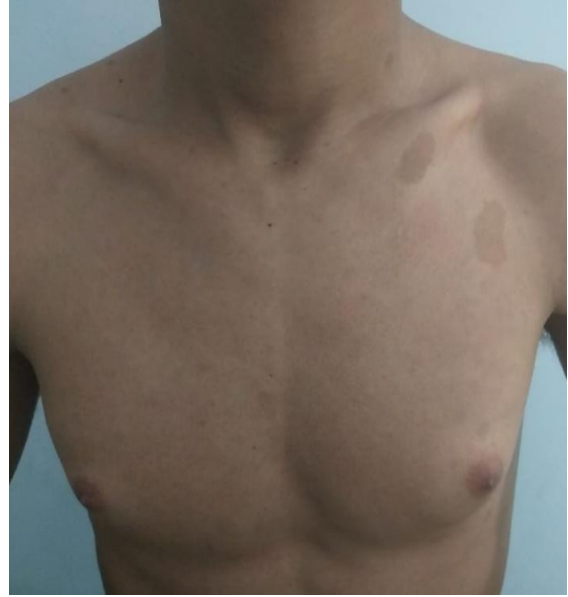herniation of the temporal lobe into the orbit can present with pulsating exophthalmos or enophthalmos [4].

## CASE PRESENTATION

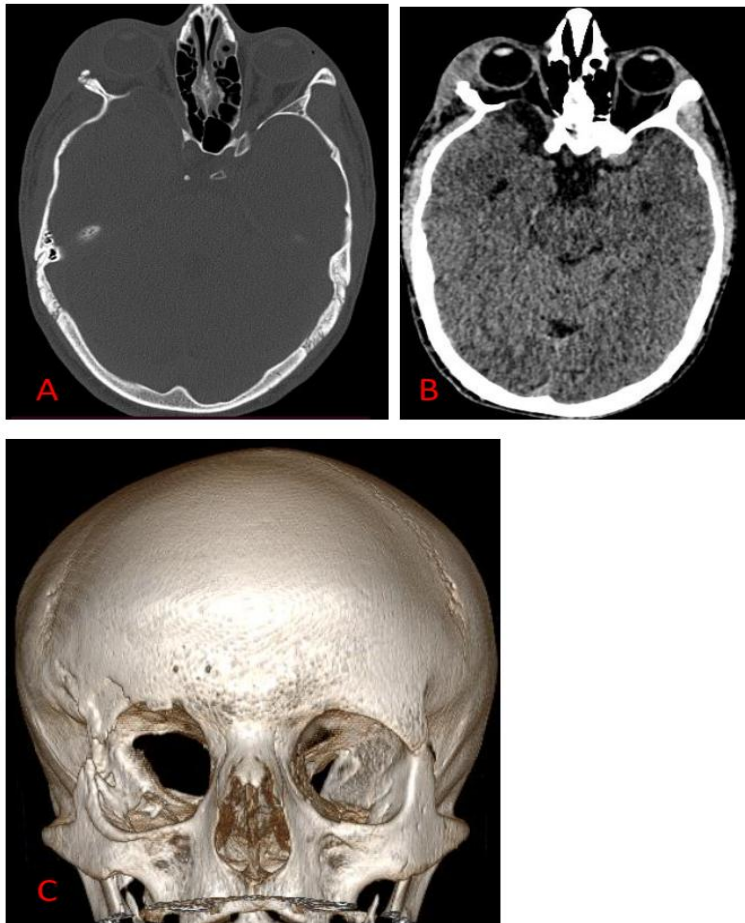
We report the case of 18 years old boy, with no particular pathological history, who presents for a right exophthalmos evolving since the age of 5 years (Fig 1), on clinical examination, there are multiple café-au-lait skin spots (Fig 2), we completed by a cerebral and oculo-orbital MRI which has objectified a sphenoid agenesis with dilation of the subarachnoid spaces (confirmed by CT scan (Fig 3) associated with a nodular lesion of the external canthus of the right eye corresponding to a neurofibroma, these lesions are responsible for a grade I exophthalmos, we have also objectified multiple signal abnormalities of basal ganglia and the white matter infra and supra-tentorial corresponding to FASI (focal areas of signal intensity) (Fig 4), all of these lesions suggestive of neurofibromatosis with cerebral and spheno-ocular involvement.



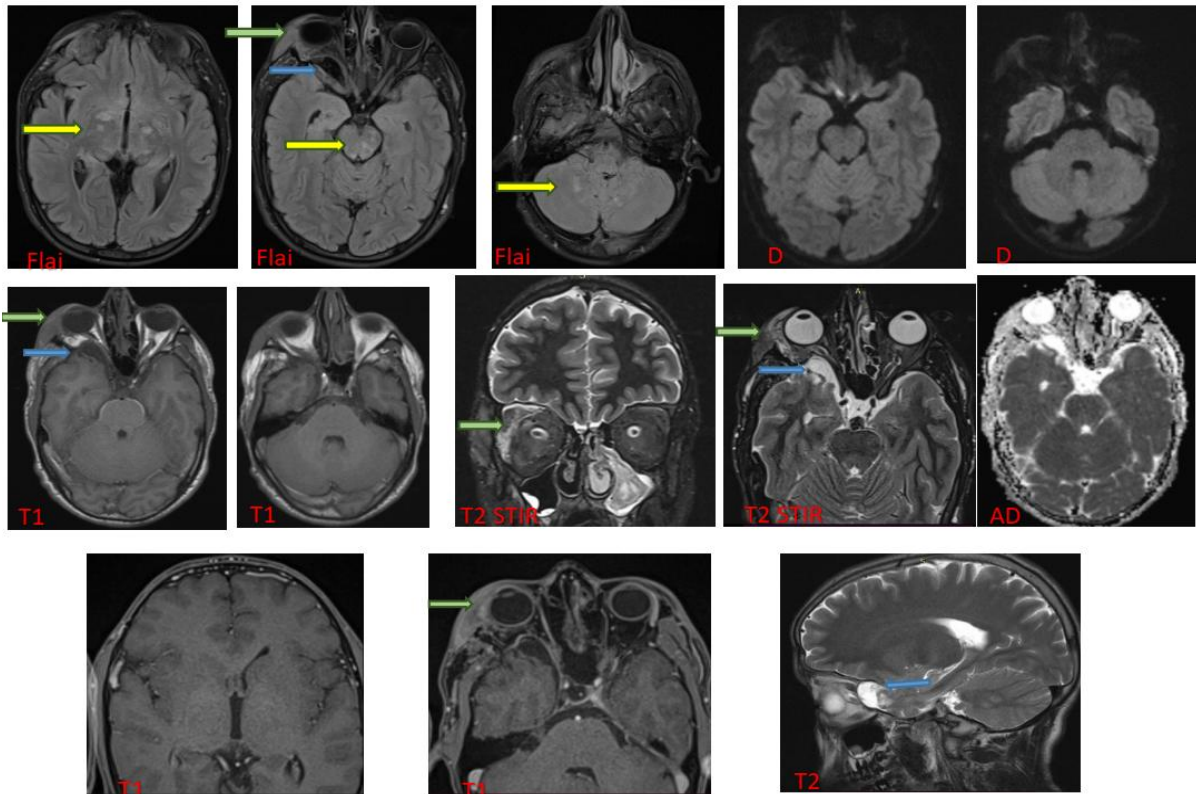
**Fig 1: Exophthalmos of the right eye**



**Fig 2: Café au lait spots**



**Fig 3: Axial CT in bone window (A) and parenchyma window (B) illustrates the hypoplasia of the right sphenoid wing and the intracranial and orbital contents separated only by dura mater. C: Anterior volume rendered 3D CT image illustrates details of the bony defect in the right orbital region**



**Fig 4:** MRI images showing the sphenoid agenesis with dilation of the subarachnoid spaces (blue arrow) associated with a nodular lesion of the external canthus of the right eye corresponding to a neurofibroma (green arrow), these lesions are responsible for a grade I exophthalmos, we have also objectified multiple signal abnormalities of basal ganglia and the white matter infra and supra-tentorial corresponding to FASI (yellow arrow)

## DISCUSSION

Neurofibromatosis type 1 may affect all systems of the human body. It is a hamartomatous disorder that originates in the neural crest and secondarily affects the supporting mesenchyme. The disorder, which is characterized by pigmented cutaneous lesions, manifests itself in various ways. Central nervous system indicators consist of an increased incidence of astrocytomas, meningiomas, schwannomas, and ependymomas. Other features of the disease include bony dysplasias, kyphoscoliosis, sphenoid wing hypoplasia and vascular dysplasia [5].

Sphenoid dysplasia is one of the characteristics of NF-1, occurring in 5-10% of cases. Furthermore, abnormalities of the sphenoid wings are often considered pathognomonic. However, complete dysgenesis of the sphenoid wing is very rare. Its radiological characteristics describe the area of defect in the greater sphenoid wing and enlargement of the middle cranial fossa. Many ophthalmic manifestations may occur in NF-1 patients. Lisch nodules are virtually all pathognomonic; other ophthalmic findings include choroidal hamartomas, plexiform neurofibromas, retinal phakomas and optic nerve gliomas. Exophthalmos and enophthalmos, potential sequelae, are associated with orbital tumors and/or sphenoid wing dysplasia [5, 6].

Intracranial CNS manifestations include characteristic NF1 “spots” and low-grade neoplasms. The NF1 “spots” are regions of signal abnormality involving the basal ganglia, thalami, dentate nuclei, cerebellar peduncles, optic radiations, and brainstem in children and adolescents; they are thought to represent regions of myelin vacuolization. They are hyperintense on T2 sequences and typically iso- to mildly hyperintense on T1 images. There should be no mass effect or enhancement, as enhancement or significant mass effect suggests development of a low-grade glioma. The lesions may wax and wane for the first decade of life or so and then regress. They are uncommon after the second decade of life [7].

Imaging may suggest the diagnosis of NF1 in the presence of characteristic lesions like in our case. It is mainly involved in the detection and monitoring of complications of the disease.

The management of NF-1 is a multidisciplinary approach involving the clinical geneticist, radiologist, neurologist and surgeon. The neurofibromas are surgically removed, but complete removal is rarely achieved. The use of drugs such as thalidomide, vinblastine, peginterferon alfa-2b and pirfenidone is being studied [8].

## CONCLUSION

Neurofibromatosis type 1 is the most common of the neurocutaneous syndromes, affecting multiple sites and organ systems. CNS manifestations, multiple tumors, to include gliomas (optic pathway and spinal are the most common) and variants of neurofibromas; bony dysplasia and vascular abnormalities. Understanding the characteristic imaging findings, as well as their clinical significance and expected evolution, is critical in correctly interpreting neuroimaging studies in this patient population, and appropriately guiding management decisions.

## REFERENCES

1. Yonaba, C., Djibo, A., Zougrana, C., Kalmogho, A., Diallo, O., Tapsoba, P., ... & Kam, L. (2015). Neurofibromatosis Type 1 revealed by ophthalmologic complications: A report of one case in Ouagadougou, Burkina Faso. *Open Journal of Pediatrics*, 5(04), 290-295.
2. Wolkenstein, P. (2005). Neurofibromatoses et sclérose tubéreuse de bourneville. *Journal of neuroradiology*, 32(3), 174-179.
3. Yahia, S. A., & Soualili, Z. (2016). Neurofibromatosis type 1 (NF1): case report and review of literature. *Journal of Childhood & Developmental Disorders*, 2(3), 20.
4. Ehigiamusoe, F. O., & Ogbeide, E. (2017). Neurofibromatosis with pulsating exophthalmos. *Port Harcourt Medical Journal*, 11(2), 99.
5. Onbas, O., Aliagaoglu, C., Calikoglu, C., Kantarci, M., Atasoy, M., & Alper, F. (2006). Absence of a sphenoid wing in neurofibromatosis type 1 disease: Imaging with multidetector computed tomography. *Korean journal of radiology*, 7(1), 70-72.
6. Macfarlane, R., Levin, A. V., Weksberg, R., Blaser, S., & Rutka, J. T. (1995). Absence of the greater sphenoid wing in neurofibromatosis type I: congenital or acquired: case report. *Neurosurgery*, 37(1), 129-133.
7. O'Brien, W. T. (2015). Neuroimaging manifestations of NF1-A pictorial review. *J Am Osteopath Coll Radiol*, 4, 16-21.
8. Ehigiamusoe, F. O., & Ogbeide, E. (2017). Neurofibromatosis with pulsating exophthalmos. *Port Harcourt Medical Journal*, 11(2), 99-102.