

## Cosmetic Dentistry Assisted by Laser

Siham Hajjaji<sup>1\*</sup>, Amal Esghir<sup>2</sup>, Hayet Hajjemi<sup>3</sup>, Abdellatif Boughzela<sup>4</sup>

<sup>1</sup>Associate Professor of Dental Medicine, Dental Service Fixed Prosthesis Unit, University Hospital Farhat Hached, Tunisia

<sup>2</sup>Dental resident, Dental Service Fixed Prosthesis Unit, University Hospital Farhat Hached, Tunisia

<sup>3</sup>Professor of Dental Medicine, Dental Service Fixed Prosthesis Unit, University Hospital Farhat Hached, Tunisia

<sup>4</sup>Professor of Dental Medicine, Dental Service Fixed Prosthesis Unit, University Hospital Farhat Hached, Tunisia

DOI: [10.36347/sjds.2021.v08i09.001](https://doi.org/10.36347/sjds.2021.v08i09.001)

| Received: 22.08.2021 | Accepted: 28.09.2021 | Published: 02.10.2021

\*Corresponding author: Dr. Siham Hajjaji

### Abstract

### Review Article

The aesthetic demand of our patients has become more and more pressing. Every day we meet a growing demand for improving the quality of the smile. To meet these expectations, modern dentistry requires the acquisition of new knowledge and technologies. Laser-assisted therapy is gradually establishing itself as one of the new standards of this modern dentistry. Dental lasers today offer real advantages over traditional techniques, allowing them to improve and optimize the final therapeutic result. The contribution of the laser (diode) in cosmetic dental surgery will be detailed per and postoperatively through two clinical cases of frenectomy and gingival depigmentation.

**Keywords:** laser, frenectomy, gingival depigmentation, aesthetics, surgery.

**Copyright © 2021 The Author(s):** This is an open-access article distributed under the terms of the Creative Commons Attribution 4.0 International License (CC BY-NC 4.0) which permits unrestricted use, distribution, and reproduction in any medium for non-commercial use provided the original author and source are credited.

## INTRODUCTION

Nowadays, the laser has become more and more popular in the field of dentistry. It is a technology that aims to facilitate the work of the practitioner and make it much more precise and relevant. It thus gives the image of a modern dentistry more reliable than traditional practices and thus allows a clearer prognosis and comfort for the patient [1,3]. However, our patients have become more and more demanding and sensitive to the smallest details because they know the possibilities that can be offered today by the new cosmetic dentistry.[13]

Indeed, by virtue of its interactions with the soft and hard tissues of the oral cavity, the laser is of growing interest in the field of dental aesthetics. Laser-assisted therapy therefore seems to be gradually establishing itself as one of the new standards of this modern dentistry. In this article, we will focus more particularly on the aesthetic applications of lasers in dental surgery.

### LASERS USED IN DENTAL SURGERY

According to their applications, lasers can be classified into two groups:

- Hot lasers for surgical use: CO2 laser, Erbium laser, Nd: YAG laser, Argon laser

- Cold lasers or soft lasers for gentle therapeutic applications: The Helium-Neon laser, The diode laser (semiconductor lasers).[17,5,12]

In this article, we deal with two clinical cases which illustrate the aesthetic applications of the diode laser in dental surgery.

### The diode laser (semiconductor lasers)

It is very effective for soft tissue providing excellent incision, hemostasis and coagulation. The diode laser has similar characteristics to the Nd: Yag laser. Both offer high penetrability in biological tissues (fig. 1).[17]

### Aesthetic applications of lasers in dental surgery

#### Clinical case n° 1: Frenectomy

Frenectomy consists of the ablation of an iatrogenic brake in order to reduce the traction it exerts on the gingival mucosa, free the inter-incisor space and improve aesthetics, especially in the presence of a high smile line.[19]

In our case, we will focus on maxillary labial freerectomy. There are two main procedures for its realization: the simple horizontal incision and the V or

rhomboid incision with or without papillary recall. For this case, we will use the diode laser (fig. 2).[10,16]

The intervention begins with traction on the upper lip showing the brake (fig. 3) which is put in tension, the tip of the laser fiber is then directed according to the outline of the incision which will be in our case an incision in V (fig. 4). We then start by making an incision in the axis of the brake (fig. 5), which will be followed by a transverse incision until a rhomboid shape is obtained. The laser energy is delivered by pulse (20 pulses per second), the practitioner works in contact mode while keeping the laser fiber always moving along the line of the incision, which is essential to avoid carbonization of the tissues and deep damage. In fact, the duration of tissue exposure is associated with the increase in temperature in situ. The lip must be kept in tension throughout the procedure in order to maintain optimal cutting precision.

Keep in mind that the ablation time depends on the composition of the target tissue, therefore the frenum cord section may be longer than the rest of the incision. We must not shred the fabrics with the fiber; we must let the laser energy make the cut [12,18]. Hemostasis is controlled throughout the operation thanks to the coagulation effect of the diode laser (fig. 6). Sutures are not necessary and the wound will heal by second intention (fig 7.a and 7.b).

Laser frenectomy has many advantages over conventional scalpel surgery:[3,6]

- Topical anesthesia which allows increased acceptance in patients, especially children
- Immediate hemostasis and increased intraoperative visibility
- No sutures
- Absence of pain per or post-operative without prescription analgesic
- Reduced edema
- Sterilization of the site : bactericidal effect of the laser used
- Fast healing

### Clinical case n ° 2: Depigmentation / Frenectomy

Gingival hyperpigmentation due to melanin is a major aesthetic damage, especially in patients with a gum smile (fig. 8). This staining due to melanin varies from light brown to black and depends on the amount and distribution of melanin in the tissues[9]. In our case, the patient consulted with the “blackish gum” as the main complaint (fig.9). Intraoral examination revealed general blackish pigmentation of the gum tissue, but the gum was healthy and completely free from inflammation. A low insertion of the maxillary labial frenulum was noted. A laser depigmentation procedure was planned, followed by a maxillary labial frenectomy using the same diode laser. The patient had not previously received any topical or local anesthesia.

The melanin-pigmented gingiva was rejected by vaporization with the diode laser. The procedure was performed on all pigmented areas. The remnants of the resected tissue were removed using sterile gauze moistened with saline solution. This procedure was repeated until the desired depth of tissue removal was reached. The labial frenectomy was performed identically to the first case (fig. 10). No periodontal dressing or stitches are necessary, and the wound will heal from the 2nd intention (fig.11.a and 11.b). Analgesic and 0.2% Chlorhexidine mouthwashes have been prescribed.

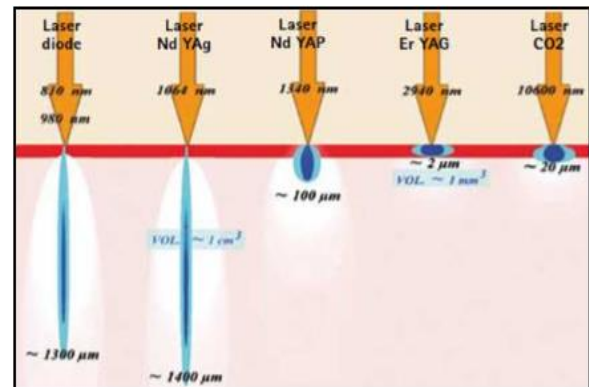


Fig-1: The penetration of energy from different laser radiations into soft tissues[3]

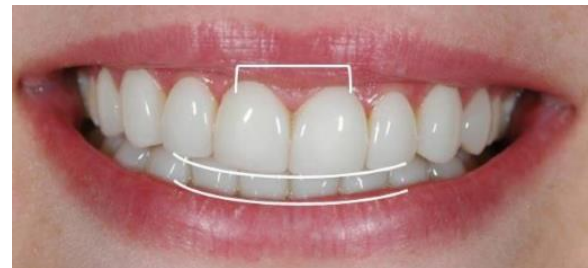

Fig-2: Harmonious and aesthetic smile (harmonious relationship between teeth / gum / lips)[3]

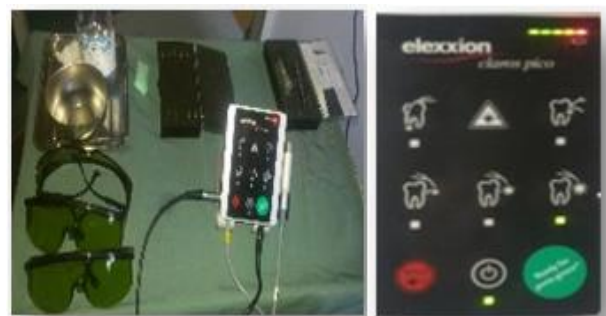
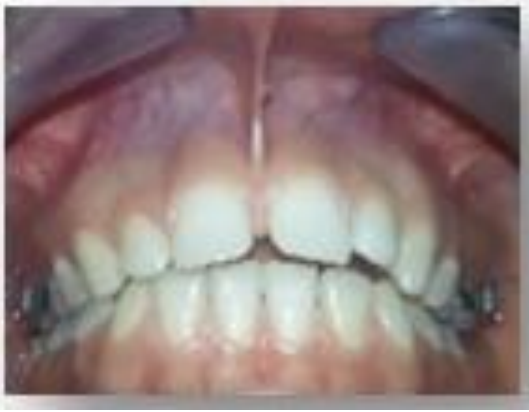
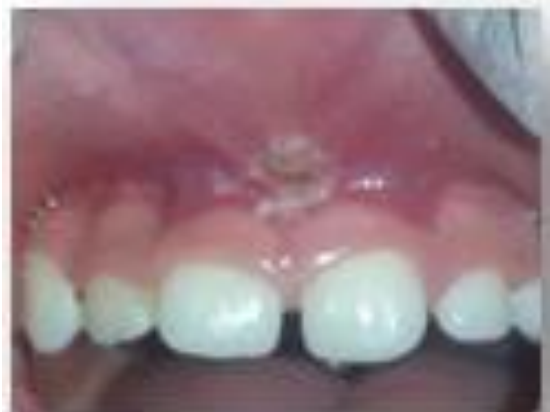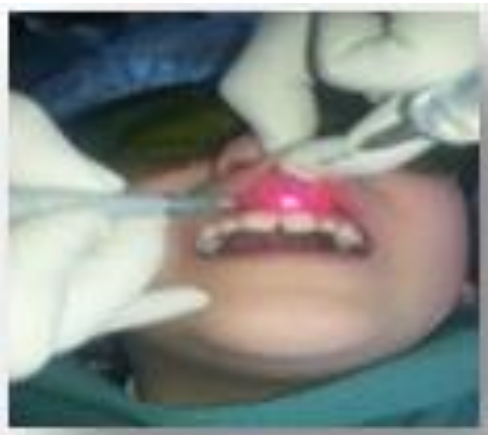Fig-3: Preparation of the surgical table for the diode laser



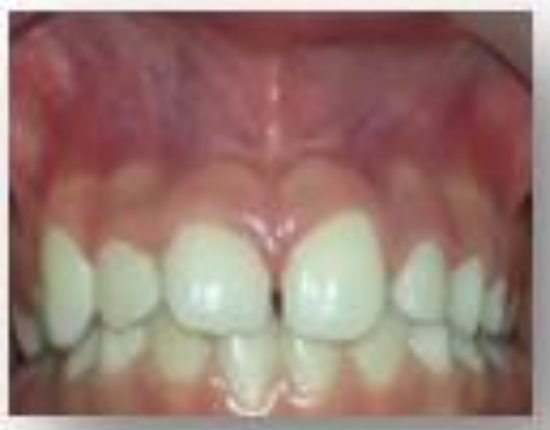**Fig-4: Traction of the upper lip to highlight the labial frenulum insertions**



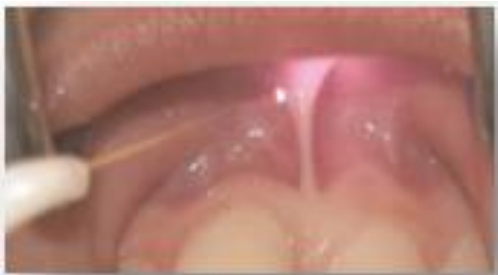**Fig-8.a: healing after 10 days**



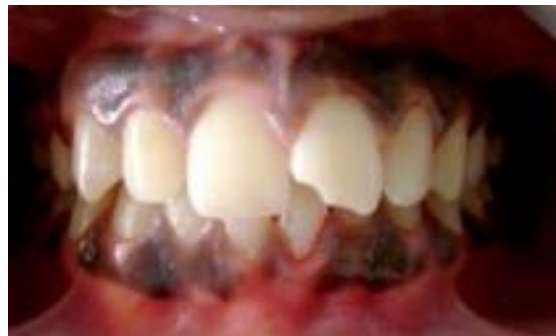**Fig-5: laser fiber in action**



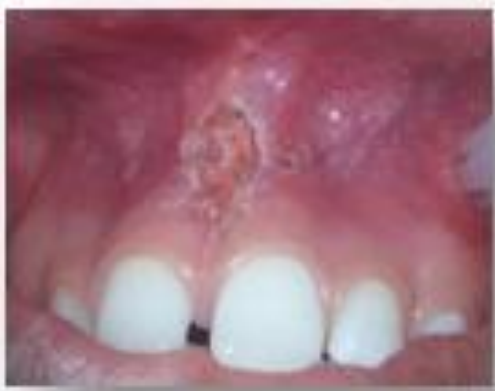**Fig-8.b: healing at 1 month**



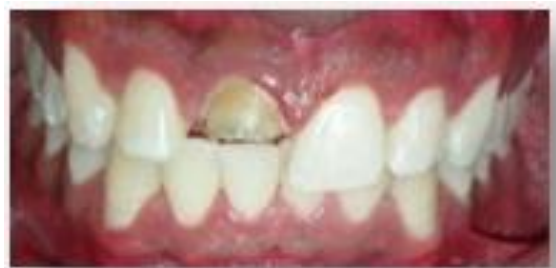**Fig-6: Incision along the axis of the brake**



**Fig-9: Gingival hyperpigmentation characterized by a general blackish coloration of the gum**

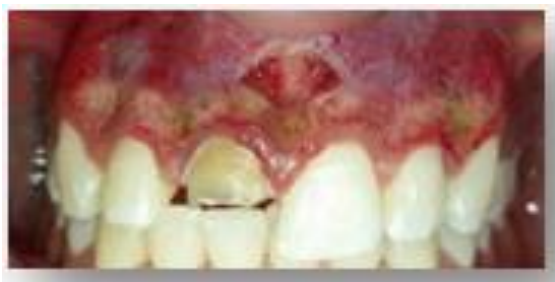

**Fig-7: Immediate postoperative situation: note the excellent hemostasis**

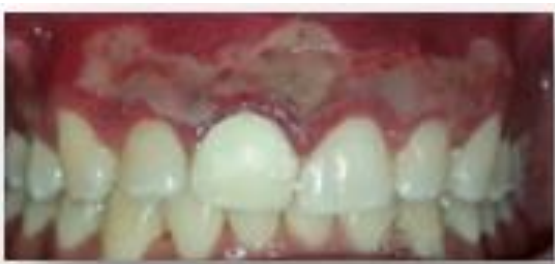

**Fig-10: Gingival hyperpigmentation due to melanin**

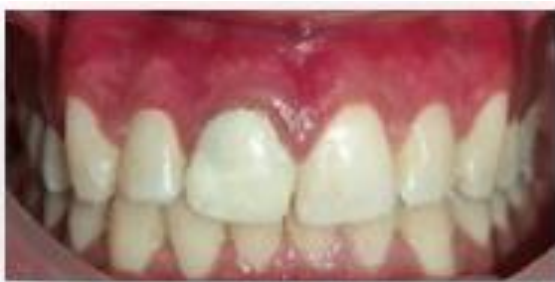



**Fig-11: Depigmentation and freepigmentation with diode laser / immediate postoperative situation**



**Fig-12.a: healing at one week**



**Fig-12.b: result at one month: aesthetic satisfaction**

#### Here again, the laser has certain advantages

It is considered the least painful technique thanks to the formation of a protein clot on the surface of the wound, which serves as a biological dressing and seals the endings of the sensory nerves.[15]

The effects of laser photo-modulation help in stimulation of fibroblasts, angiogenesis and acceleration of lymphatic flow, which improves tissue repair and regeneration.[13]

It is an excellent hemostatic agent, which significantly improves visibility during the operation. Finally, he presents very little recurrence; in fact, no gingival repigmentation at 6 months of depigmentation by the laser has been observed, and this following the destruction of the epithelial cells of the basal layer by the laser beam[17]. However, you have to be careful with the risks of gingival ulceration and recession, especially in the event of a late periodontium.

#### CONCLUSION

Lasers provide a real benefit for the success of our treatments in cosmetic dentistry but also in all other areas of dentistry (simplification of protocols, operative comfort, biostimulation, reduction of postoperative

effects, etc.).[7] The application of the laser appears to be an effective and safe method, if the choice of laser radiation is suitable for the case, and if the precautions indicated by the manufacturer are observed during its use.[2]

#### REFERENCES

1. Yukna, R. A., Carr, R. L., & Evans, G. H. (2007). Histologic evaluation of an Nd: YAG laser-assisted new attachment procedure in humans. *International Journal of Periodontics & Restorative Dentistry*, 27(6).
2. Williams, T. M., Cobb, C. M., Rapley, J. W., & Killoy, W. J. (1995). Histologic Evaluation of Alveolar Bone Following CO 2 Laser Removal of Connective Tissue From Periodontal Defects. *International Journal of Periodontics & Restorative Dentistry*, 15(5).
3. White, J. M., Goodis, H. E., & Rose, C. L. (1991). Use of the pulsed Nd: YAG laser for intraoral soft tissue surgery. *Lasers in surgery and medicine*, 11(5), 455-461.
4. White, J. M., Chaudhry, S. I., Kudler, J. J., Sekandari, N., Schoelch, M. L., & Silverman Jr, S. (1998). Nd: YAG and CO2 laser therapy of oral mucosal lesions. *Journal of clinical laser medicine & surgery*, 16(6), 299-304.
5. Watanabe, I., & Topham, D. S. (2006). Laser welding of cast titanium and dental alloys using argon shielding. *Journal of Prosthodontics: Implant, Esthetic and Reconstructive Dentistry*, 15(2), 102-107.
6. Tomasi, C., Schander, K., Dahlén, G., & Wennström, J. L. (2006). Short-term clinical and microbiologic effects of pocket debridement with an Er: YAG laser during periodontal maintenance. *Journal of periodontology*, 77(1), 111-118.
7. Taylor, J. C., Hondrum, S. O., Prasad, A., & Brodersend, C. A. (1998). Effects of joint configuration for the arc welding of cast Ti-6Al-4V alloy rods in argon. *The Journal of prosthetic dentistry*, 79(3), 291-297.
8. Shimizu, N., Yamaguchi, M., Goseki, T., Shibata, Y., Takiguchi, H., Iwasawa, T., & Abiko, Y. (1995). Inhibition of prostaglandin E2 and interleukin 1-β production by low-power laser irradiation in stretched human periodontal ligament cells. *Journal of Dental Research*, 74(7), 1382-1388.
9. Smith, D. L., Burnett, A. P., & Gordon jr, T. E. (1972). Laser welding of gold alloys. *Journal of dental research*, 51(1), 161-167.
10. Spitz, S. D. (2008). Lasers in prosthodontics: clinical realities of a dental laser in a prosthodontic practice. *Alpha Omegan*, 4(101), 188-194.
11. Sasaki, K. M., Aoki, A., Ichinose, S., & Ishikawa, I. (2002). Ultrastructural analysis of bone tissue irradiated by Er: YAG laser. *Lasers in Surgery and Medicine: The Official Journal of the American*

- Society for Laser Medicine and Surgery*, 31(5), 322-332.
12. Schwarz, F., Aoki, A., Becker, J., & Sculean, A. (2008). Laser application in non-surgical periodontal therapy: a systematic review. *Journal of clinical periodontology*, 35, 29-44.
  13. Schwarz, F., Olivier, W., Hertel, M., Sager, M., Chaker, A., & Becker, J. (2007). Influence of implant bed preparation using an Er: YAG laser on the osseointegration of titanium implants: a histomorphometrical study in dogs. *Journal of oral rehabilitation*, 34(4), 273-281.
  14. Romanos, G. E., Everts, H., & Nentwig, G. H. (2000). Effects of diode and Nd: YAG laser irradiation on titanium discs: a scanning electron microscope examination. *Journal of periodontology*, 71(5), 810-815.
  15. Romanos, G. E. (1994). Clinical applications of the Nd: YAG laser in oral soft tissue surgery and periodontology. *Journal of clinical laser medicine & surgery*, 12(2), 103-108.
  16. Romanos, G., Crespi, R., Barone, A., & Covani, U. (2006). Osteoblast attachment on titanium disks after laser irradiation. *International Journal of Oral & Maxillofacial Implants*, 21(2).
  17. Romanos, G., & Nentwig, G. H. (1999). Diode laser (980 nm) in oral and maxillofacial surgical procedures: clinical observations based on clinical applications. *Journal of clinical laser medicine & surgery*, 17(5), 193-197.
  18. Pick, R. M., & Colvard, M. D. (1993). Current status of lasers in soft tissue dental surgery. *Journal of periodontology*, 64(7), 589-602.
  19. Ozawa, Y., Shimizu, N., Kariya, G., & Abiko, Y. (1998). Low-energy laser irradiation stimulates bone nodule formation at early stages of cell culture in rat calvarial cells. *Bone*, 22(4), 347-354.
  20. Parker, S. (2003). The Use of the Nd: YAG Dental Laser as an Adjunct to Aesthetic Restorative Treatment. *Dentistry today*, 22(12), 60-63.
  21. Patil, U. (2008). Overview of lasers. *Indian Journal of Plastic Surgery*, 41(S 01), 101-113.