

Esthetic Management of a Huge Labiomenal Lipoma: A Case Report

Sarra Azzez^{1*}, Chokri Abdellatif¹, Rym Hadhri², Sameh Sioud¹, Hajer Hentati¹, Jamil Selmi¹

¹Department of Oral medicine and oral surgery, University Dental Clinic of Monastir, University of Monastir, Tunisia

²Cytology and pathological anatomy Department, Fattouma Bourguiba Hospital (Monastir), University of Monastir, Tunisia

DOI: [10.36347/sjmcr.2021.v09i10.007](https://doi.org/10.36347/sjmcr.2021.v09i10.007)

| Received: 20.08.2021 | Accepted: 28.09.2021 | Published: 05.10.2021

*Corresponding author: Sarra Azzez

Abstract

Case Report

Lipomas are benign soft tissue neoplasm. Despite they are the most common tumours of mesenchymal nature in human body, they are unusual in oral and maxillofacial regions. The oral cavity occurrence rate ranges from 1% to 4%. The etiology remains unclear and different theories have been proposed to explain the pathogenesis of this tumour. Clinically, lipomas exhibit painless, well-circumscribed nodular swelling with yellow color or covered by normal mucosa. The case report is about a large and deep-seated lipoma occurring in labiomenal region in a 60-year-old-male patient causing esthetic impediment and speech problem. The lesion was removed through intra-oral approach for esthetic reason. No recurrence was reported after 3 months follow-up.

Keywords: Lipoma, soft tissue tumour, surgery, esthetic management.

Copyright © 2021 The Author(s): This is an open-access article distributed under the terms of the Creative Commons Attribution 4.0 International License (CC BY-NC 4.0) which permits unrestricted use, distribution, and reproduction in any medium for non-commercial use provided the original author and source are credited.

INTRODUCTION

Lipomas are common mesenchymal benign tumours that occur in any region of the human body containing fat. They represent 15% to 20% of all benign neoplasm in head and neck region. However, the occurrence in the oral cavity is rare with 1% to 4% incidence of all benign tumours [1, 2].

They are composed of mature adipocytes usually surrounded by a thin fibrous capsule. Lipoma are located more often in the buccal mucosa followed by the tongue, floor of the mouth, lips, palate and gingiva. The major salivary glands (especially the parotid gland) can be also affected. Clinically, oral lipoma presents as well-circumscribed, asymptomatic, slow-growing, painless and deep-seated nodule covered by normal mucosa. The tumour growing may cause discomfort, speech and mastication difficulties depending on their location which make the patient consult [3, 4].

Histologically, lipomas can be divided into multiple subtypes. The simple lipoma is the most reported in the literature.

Although mechanical trauma, endocrine disorders, obesity, hypercholesterolemia, radiation, and influences of chromosomal abnormalities are reported,

the etiology and pathogenesis of lipomas remain uncertain [5, 6].

The aim of this article is to report a case of a huge labiomenal lipoma near to mental nerve and managed by intraoral excision.

CASE REPORT

A 60-year-old male patient was referred to the department of oral medicine and oral surgery of Monastir- Tunisia dental clinic with a chief complaint of chin swelling localized in the left labiomenal region and causing difficulties when talking and chewing since the last year. The patient reported that the swelling was gradually increasing in size without associated paraesthesia or ulceration. The medical anamnesis revealed that he had diabetes treated with insulin without any other diseases or medication. He had no history of smoking or alcohol consumption.

The extra-oral examination revealed an asymmetry caused by a non-tender, painless mass in the left anterior region of the mandible (chin region) (Figure 1). Intra-orally, the patient was totally edentulous. The swelling extended from muco-gingival junction to buccal mucosa and measured 4 cm × 3 cm. It was covered by normal mucosa with clear margins (Figure 2). An echography was requested. It had revealed a well-demarcated soft tissue fatty in nature suggestive of lipoma.

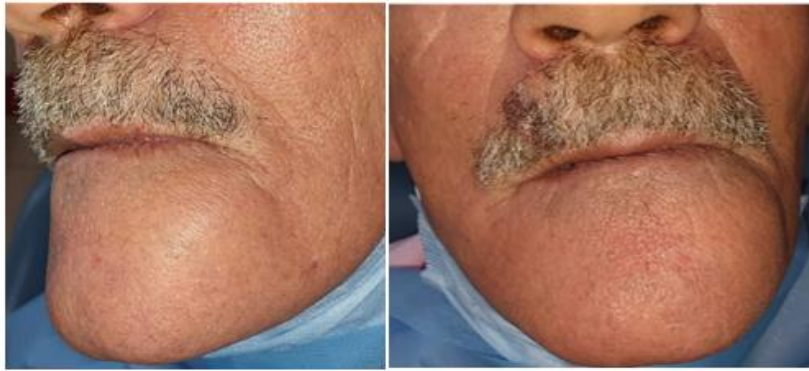


Figure 1: Extraoral views showing left labiomental swelling

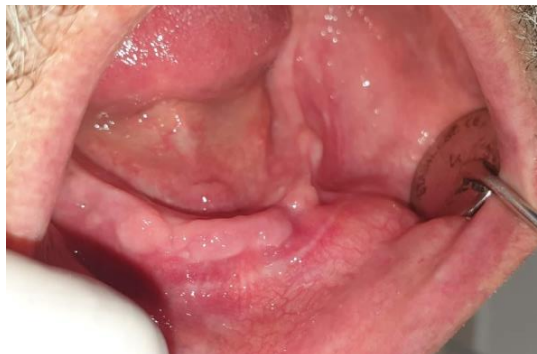

Figure 2: Intraoral examination showing a swelling in the left anterior mandibular site

The patient was informed about the surgical decision and procedure and a written consent was given. The mass was surgically excised under local anesthesia. As it was near to the mental foramen, a precise and horizontal incision about 2,5 cm was performed with surgical scalped blade No.15c. The lesion was totally excised using the blunt dissection

technique. It was encapsulated, soft, well-defined with yellowish color and measured 3 cm ×2cm in size. The surgical incision was sutured with 4.0 vicryl resorbable suture (Figure 3).

The excised tissue was sent for histological examination. The sutures were removed after 10 days.

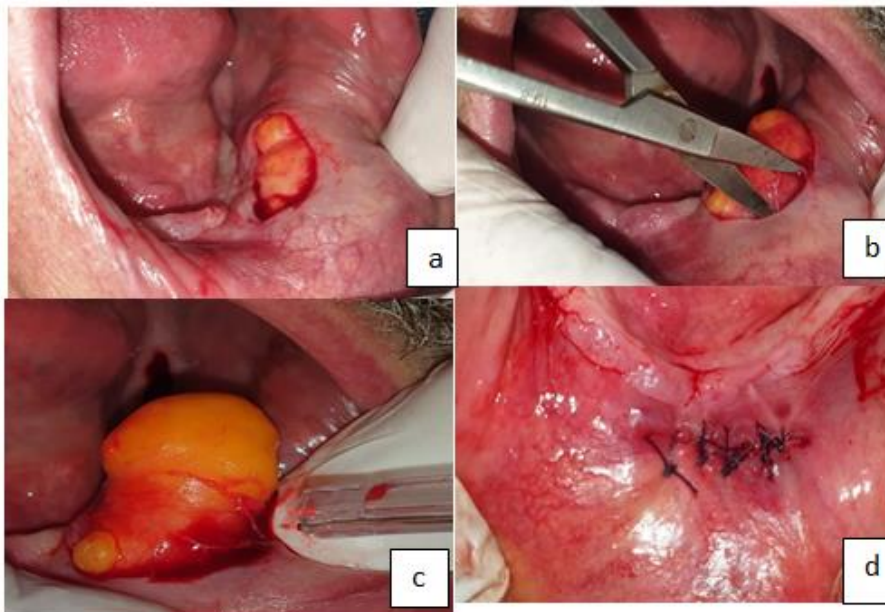


Figure 3: Surgical excision: (a) Vertical surgical incision, (b) Peripheral blunt dissection, (c) Hand pressure used to push the lesion outside, (d) Surgical incision sutured

The histopathologic examination showed lobules of mature adipocytes without cellular atypia and surrounded by thin fibrous connective tissue septa compatible with lipoma. Muscles fibers were also

surrounding some parts of the lesion (Figure 4). Based on these findings, the diagnosis of simple lipoma was made.

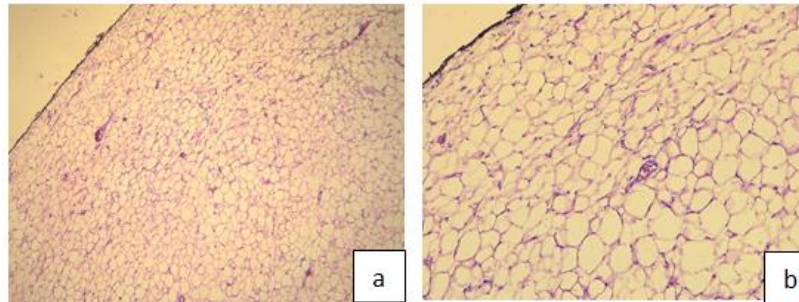


Figure 4: Lipoma composed of lobules of mature adipocytes (a: Hematoxylin Eosin X 40, b: Hematoxylin Eosin X 100)

The postoperative healing was uneventful. No paresthesia was described. There was no recurrence at 3 months follow-up (Figure 5).

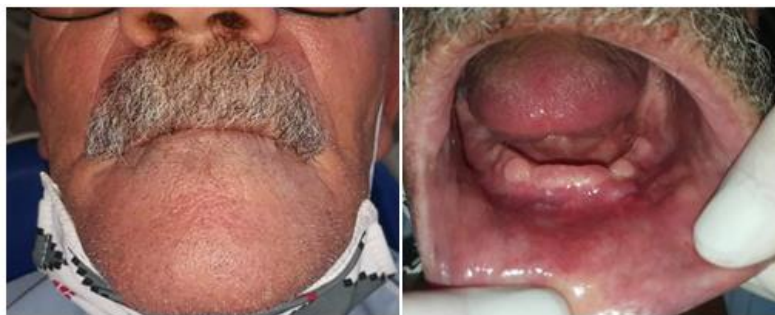

Figure 5: A follow-up after 3 months

DISCUSSION

Lipomas are a benign mesenchymal neoplasm of mature adipose tissue seen most commonly in the head and neck region [4, 5]. The oral lipoma is relatively uncommon. It was described for the first time by Roux in 1948 as “yellow epulis” [6]. In a study conducted by Furlong *et al.*, only 125 oral lipomas over the period of 20 years were reported [7]. Lipomas can affect patients of all ages and gender even though some studies reported male or female predilection and it is more likely to affect the fourth and fifth decade of life [8, 9]. In a review done by Freitas *et al.*, based on 26 cases of the Brazilian population, the mean age of occurrence was 54.6 years [10]. The present case had involved a male patient with age of 60 years.

Till date, the etiology and pathogenesis of lipomas remain unclear. Many factors were implicated such as, endocrine problems, mechanical trauma, obesity, hypercholesterolemia, chromosomal abnormalities, diabetes and radiation [5, 6, 10]. However, in this paper, the patient did not have any history of obesity or trauma but he had diabetes. This is very important to consider a possible recurrence after surgical treatment. In fact, lipoma have recently been correlated with diabetes. This relationship was discussed by several authors in the literature. The

mechanism reported suggested that diabetes patients are exposed to DNA mitochondrial mutations which may cause a perturbation in the maturation process of adipocytes and a local growth of adipose tissue will occur. Thus, when a diabetes patient complains of an asymptomatic gingival swelling in the intraoral area, lipoma should be prominent in the differential diagnosis [11].

The clinic characteristics may depend on the tumour location. But they present usually as slow-growing, painless and mobile nodule covered by normal mucosa. The yellow color appearing through the overlying thin mucosa facilitate the diagnosis of lipoma but it's not always the case [12]. These characteristics were found in this clinical report. Signs and symptoms such discomfort, speech and mastication impediment, may appear over time depending on the size and location [7, 9].

In the present case, the patient had complaint about discomfort and speech problem. The lipoma had grown over a year according to the patient. The excised tissue in this study measured 3 cm x 2 cm in size, which is relatively large.

Histologically, lipomas consist of mature fat cells divided by connective tissue septa and blood vessels. The adipocytes didn't exhibit any atypia [2]. They are usually circumscribed by a thin fibrous capsule.

Due to the similarities in the histological features between lipoma and other diseases, it is very important to consider tumours such as epidermoid cysts, pleomorphic adenomas, fibromas, thyroglossal duct cysts, mucoepidermoid carcinoma, and lymphoepithelial cysts in the differential diagnosis [7, 10].

According to those microscopical features they can be classified into simple lipoma, fibrolipoma, angiolipoma, spindle cell lipoma, and pleomorphic, myxoid, sialolipoma, and intramuscular lipomas [3]. Among these variants, myxoid lipomas and angiolipomas are rarely found in the oral cavity [14]. Simple lipoma is the most common diagnosis in the literature [7].

The hematoxylin- and eosin-stained soft tissue specimen in our case showed the presence of mass of mature adipocytes arranged in lobules surrounded by a fibrous capsule. There was no evidence of cellular atypia. On the basis of microscopic features, it can be classified as simple lipoma.

Although rare, the malignant transformation of lipoma has also been reported [11]. The malignant characteristics are defined by cellular proliferation and pleomorphism, myxoid differentiation, increased vascularity, and mitosis [7].

The treatment of choice for lipoma is surgical excision; however, the removal can be difficult in situations if they are positioned deeply like our case. Depending on the location and extension of the lesion, the surgeon have the choice between an intraoral approach or a transcuteaneous access [13].

In the present patient, a complete excision was made through a blunt dissection due to the thin capsule of the lesion. Deep-seated and large-sized lipomas in esthetic regions of the face oblige the surgeons to look for esthetic alternative [14]. Therefore, this paper proposes an intraoral approach to remove a lesion without esthetic compromise.

Recurrence following surgical removal are rare [9]. Nevertheless, diabetes patients should undergo regular follow-up as explained above.

CONCLUSION

Oral lipomas are uncommon benign tumours. They are typically slow-growing and asymptomatic masses, mainly discovered during routine dental check-up. Nevertheless, the location and size growth over

years may cause discomfort during speech and mastication and esthetic problems.

The conservative surgical excision still remains the treatment of choice for this lesion. Nonsurgical treatment approach may be suggested in the future.

Although this entity is rare, it's important that clinicians should always consider intraoral lipoma in their differential diagnosis of a benign swelling in oral cavity.

Conflicts of interest: All the authors declare not having any conflicts of interest.

Funding: The authors received no financial support for the research, authorship, and/or publication of this article.

BIBLIOGRAPHY

- Hoseini, A. T., Razavi, S. M., & Khabazian, A. (2010). Lipoma in oral mucosa: two case reports. *Dental research journal*, 7(1), 41-43.
- Sharma, G., Jain, K., Nagpal, A., & Baiju, C. S. (2016). A rare presentation of lipoma on mandibular mucogingival junction. *Journal of Indian Society of Periodontology*, 20(2), 199-202.
- Filho, G. A. N., Caputo, B. V., dos Santos, C. C., Souza, R. S., Giovani, E. M., Scabar, L. F., & Allegratti, C. E. (2010). Diagnosis and treatment of intraoral lipoma: a case report. *J Health Sci Inst*, 282, 129-31.
- Kumar, L. K., Kurien, N. M., Raghavan, V. B., Menon, P. V., & Kharam, S. A. (2014). Intraoral lipoma: a case report. *Case reports in medicine*, 2014.
- Alharbi, A. S. (2020). Intraoral Lipoma of the Cheek—A Case Report With a One-Year Follow-up and Review of Literature. *Cureus*, 12(9).
- Venkateswarlu, M., Geetha, P., & Srikanth, M. (2011). A rare case of intraoral lipoma in a six year-old child: a case report. *International journal of oral science*, 3(1), 43-46.
- Furlong, M. A., Fanburg-Smith, J. C., & Childers, E. L. (2004). Lipoma of the oral and maxillofacial region: Site and subclassification of 125 cases. *Oral Surgery, Oral Medicine, Oral Pathology, Oral Radiology, and Endodontology*, 98(4), 441-450.
- Nayak, S., & Nayak, P. (2011). Lipoma of the oral mucosa: a case report. *Arch Orofac Sci*, 6(1), 37-39.
- Mehendiratta, M., Jain, K., Kumra, M., & Manjunatha, B. S. (2016). Lipoma of mandibular buccal vestibule: a case with histopathological literature review. *Case Reports*, 2016, bcr2016215586.
- de Freitas, M. A., Freitas, V. S., de Lima, A. A. S., Pereira Jr, B., & Nunes dos Santos, J. (2009).

Intraoral lipomas: a study of 26 cases in a Brazilian population. *Quintessence International*, 40(1), 79–85.

11. Park, B. G., Choi, D. J., Park, J. W., & Kim, J. S. (2015). Oral cavity lipoma: a case report. *Journal of the Korean Association of Oral and Maxillofacial Surgeons*, 41(4), 213-216.
12. Debnath, S. C., & Saikia, A. (2010). Lipoma of the parotid gland extending from the superficial to the deep lobe: a rarity. *British Journal of Oral and Maxillofacial Surgery*, 48(3), 203-204.
13. Ellis, E. III., & Zide, M. F. (2005). *Surgical Approaches to the Facial Skeleton*. 2nd ed. Baltimore, MD: Williams & Wilkins.
14. dos Santos Trento, G., Stringhini, D. J., Rebellato, N. L. B., & Scariot, R. (2017). Extra-oral excision of a buccal fat pad lipoma. *Journal of Craniofacial Surgery*, 28(3), e226-e227.