

Malignant Schwannoma of the Thigh in a Pediatric Patient: A Case Report

Sanae Chaouia^{1*}, Ghita Hadraoui¹, Basma Mahrouch¹, Youness El-Khadir¹, Oumayma Bounid¹, Tariq Igarramen¹, Rokkaya Iharti¹, Mouna Darfaoui¹, Abdelhamid El Omrani¹, Mouna Khouchani¹

¹Radiation Oncology Department, Mohammed VI Teaching Hospital, Marrakesh, Morocco

DOI: [10.36347/sjmcr.2021.v09i10.008](https://doi.org/10.36347/sjmcr.2021.v09i10.008)

| Received: 23.08.2021 | Accepted: 30.09.2021 | Published: 06.10.2021

*Corresponding author: Sanae Chaouia

Abstract

Case Report

Malignant schwannomas are rare types of malignant peripheral nerve sheath tumors composed of neoplastic Schwann cells. Many are discovered incidentally as solitary tumors. The cause is unknown. Most develop independently, although some are associated with genetic disorders such as neurofibromatosis type 2 or schwannomatosis. Schwannomas can emerge in any part of the body. They affect all age groups, with a peak occurrence between 25 and 40, without predilection to sex or race. Many are asymptomatic; nevertheless, symptoms such as paresthesia and pain are induced by mass effect and direct nerve invasion. A thorough physical examination, imaging modalities such as magnetic resonance imaging, and surgical biopsy are used to make a diagnosis. Treatment is affected by several parameters, such as the location of the tumor and the severity of the symptoms. Asymptomatic patients are treated conservatively, whereas those who are symptomatic undergo surgical resection with a favorable prognosis.

Keywords: Schwannoma, Malignant, thigh, children.

Copyright © 2021 The Author(s): This is an open-access article distributed under the terms of the Creative Commons Attribution **4.0 International License (CC BY-NC 4.0)** which permits unrestricted use, distribution, and reproduction in any medium for non-commercial use provided the original author and source are credited.

INTRODUCTION

Malignant peripheral nerve sheath tumors (MPNST) are the current term for malignant tumors of the peripheral nerves. MPNST are any clinically or histologically malignant tumors that arise from cells in peripheral nerve sheaths. These tumors account for around 10% of all soft tissue sarcomas. They appear in three forms: sporadic, related with neurofibromatosis type 1, and as a consequence of irradiation [1]. The tumors have the potential for malignancy and fast metastasis, especially when combined with neurofibromatosis [2]. It requires a precise, early diagnosis based on imaging techniques and histological investigations to determine the appropriate treatment strategy. Surgery is the recommended treatment option supplemented by postoperative irradiation and/or chemotherapy. Despite aggressive surgery and adjuvant treatment, patients with MPNST have a poor prognosis; nevertheless, prognostic factors have not been reported consistently in the literature to date [3-5].

CASE PRESENTATION

Our patient is an 11 years-old boy with an eventful family history. In February 2020, he observed a tumor growing on the anteromedial region of his left

thigh under the groin, which was gradually enlarging. He had no symptoms and no neurological impairment other than a sense of pressure in the lower part of his thigh. After a visit to the Paediatric Surgery Department, an MRI was performed with a finding of an extensive, probably malignant expansion of the anteromedial compartment of the left thigh in close touch with the vascular and nerve structures, measuring 8.5 x 3.4 x 6 cm (Figure 1). An excisional biopsy of the lesion was performed in the Department with the following conclusion: Malignant sarcoma primarily referring to a malignant schwannoma of the peripheral nerve. Post-operative MRI showed the persistence of a superficial femoral perivascular lesion, compatible with a tumor residue. Due to that, adjuvant chemotherapy was administered based on vincristine, adriamycin, and cyclophosphamide (4 cycles). During the subsequent follow-ups, there was a significant progression of the actual lesion.

At this stage, the patient was referred to the Pediatric Surgery department for a total excision due to the unsafe resection margins. Then he was referred to our department for further management.

The case was discussed in a multidisciplinary meeting, which recommended deferring radiotherapy after completion of the surgical resection. The patient

was addressed to surgery, but, the parents refused the procedure, then he was lost to follow-up. He died after five months from complications.

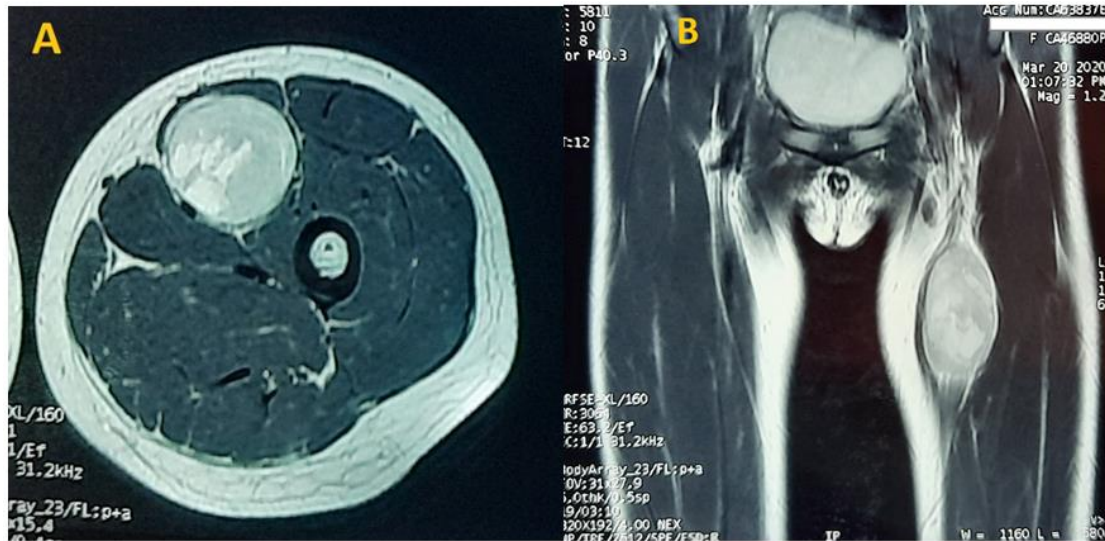


Fig-1: A: T2-weighted axial magnetic resonance image of an extensive malignant expansion of the anteromedial compartment of the left thigh in close touch with the vascular and nerve structures. **B:** T2-weighted frontal magnetic resonance image of the extensive malignant expansion of the anteromedial compartment of the left thigh.

DISCUSSION

Malignant schwannomas are uncommon sarcomas that evolve from the Schwann sheath cells that surround peripheral nerve fibers. It is a nerve sheath tumor described as aggressive and severely malignant, with a low survival rate despite treatment[2]. They often damage the central nerve trunks, especially those of the upper limb. The posterior tibial nerve is the most often afflicted nerve in the lower limb [6-8]. These tumors are extremely uncommon in children and more often affect adults ranging from 25 to 40[9].

Most schwannomas are asymptomatic; however, they may become symptomatic after so many months or years. The tumor's mass effect can induce pain at the location of the lesion and radiate pain along the course of the concerned nerve. Physical examination may reveal a lump on the knee, and because of the non-specific symptoms, it is challenging to differentiate schwannomas from other soft tissue tumors. Ganglion cysts, lipomas, and lipofibromatous hamartomas are often easily compressible and smooth to the touch, whereas schwannomas are firm to the touch[4, 5, 10].

The ultrasound examination usually reveals a focal soft tissue mass within the nerve host. MRI is the recommended examination for identifying the tumor and its connections to the nerve [11, 12]. Histopathology would be used to make the final diagnosis.

The mainstay of treatment for malignant schwannoma is radical in bloc resection. However, The

quality of the resection influences the use of future oncological therapy[13]. Survival after surgery is 79% if the removal is complete and 22% if the removal is impossible or in metastases[9].

CONCLUSION

Anterior thigh schwannoma is a rare tumor, in which the pathogenesis is still unknown. More research is needed to understand this entity, in order to help making the diagnosis and to provide better treatment.

REFERENCE

- Chalk, C. (2010). Focal Peripheral Neuropathies, 4th ed. *Neurol Int.* 26, 2(2):e19.
- Cashen, D. V., Parisien, R. C., Raskin, K., Hornicek, F. J., Gebhardt, M. C., & Mankin, H. J. (2004). Survival data for patients with malignant schwannoma. *Clinical Orthopaedics and Related Research*, 426, 69-73.
- Ghosh, B. C., Ghosh, L., Huvos, A. G., & Fortner, J. G. (1973). Malignant schwannoma. A clinicopathologic study. *Cancer*, 31(1), 184-190.
- Vauthey, J. N., Woodruff, J. M., & Brennan, M. F. (1995). Extremity malignant peripheral nerve sheath tumors (neurogenic sarcomas): a 10-year experience. *Annals of surgical oncology*, 2(2), 126-131.
- Sordillo, P. P., Helson, L., Hajdu, S. I., Magill, G. B., Kosloff, C., Golbey, R. B., & Beattie, E. J. (1981). Malignant schwannoma—clinical characteristics, survival, and response to therapy. *Cancer*, 47(10), 2503-2509.
- Nawabi, D. H., & Sinisi, M. (2007). Schwannoma of the posterior tibial nerve: the problem of delay in

- diagnosis. *The Journal of bone and joint surgery. British volume*, 89(6), 814-816.
7. D'Agostino, A. N., Soule, E. H., & Miller, R. H. (1963). Sarcomas of the peripheral nerves and somatic soft tissues associated with multiple neurofibromatosis (von Recklinghausen's disease). *Cancer*, 16(8), 1015-1027.
 8. Woertler K. Tumors and tumor-like lesions of peripheral nerves. *Semin Musculoskelet Radiol*. nov 2010;14(5):547-58.
 9. Dubousset, J. (2001). Tumeurs des tissus mous chez l'enfant et l'adolescent. *Cahiers d'enseignement de la SOFCOT*, 78, 19-32.
 10. Gosk, J., Gutkowska, O., Mazurek, P., Koszewicz, M., & Ziółkowski, P. (2015). Peripheral nerve tumours: 30-year experience in the surgical treatment. *Neurosurgical review*, 38(3), 511-521.
 11. Créteur, V., Bacq, C., Fumière, E., Bissen, L., & Delcour, C. (2007). Sonography of peripheral nerves. Part II: lower limbs. *Journal de radiologie*, 88(3 Pt 1), 349-360.
 12. Beaman, F. D., Kransdorf, M. J., & Menke, D. M. (2004). Schwannoma: radiologic-pathologic correlation. *Radiographics*, 24(5), 1477-1481.
 13. Ferner, R. E., & Gutmann, D. H. (2002). International consensus statement on malignant peripheral nerve sheath tumors in neurofibromatosis 1.