

## An Unusual Case Report of Delayed Acute Pulmonary Embolism after Mild-COVID-19: Value of Post-Discharge Thromboprophylaxis?

Falmata Laouan Brem<sup>1\*</sup>, Désiré Massimbo<sup>1</sup>, Noha El Ouafi<sup>1,2</sup>, Bazid Zakaria<sup>1</sup>

<sup>1</sup>Department of Cardiology, Mohammed VI University Hospital, Faculty of Medicine and Pharmacy of Oujda, Mohammed First University, Oujda, MAR.

<sup>2</sup>Epidemiological Laboratory of Clinical Research and Public Health, Faculty of Medicine and Pharmacy of Oujda, Mohammed First University, Oujda, MAR.

DOI: [10.36347/sjmcr.2021.v09i10.012](https://doi.org/10.36347/sjmcr.2021.v09i10.012)

| Received: 11.04.2021 | Accepted: 15.05.2021 | Published: 07.10.2021

\*Corresponding author: Falmata Laouan Brem

### Abstract

### Case Report

COVID-19-related hypercoagulability state resulting in thromboembolic events is widely described in critically ill patients, especially in those hospitalized in the intensive care unit. Nevertheless, these thrombotic events are uncommon in COVID-19-patients with mild disease. Herein we present the case of a 51-year-old male admitted for pulmonary embolism who previously presented a mild COVID-19 twenty days earlier. He was discharged on Rivaroxaban. This finding raises discussion about extending prophylactic anticoagulation in selected patients with mild COVID-19 at a high risk of VTE.

**Keywords:** Case report, Post-COVID-19, Mild disease, Pulmonary embolism, thromboprophylaxis, anticoagulation.

**Copyright © 2021 The Author(s):** This is an open-access article distributed under the terms of the Creative Commons Attribution 4.0 International License (CC BY-NC 4.0) which permits unrestricted use, distribution, and reproduction in any medium for non-commercial use provided the original author and source are credited.

## INTRODUCTION

The SARS-CoV-2 infection symptoms are mainly respiratory. [1] However, subjects who have contracted this disease may be asymptomatic or present mild symptoms of COVID-19. [i] Since the emergence of this novel Coronavirus (SARS-CoV-2) lately in December 2019 causing a global COVID-19 pandemic, [ii] thromboembolic events are being interestingly recognized in COVID-19-patients especially pulmonary embolism and so more in patients with severe illness. [iii] However, these events are uncommon in those with a mild disease, [iv] asymptomatic, or in those recovered from COVID-19 infection. [v] Here, we report a rare case of a 51-year-old male admitted for pulmonary embolism who previously presented a mild COVID-19 twenty days earlier.

## CASE PRESENTATION

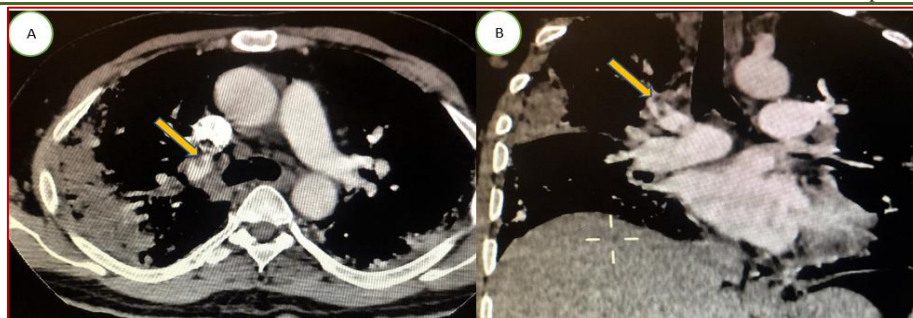
### Initial Admission

A 51-year-old male with a previous history of diabetes mellitus tested positive for the SARS-CoV-2 reverse transcription-polymerase chain reaction (RT-PCR) after eight days of fever and dry cough. He was hospitalized in general wards and received treatment

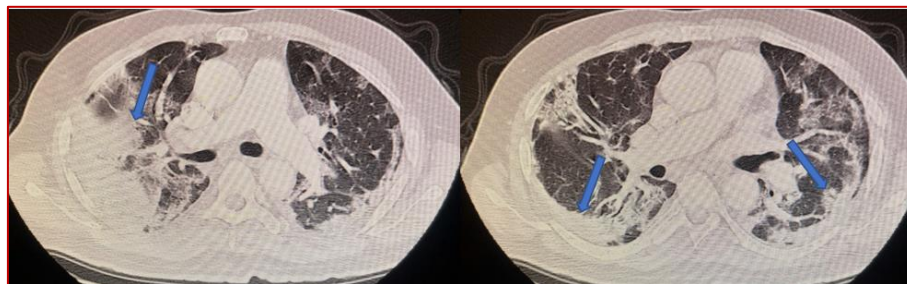
with hydroxychloroquine, prophylactic dose of anticoagulation with enoxaparin and, azithromycin. His condition improved and he was discharged five days later.

### Second hospitalization

Twenty days after discharge, he presented to emergency department for sudden dyspnea. On admission, he was hemodynamically stable, oxygen saturation at 88% in the room air. The physical examination revealed no abnormalities. Biological assessment revealed a decreased count of lymphocytes cells level of 790 elements/mm<sup>3</sup>, a high level of C-reactive protein (CRP) at 242 mg/L, a high level of ferritin at 2442ng/mL, and elevated D-dimer level (10300ng/mL). A computed tomography pulmonary angiography (CTPA) was performed and showed a filling defect in the right pulmonary artery extended to lobar arteries (**Figure 1**). Chest computed tomography (CT) scan showed COVID-19 pneumonia related-radiological findings such as bilateral subpleural ground-glass opacities as well as a consolidation. (**Figure 2**) A second COVID-19 RT-PCR was performed and showed a negative result. The patient received a curative anticoagulation with enoxaparin. After ten days, he was discharged on Rivaroxaban.



**Fig-1:** A computed tomography pulmonary angiography (CTPA) in axial (A) and (B) windows showing acute pulmonary embolism. (Yellow arrows)



**Fig-2:** Chest computed tomography (CT) scan in axial window revealing COVID-19 pneumonia related-radiological findings such as bilateral subpleural ground-glass opacities as well as a consolidation. (Blue arrows)

## DISCUSSION

Pulmonary outcomes after COVID-19 remain unknown. However, a recent study reported the association with significant functional and radiological abnormalities in severe/critical COVID-19 four months after COVID-19 infection. [vi] While pulmonary embolism has been little reported in hospitalized patients with a mild COVID-19 disease, [iv] its late occurrence in those who were discharged from hospital with a mild disease is a rare condition. [vii] In fact, there has been a few cases of delayed pulmonary embolism in patients discharged after COVID-19 even under thromboprophylaxis, and most of them were severely ill. [viii] Therefore, the incidence of PE in hospitalized or discharged patients with mild COVID-19 symptoms is unknown. Vechi HT *et al.* [ix] reported five cases of mild COVID-19 outpatients, diagnosed between the third and the fourth week after the onset of symptoms with acute pulmonary embolism after an apparent clinical improvement. They concluded that thromboembolic events can also complicate the early course of mild COVID-19 or manifest later in the disease's course. There has been a single report of 41-year-old patient with pulmonary embolism 5 months after COVID-19. [x]

The hypercoagulability state during the COVID-19 disease seems to persist after hospital discharge, despite well-conducted thromboprophylaxis. [viii] Nonetheless, current guidelines do not recommend prophylactic anticoagulation in non-hospitalized patients with COVID-19. [xi] Furthermore, there have been controversial recommendations on extending prophylactic anticoagulation after hospital

discharge. Some authors recommend post-discharge thromboprophylaxis in COVID-19-patients with LMWH or the direct oral anticoagulants for approximately 14-30 days, based on the high-risk of VTE. [xii; xiii]

Our patient presented mild COVID-19 symptoms and diagnosed with PE twenty days after hospital discharge while he received prophylactic anticoagulation during his first hospitalization. This suggests that a residual thrombotic risk exists in patients with a mild disease after hospital discharge, raising the question of extending prophylactic anticoagulation to post-discharge in patients with a mild COVID-19 disease at a high-risk of VTE. Therefore, it may be reasonable to suggest that there may be a potential risk of VTE even in patients with a mild COVID-19 disease even after discharge and not only critically ill patients.

## CONCLUSION

Although the striking relationship of VTE with moderate and severe COVID-9 cases has been established, its mechanism in mild-COVID-19 is still unknown. However, this rare case of a mild COVID-19 who lately developed PE, suggests that thromboembolic events can also complicate the early course of mild COVID-19 or manifest later in the disease's course. Nevertheless, further studies are needed to assess whether there is a benefit of extending thromboprophylaxis in this population.

**Conflict of interest:** The authors declare non-conflicts of interest

## REFERENCE

1. Huang C, Wang Y, Li X, et al. Clinical features of patients infected with 2019 novel coronavirus in Wuhan, China. *Lancet*. (2020) 395:497–506. doi:10.1016/S0140-6736(20)30183-5
2. Miri SM, Noorbakhsh F, Mohebbi SR, Ghaemi A. Higher prevalence of asymptomatic or mild COVID-19 in children, claims and clues. *J Med Virol*. 2020 Nov; 92(11):2257-2259.
3. World Health Organization. WHO announces COVID-19 outbreak a pandemic. March 12th, 2020. Coronavirus disease (COVID-19) outbreak. Geneva: World Health Organization, 2020.
4. Helms J, Severac F, Merdji H, Anglés-Cano E, Meziani F. Prothrombotic phenotype in COVID-19 severe patients. *Intensive Care Med*. 2020 Jul; 46(7):1502-1503.
5. Norberto B Fiorini, Fernando Garagoli, Rosana C Bustamante, Rodolfo Pizarro, Acute pulmonary embolism in a patient with mild COVID-19 symptoms: a case report, *European Heart Journal - Case Reports*, Volume 5, Issue 1, January 2021, ytaa563, <https://doi.org/10.1093/ehjcr/ytaa563>
6. Laouan Brem F, Rasras H, El Ouafi N, et al. (March 12, 2021) Bilateral Pulmonary Embolism in Patients Recovered From Asymptomatic COVID-19 Infection. *Cureus* 13(3): e13848. doi:10.7759/cureus.13848
7. Guler SA, Ebner L, Beigelman C, et al. Pulmonary function and radiological features four months after COVID-19: first results from the national prospective observational Swiss COVID-19 lung study. *Eur Respir J*. 2021 Jan 8:2003690. doi:10.1183/13993003.03690-2020.
8. Vechi HT, Maia LR, Alves MDM. Late acute pulmonary embolism after mild Coronavirus Disease 2019 (COVID-19): a case series. *Rev Inst Med Trop Sao Paulo*. 2020 Sep 4;62:e63. doi:10.1590/S1678-9946202062063.
9. Falmata Laouan Brem et al. Late-onset of pulmonary embolism following hospitalization for COVID-19 despite thromboprophylaxis: a report of two cases. *Pan African Medical Journal*. 2021;38:226. doi:10.11604/pamj.2021.38.226.28503
10. Vechi HT, Maia LR, Alves MDM. Late acute pulmonary embolism after mild Coronavirus Disease 2019 (COVID-19): a case series. *Rev Inst Med Trop Sao Paulo*. 2020;62:e63. Published 2020 Sep 4. doi:10.1590/S1678-9946202062063
11. Taha M, Nguyen P, Sharma A, Taha M, Samavati L. Forty-One-Year-Old Man with Pulmonary Embolism 5 Months After COVID-19. *Clinical Medicine Insights: Circulatory, Respiratory and Pulmonary Medicine*. January 2021. doi:10.1177/1179548420986659
12. Antithrombotic therapy in patients with COVID-19. Updated May 12, 2020. <https://www.covid19treatmentguidelines.nih.gov/adjunctivetherapy/antithrombotic-therapy/>.
13. Spyropoulos AC, Levy JH, Ageno W, et al. Scientific and Standardization Committee communication: Clinical guidance on the diagnosis, prevention, and treatment of venous thromboembolism in hospitalized patients with COVID-19. *J Thromb Haemost*. 2020 Aug; 18(8):1859-1865.
14. Spyropoulos AC, Lipardi C, Xu J, et al. Modified IMPROVE VTE Risk Score and Elevated D-Dimer Identify a High Venous Thromboembolism Risk in Acutely Ill Medical Population for Extended Thromboprophylaxis. *TH Open*. 2020 Mar 13;4(1): e59-e65.