

## Outcome of Fixation of Spondylolisthesis Grade I and Fusion with Bone Graft without Metallic Cage, Experiences in Private Hospitals

Dr. Md Mizanur Rahman<sup>1\*</sup>, Dr. Md Mahfuzur Rahman<sup>2</sup>, Dr. Sajedur Reza Faruquee<sup>3</sup>, Dr. Mohammad Sadequr Rahman<sup>4</sup><sup>1</sup>Assistant Professor (Orthopedic Surgery), Mugda Medical College, Mugda, Dhaka, Bangladesh<sup>2</sup>Associate Professor (Neuro-Trauma), National Institute of Neuroscience & Hospital, Dhaka, Bangladesh<sup>3</sup>Associate Professor (Orthopaedics), National Institute of Traumatology and Orthopaedic Rehabilitation (NITOR), Sher E Bangla Nagar, Dhaka, Bangladesh<sup>4</sup>Assistant Professor Ear Nose and Head Neck Department, US Bangla Medical College, Dhaka, BangladeshDOI: [10.36347/sjams.2021.v09i10.020](https://doi.org/10.36347/sjams.2021.v09i10.020)

| Received: 04.09.2021 | Accepted: 10.10.2021 | Published: 24.10.2021

\*Corresponding author: Dr. Md Mizanur Rahman

## Abstract

## Original Research Article

**Background:** Hard working people seldomly suffer from backpain may caused from spondylolisthesis. **Objectives:** The purpose of the present study was to find out the Clinical results and Status of radiological fusion of spondylolisthesis in Lumbar Spine. **Methodology:** This cross-sectional study was conducted at two private Hospitals, Islami Bank Hospital, Motijheel and Islamia General Hospital, Jatrabari, Dhaka, Bangladesh from January 2013 to June 2017 for a period of 4.5 years and average follow up period is 5 years. Patients with diagnosed cases of Spondylolisthesis irrespective of age and sex were selected as study population. An elaborate history of the selected patient was taken with an emphasis of occupation, time of symptoms, past history of hard working. Inclusion criteria was unstable, degenerative spondylolisthesis grade I irrespective of age and sex, not previously treated by surgery and did not use metallic cages are recruited in this Study. Exclusion criteria was grade II and above grade, traumatic spondylolisthesis, previously surgically treated patients and planning to use metallic cage. Every patient was treated by fixation of listhetic spines, decompression by laminectomy and giving autogenous bone graft from spinous process and lamina without metallic cages. **Result:** A total number of 40 patients with Spondylolisthesis in lumbar spine were recruited. Out of 40 patients, 32(80%) patients were in the age group of 31-60 years that is active age group, The mean age was 45.92 years. Immediate post operative pain relief Significant and moderate (28+11) 97.5%, Post operative Radiating pain Improves almost Nil and mild (31+8) 97.5%, after six months follow up post operative radiological fusion achieved (36) 90%. **Conclusion:** In the management of unstable, degenerative spondylolisthesis grade I, Fixation, Decompression and putting autogenous bone graft without metallic cage is good option of treatment.

**Keywords:** Spondylolisthesis, Bone graft, Metallic cage.

Copyright © 2021 The Author(s): This is an open-access article distributed under the terms of the Creative Commons Attribution 4.0 International License (CC BY-NC 4.0) which permits unrestricted use, distribution, and reproduction in any medium for non-commercial use provided the original author and source are credited.

## INTRODUCTION

Subluxation of one vertebra on another occurs when the vertebra moves forward in relation to its neighboring vertebra. Lumbar fusion surgery helps stabilize the spine in cases of lumbar spondylolisthesis, which in turn helps patients with persistent low back pain and impairment. For surgical management of spondylolisthesis, several lumbar fusion techniques have been described, including posterior lumbar fusion (PLF), posterior lumbar interbody fusion (PLIF), anterior lumbar interbody fusion, circumferential 360 fusion (front and back), and the transforaminal lumbar interbody fusion (TLIF) [1, 2]. Cloward developed PLIF in 1940 using a tricortical bone graft transplant from iliac bone [3].

Brantigan and Steffee created the first interbody cage with a carbon fiber reinforced implant [4].

The interbody cages evolved fast in the years that followed, with several variation kinds including titanium cages, and the use of cages in conjunction with locally morcellized bone graft rather than tricortical iliac bone graft became the norm of contemporary treatment [5]. In underdeveloped and developing nations, a different method is used with locally morcellized autograft from the posterior components removed during decompression in spondylolisthesis in instrumented interbody fusion without cages due of the high cost.

In this study our main goal is to evaluate the outcome of Fixation of Spondylolisthesis Grade I and fusion with Bone graft without Metallic cage.

## OBJECTIVE

To assess the outcome of Fixation of Spondylolisthesis Grade I and fusion with Bone graft without Metallic cage.

## METHODOLOGY

This cross-sectional study was conducted at two private Hospitals, Islami Bank Hospital, Motijheel and Islamia General Hospital, Jatrabari, Dhaka, Bangladesh from January 2013 to June 2017 for a period of 4.5 years. Patients with diagnosed cases of Spondylolisthesis irrespective of age and sex were selected as study population. An elaborate history of the selected patient was taken with an emphasis of occupation, time of symptoms, past history of hard working. Inclusion criteria was spondylolisthesis grade I irrespective of age and sex, unstable, not previously

treated by surgery and did not use metallic cages are recruited in this study. Exclusion criteria was grade II and above grade, previously surgically treated patients and planning to use metallic cage. Every patient was treated by fixation of listhetic spines, decompression by laminectomy and giving autogenous bone graft from spinous process and lamina, without metallic cages.

All collected data were coding and input in SPSS-25 for further analysis. Both descriptive and inferential statistics done. Descriptive statistics included frequency distribution, percent, mean, standard deviation; graph, tables, figures and inferential statistics.

## RESULTS

In Figure-1 shows age group of the patients where most of the patients belong to 31-40- and 41-50-years age group, 27.5%. The following figure is given below in detail:

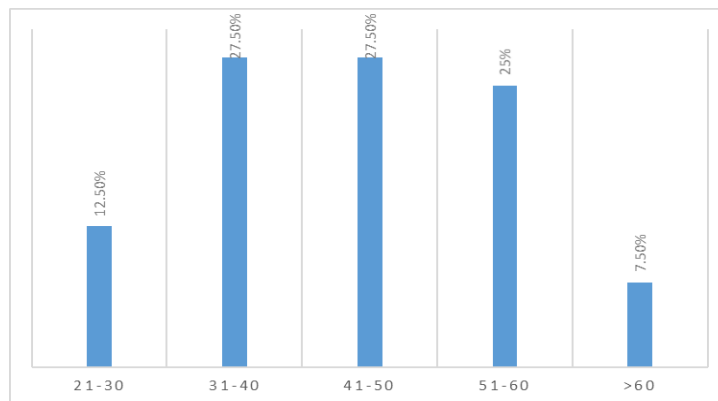


Figure-1: Age Group

In Table-1 shows Post-Operative Radiating pain relief in Graphic Rating Scale where total patients n = 40, among those 77.5% patients didn't have any radiating pain after operation where as 20% patients

feel mild pain and 2.5% patient shows moderate level of radiating pain after surgery. The following table is given below in detail:

Table-1: Post-Operative Radiating pain relief (Graphic Rating Scale)

Level of Radiation	Preoperative	Post operative	Percentage
No pain	0	31	77.5%
Mild	01	08	20%
Moderate	08	01	2.5%
Severe	28	0	0%
Excruciating	03	0	0%

In table-2 shows distribution of patients according to level of fixation, where we found total

fixation level n=45, among those L34 level 06 (13.33%), L45 level 19 (42.22%) and L5S1 20(44.44%)

Table 2: Distribution of patients according to level of fixation

No	Level of fixation	Number of patients	Percentage
01	L 3,4	06	13.33%
02	L 4,5	19	42.22%
03	L5S1	20	44.44%

In Table-3 shows distribution of patients according to level of fixation, where we found single

level fixation 35 (87%) and Double level fixation 05 (13%)

**Table 3: Distribution of patients according to Number of fixation Level**

01	Single level	35	87%
02	Double level	05	13%

In Table-4 shows Post-operative Listhesis Reduction status where Listhesis was reduced 42.5%

cases were unchanged 57.5% cases. The following table is given below in detail:

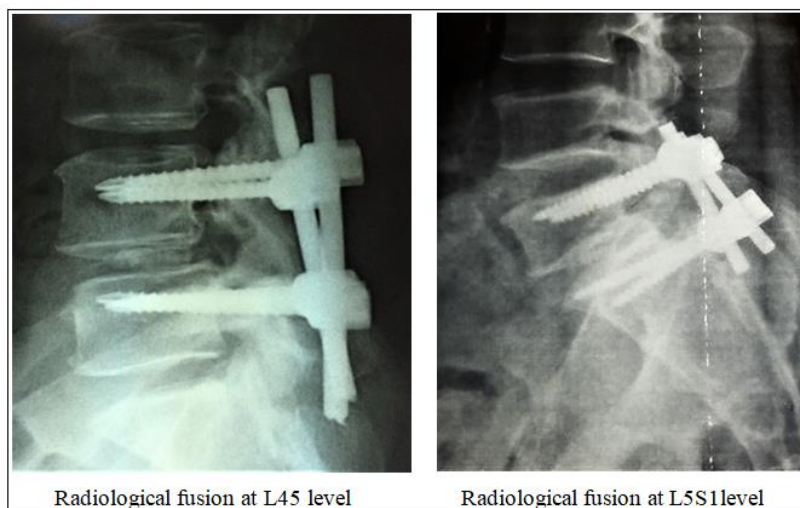
**Table-4: Post-operative Listhesis Reduction status**

Status of Reduction	Number of Patients	Percentage
Reduced	17	42.5%
unreduced	23	57.5%

In Table-5 shows post-Operative Radiological fusion where 90% cases fusion were completed. The following table is given below in detail:

**Table-5: post-Operative Radiological fusion**

Fusion status	Number of patients	Percentage
Fusion complete	36	90%
Fusion not occur	04	10%



## DISCUSSION

Study in 2006, reported no difference in the outcome in using an interbody cage to treat single-level degenerative spondylolisthesis compared with interbody fusion without a cage [6].

In 2010, one study compared titanium cage versus iliac bone graft in interbody fusion. Results were in favor of titanium cages [7]. In 2011, it was found that, the clinical outcome was excellent in 52%, fusion rate was 100% at 18 months [8].

In 2015, one study compared PLIF with locally sourced bone chips to PLIF with a cage. Clinical and radiological outcomes showed no statistically significant difference. <sup>10</sup> In 2016, another report compared the polyetheretherketone cage versus autologous cage using the lumbar spinous process and

laminae in lumbar interbody fusion. Again, results showed no significant difference between the groups clinically or radiologically [9].

In our case without metallic cage, 77.5% patients didn't have any radiating pain after operation and 20% patients have mild pain, 90% cases bony fusion was completed in 6 months follow up. While Listhesis condition was reduced 42.5% cases were unchanged 57.5% cases. Whereas, in one study showed that, there was no significant difference in outcome between the spondylolisthesis patients, who were treated with direct bone graft only, and those with degenerative disc, who additionally underwent a fusion procedure with bone grafting metallic cage [10].

## CONCLUSION

After reviewing results, we can conclude that, in management of Spondylolisthesis grade I, Fixation, Decompression and putting autogenous bone graft without metallic cage is good option of treatment and cost effective.

## REFERENCE

1. Ha, K. Y., Na, K. H., Shin, J. H., & Kim, K. W. (2008). Comparison of posterolateral fusion with and without additional posterior lumbar interbody fusion for degenerative lumbar spondylolisthesis. *Clinical Spine Surgery*, 21(4), 229-234.
2. Lee, C. K., & Kopacz, K. J. (2006). In: Rothman "Simeone the Spine. Herkowitz, H. N., Garfin, S. R., Eismont, F. J., Bell, G. R., Balderston, R. A., editors. Philadelphia: Elsevier; pp. 350–360.
3. Cloward, R. B. (1953). The treatment of ruptured lumbar intervertebral discs by vertebral body fusion: I. Indications, operative technique, after care. *Journal of neurosurgery*, 10(2), 154-168.
4. Brantigan, J. W., & Steffee, A. D. (1993). Carbon Fiber Implant to Aid Interbody Lumbar Fusion: 1-year Clinical Results in the First 26 Patients. In *Lumbar Fusion and Stabilization* (pp. 379-395). Springer, Tokyo.
5. Okuyama, K., Kido, T., Unoki, E., & Chiba, M. (2007). PLIF with a titanium cage and excised facet joint bone for degenerative spondylolisthesis—in augmentation with a pedicle screw. *Clinical Spine Surgery*, 20(1), 53-59.
6. Cloward, R. B. (1985). Posterior lumbar interbody fusion updated. *Clinical orthopaedics and related research*, (193), 16-19.
7. Raman, A. S., Crawford, R., Kakkar, R., Rai, A. S., & Crawford, R. J. (2008, August). Posterior lumbar interbody fusion for degenerative spondylolisthesis: a comparison of results: using non structural autograft alone versus interbody cage with autograft. In *Orthopaedic Proceedings* (Vol. 90, No. SUPP\_III, pp. 456-456). The British Editorial Society of Bone & Joint Surgery.
8. Fathy, M., Fahmy, M., Fakhri, M., Aref, K., Abdin, K., & Zidan, I. (2010). Outcome of instrumented lumbar fusion for low grade spondylolisthesis; Evaluation of interbody fusion with & without cages. *Asian journal of neurosurgery*, 5(1), 41-47.
9. Müslüman, A. M., Yılmaz, A., Cansever, T., Çavuşoğlu, H., Çolak, İ., Genç, H. A., & Aydın, Y. (2011). Posterior lumbar interbody fusion versus posterolateral fusion with instrumentation in the treatment of low-grade isthmic spondylolisthesis: midterm clinical outcomes. *Journal of Neurosurgery: Spine*, 14(4), 488-496.
10. Hu, M. W., Liu, Z. L., Zhou, Y., Shu, Y., L. Chen, C., & Yuan, X. (2012). Posterior lumbar interbody fusion using spinous process and laminae. *The Journal of bone and joint surgery. British volume*, 94(3), 373-377.