

## Case Report on Pemphigus Vulgaris

Simhavalli.Godavarthi\*, Bammidi Tushara, Krishnapriya Lakhinana, Kosuru Chandini

Avanathi Institute of Pharmaceutical Sciences, Thagarapavalasa, Andhra Pradesh, India

DOI: [10.36347/sjmcr.2021.v09i10.028](https://doi.org/10.36347/sjmcr.2021.v09i10.028)

| Received: 16.09.2021 | Accepted: 23.10.2021 | Published: 30.10.2021

\*Corresponding author: Simhavalli. Godavarthi

### Abstract

### Case Report

This case report is mainly about the rare auto immune disease pemphigus vulgaris. Its onset appears on the basis of interaction between genetic predisposition and various triggering factors. Mostly it is clinical presented as oral lesions, mucosal lesions, skin blisters that are itchy and painful. It affects people around the age of 50 to 60 mostly Jewish heritages from southeast Europe, India and the Middle East. Basing on clinical features, histopathological and immunopathological findings it has to diagnose and must be treated immediately because, delayed treatment cannot be helpful and may cause fatality to the patient.

**Keywords:** Auto immune, pemphigus vulgaris, lesions, histopathology, immunopathology.

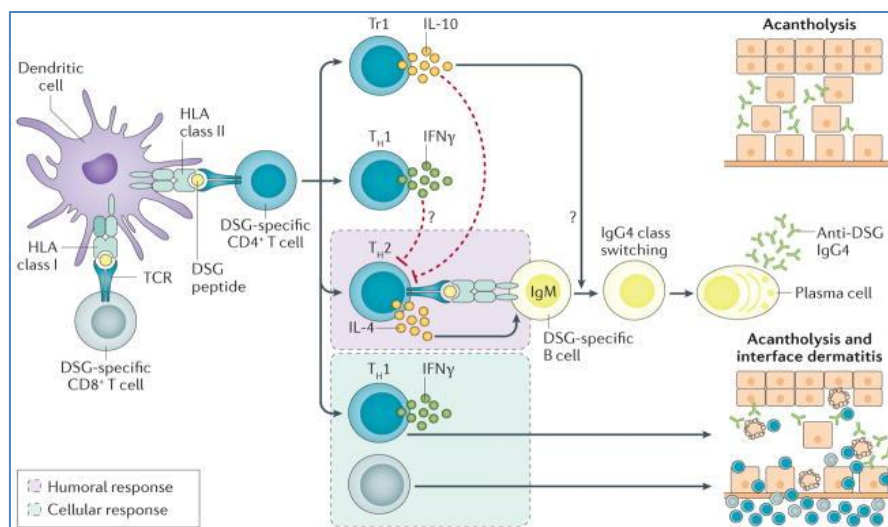
**Copyright © 2021 The Author(s):** This is an open-access article distributed under the terms of the Creative Commons Attribution 4.0 International License (CC BY-NC 4.0) which permits unrestricted use, distribution, and reproduction in any medium for non-commercial use provided the original author and source are credited.

## INTRODUCTION

Pemphigus is a distinct organ-specific autoimmune blistering complaint involving skin and mucous membranes associated with auto antibodies directed against desmosomes-intercellular tenacious patch complex localized on the keratinocyte cell surface [1]. pemphigus has three major variants, which are classified depending on the base of clinical, histological features, immunofluorescence staining pattern and autoantibody profile of the complaint including pemphigus vulgaris (PV), pemphigus foliaceus (PF) and paraneoplastic pemphigus (PNP),

which all have further subtypes [2-4] less constantly seen and newer variants of pemphigus include IgA pemphigus (IGAP) and pemphigus heretiformis (PH) [5].

The term "pemphigus" origins from Greek word "pemphix", which has a meaning of "blister". it's a chronic potentially life-threatening bullous complaint if not treated on time [6, 7]. the phenotypes of pemphigus represent a complex diapason with multiple inheritable and environmental factors playing a part in complaint pathogenesis [8].



**Fig-01: Pathophysiology of pemphigus**

## CASE REPORT

A female patient of age 27 years has come to dermatology ward with complaint of itchy pigmented lesions for 1 month. She has history lesions marked on flexor aspect of both fore arm and lower legs over a period of one month. her haemoglobin is 12.8 gm% and her other lab investigations states that “multiple highly pigmented flat shaped papules distributed bilaterally symmetrically over the upper limbs and lower legs. Her sample of unbroken blister was founded to be pemphigus vulgaris that cells in the epidermis. She was given Inj. Dexamethasone (decadron) 4mg/kg until her disease got cured, Inj. rantidine 150 mg IV - BD for 3 days, Tab.cetirizine 10mg p/o – OD, and betamethasone dipropionate cream until she is cured.

## DISCUSSION

Mostly to treat blisters it takes about 2-3 weeks of treatment. High dose of corticosteroids (dexamethasone) should be taken and gradually to be reduced to lower levels and treatment usually starts with oral corticosteroids and may later be combined with a so-called steroid-sparing drug or adjuvant drugs. Corticosteroids must not be stopped suddenly as their sudden cease can affect blood pressure and blood sugar levels. Inj rantidine is given to treat as they patients suffer with erosions of mucous membrane which is equal to ulcers. Cetirizine tablet is prescribed to eradicate allergies. Betamethasone dipropionate cream is used to treat itching, redness, dryness, crusting, scaling and any skin conditions that produce skin discomfort. Patient must cultivate some dietary and lifestyle modifications like avoiding spicy foods as they may be sensible to cause irritation to mucous layer and using soothing lotions or numbing lozenges for mouth blisters in case to manage wound. Patient must avoid too much of sun exposure and she must be always hydrated as dehydration can lead to complications such as skin infections, sepsis or spread of infection via blood stream.

## CONCLUSION

Pemphigus is a life-threatening disease and it has high risk of mortality so, it has to be diagnosed as early as possible and treatment should also be started instantaneously. The better apprehension of the role of immunological dysregulation in the pathogenesis will cause aiding a newly targeted therapeutically active agent in the treatment.

## ETHICAL APPROVAL

This study received support from King George Hospital, Visakhapatnam.

## ACKNOWLEDGEMENT

We acknowledge the continuous support from HOD of general medicine department superintendent of king George Hospital (KGH) for successfully completing the study.

## REFERENCE

1. Saito, M., Stahley, S. N., Caughman, C. Y., Mao, X., Tucker, D. K., Payne, A. S., & Kowalczyk, A. P. (2012). Signaling dependent and independent mechanisms in pemphigus vulgaris blister formation. *PLoS one*, 7(12), e50696.
2. Amagai, M., Koch, P. J., Nishikawa, T., & Stanley, J. R. (1996). Pemphigus vulgaris antigen (desmoglein 3) is localized in the lower epidermis, the site of blister formation in patients. *Journal of Investigative Dermatology*, 106(2), 351-355.
3. Amagai, M., Tsunoda, K., Zillikens, D., Nagai, T., & Nishikawa, T. (1999). The clinical phenotype of pemphigus is defined by the anti-desmoglein autoantibody profile. *Journal of the American Academy of Dermatology*, 40(2), 167-170.
4. Kárpáti, S., Amagai, M., Prussick, R., Cehrs, K., & Stanley, J. R. (1993). Pemphigus vulgaris antigen, a desmoglein type of cadherin, is localized within keratinocyte desmosomes. *The Journal of cell biology*, 122(2), 409-415.
5. Paus, R., Amagai, M., Ahmed, A. R., Kitajima, Y., Bystry, J. C., Milner, Y., & Grando, S. (2006). Are desmoglein autoantibodies essential for the immunopathogenesis of pemphigus vulgaris, or just “witnesses of disease”? *Experimental dermatology*, 15(10), 815-815.
6. Grando, S. A., Bystry, J. C., Chernyavsky, A. I., Frušić-Zlotkin, M., Gniadecki, R., Lotti, R., & Pincelli, C. (2009). Apoptolysis: a novel mechanism of skin blistering in pemphigus vulgaris linking the apoptotic pathways to basal cell shrinkage and suprabasal acantholysis. *Experimental dermatology*, 18(9), 764-770.
7. Lanza, A., Cirillo, N., Femiano, F., & Gombos, F. (2006). How does acantholysis occur in pemphigus vulgaris: a critical review. *Journal of cutaneous pathology*, 33(6), 401-412.
8. Spindler, V., & Waschke, J. (2018). Pemphigus—a disease of desmosome dysfunction caused by multiple mechanisms. *Frontiers in immunology*, 9, 136.