

Surgical Approach to Splenic Hydatid Cyst: A Case Report

El FDILI EL MOSTAPHA^{1*}, Tarik Souiki¹, Karim IBN Majdoub¹, Imane Toughrai¹, Khalid Mazaz¹

¹Digestive and Endocrine Surgery Department, Hassan II University Hospital in Fez

DOI: [10.36347/sasjs.2021.v07i11.009](https://doi.org/10.36347/sasjs.2021.v07i11.009)

| Received: 03.10.2021 | Accepted: 09.11.2021 | Published: 16.11.2021

*Corresponding author: El Fdili El Mostapha

Abstract

Case Report

Hydatid disease, or echinococcosis, is a widespread zoonotic parasitic disease caused by a tapeworm. It is most frequently caused by *Echinococcus granulosus*, and the liver is the most commonly involved organ, although it may affect other organs. Hydatid disease of the spleen is a rare condition with a worldwide incidence of 0.5–4% [10]. Hydatid cyst of the ovary is an extremely rare presentation and accounts for 0.2–1% of the diagnosed cases. It may be mistaken for ovarian cysts or cystic tumors of the ovary [1]. We present here a case report about a female patient who was admitted in gynecologic service for cystic tumor of ovary revealed by ultrasound and CT and operated by the realization of hysterectomy and adnexectomy. The macroscopic and microscopic exam reveals that the lesion is a hydatid cyst, the CT objectifies also a splenic hydatid cyst and the patient was transferred to the digestive surgery department for further management for surgery and the treatment was a total splenectomy.

Keywords: Hydatid cyst, spleen, ovary, diagnosis, Ultrasonography, CT scan, surgery, splenectomy, albendazole, follow-up.

Copyright © 2021 The Author(s): This is an open-access article distributed under the terms of the Creative Commons Attribution 4.0 International License (CC BY-NC 4.0) which permits unrestricted use, distribution, and reproduction in any medium for non-commercial use provided the original author and source are credited.

INTRODUCTION

Hydatid disease, which is most often caused by *Echinococcus granulosus*, can occur in virtually all parts of the body. The disease most frequently occurs in the liver followed by the lungs, muscles, and bones respectively. Primary ovarian hydatid cyst is a rare case [2].

Splenic hydatid disease has been reported to constitute up to 4% of cases of abdominal hydatid disease [3]. In this report, we present the case of a woman with concomitant splenic and ovary hydatid cysts.

CASE REPORT

A 65-year-old woman with arterial hypertension was admitted to our general surgery clinic with a splenic hydatid cyst detected by an abdominal scanner. She was consulting initially in gynecologic department for a chronic isolated pelvic pain without digestive symptoms, an ultrasound exam was performed and objectified an ovary's mass and completed by an abdominal CT that showed the simultaneous presence of another mass located in the spleen recalling an hydatid cyst, the 2 exams concluded to an ovarian hydatid cyst concomitant with hydatid spleen cyst.

The patient was initially operated for the ovarian hydatid cyst in gynecology department with a realization of hysterectomy and adnexectomy, and get referred in our service to remove the spleen mass.

Physical examination: patient with GCS=0, conscious, pulse 70, respiratory rate normal, temperature 37, abdominal palpation showed painless splenomegaly.

Initially before gynecologic surgery a pelvic ultrasound was performed showing a 80mm splenic multilocular cystic mass compatible with hydatid cyst type 3 according to the classification of Gharbi, and a left annex with a multilocular image with thickest partitions.

We completed by An abdominopelvic computed tomography (CT) showed a 60 × 75 mm cyst roughly oval in shape, with partially calcified wall, with variable density content including daughter cysts with unmodified wall after contrast, originating from the spleen (Fig. 1), and a second cyst of 60 × 55 mm in size originating between the bladder and uterus (Fig. 2). We affirmed the diagnosis of concomitant splenic and ovary hydatid cysts. Positive hydatid serology has been reported and the laboratory exams show leukocytosis with eosinophilia.

Chest X ray didn't show any concomitant cysts in the lungs. Patient was kept on albendazole 400 mg oral tablet once per day for 8 weeks before the surgery, a biological follow-up was made by blood dosage of transaminases that doesn't show any abnormality.

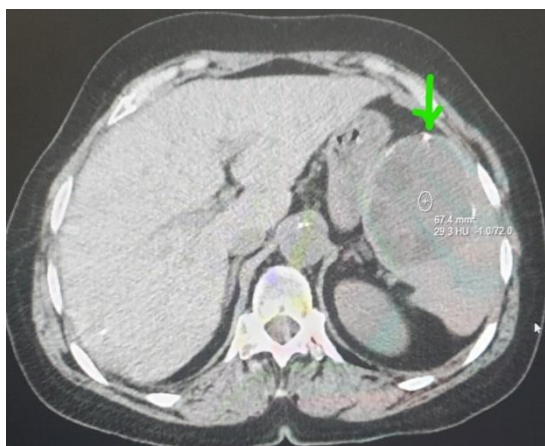


Fig-1

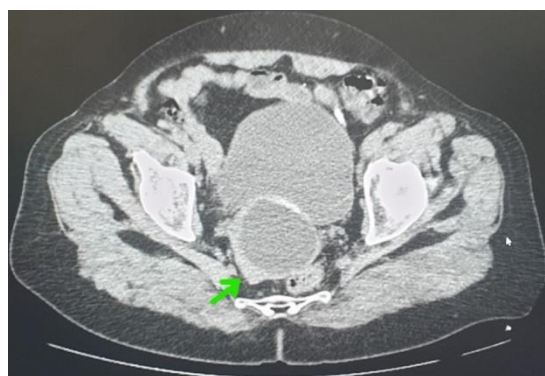

Fig-2

The laparoscopic approach was not done due to the size of the splenic cyst, and because a total splenectomy was decided.

Laparotomy was performed through a midline incision and we made protection of peritoneal tissues and organs with protoscolicide-soaked surgical drapes, the surgical exploration revealed a cyst occupying the middle part of the spleen.

Total splenectomy surgery was performed after splenic vessel ligation, the peritoneal cavity was washed locally with hypertonic saline solution (NaCl 10%), hemostasis is ensured. The macroscopic and microscopic examination of the specimen confirmed an Hydatid cyst (Fig. 3).

The postoperative follow-up is carried out without incident, The patient was fine and was sent home on the fourth postoperative day the albendazole based-treatment was started on the 7th day on postoperative for 3 months, and a vaccination was done against *S. pneumonia*, *N. meningitidis*, *H. influenzae*.

Late clinical follow-up doesn't reveal any recurrences, and now the patient does have no functional complaints.

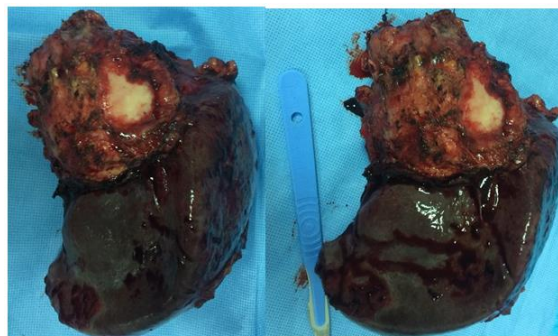


Fig-3: Splenectomy's piece with hydatid cyst

DISCUSSION

Splenic hydatid cyst is a very rare manifestation [4] and is generally asymptomatic [5, 6]. The very slow growth rate explains the long period of clinical latency [7], sometimes diagnosis is done by fortuitous discovery [8, 9] or is generally established during imaging for other causes [11,12].

Most common symptom is a left upper quadrant abdominal pain [8, 9] that can be a demonstration of a complicated hydatid cyst like rupture, or secondary infection [13, 14].

The splenic hydatid cyst can make a fistulation to adjacent organs (stomach, colon) [35, 36] and rupture into the peritoneal, retroperitoneal space [37] or pleural cavity that may cause a life-threatening by a systemic anaphylactic reaction.

A Systemic hypertension caused by the renal arterial compression may be occurred rarely, but cited in the literature [38].

Digestive manifestations may occur by the mass effect on neighboring organs and thoracic pain or dyspnea for the upper polar cysts [34].

In our case the patient was complaining by symptoms like pelvic pain related to the ovary's cyst, and the detection of the second cyst located in the spleen was done by abdominal CT, so it was asymptomatic and the imagery was determinant.

The physical examination finds a palpable mass in the left upper quadrant which is the case of our patient. Hydatid serology has a low sensitivity in the diagnosis of hydatid cysts because of its inability to differentiate between active and inactive cysts [15], but this lab test associated to radiology was useful to establish diagnosis. The combination of radiological and serological testing allows us to make diagnosis and differential diagnosis of splenic hydatid cyst [16-20].

The ultrasound is the exam of first intention to perform for splenic hydatid cyst's diagnosis. It is useful for cyst staging [16, 20] similar with that used for liver hydatid cysts: type I: purely cystic lesion; type II: germinative membrane is detached within parts of the cyst; type III: multicystic lesion separated by septae; type IV: the cyst is degenerated with a pseudo-solid appearance; type V-the pseudo-solid cyst and the ectocyst is calcified; this staging guides the therapeutic management of the cyst,

CT scan more accurately detects cyst number, size, localization, and presence of cysts in other organs. In addition, CT is preferable for monitoring of postoperative recurrences [16].

US and CT are the key for hydatid cyst diagnosis, they provide complimentary data for designing clinical management strategies. The radiological appearance of these cysts depends upon the location, the patient age, and presence of complications [16].

In our study the CT scan description of the splenic cyst is similar to that of hydatid cysts: calcification of the cyst wall, the presence of daughter cysts. While ultrasonography showed that the splenic hydatid cyst is classified stage 3.

The standard treatment is surgery, by chosen an open or laparoscopic approach [22, 23]. The choice of appropriate treatment depends on the patient's age, health condition, symptoms, and the surgeon's experiences, the size, location and the number of cysts is determining the therapy to prevent complications, eradicate echinococcosis infestation, and reduce hydatid cysts mortality and morbidity [16, 18].

The surgical treatment is based on two methods: total splenectomy and spleen-saving attitude including deroofing with omentoplasty, partial splenectomy, and pericystectomy [28, 29]. The open approach is done by a midline supraumbilical incision or a left subcostal incision particularly for the isolated splenic cyst [27].

Studies done on splenic hydatid disease are based on individual cases with low evidence to support total splenectomy or spleen preserving surgery. The surgical management of multiple and large cysts allows us to avoid rupture and its complications like anaphylaxis, bleeding and septic shock. The conservative approach is recommended when the cysts localization is peripheral [21], it consists in the removal of the entire cyst with the conservation of a part of splenic parenchyma for preserving immune functions of the spleen [24, 25], on the other side it exposes to the risk of suppuration of residual cavity (11-27%) and of recurrence (18%) [26]. We did a total splenectomy because of the size and the location of the cyst, and this

is the best treatment option for complete removal of infected tissues and avoiding potentially infected remnant cavity, bearing in mind post-splenectomy complications [21]. Splenectomy is the efficient treatment for hydatid splenic cyst in despite of the risk of post-operative sepsis that can be reduced by vaccination and the antibiotics use, related mortality reaches 1.9% in adults [30, 31].

The laparoscopic approach has been reported in literature with promising good results, it takes its place when the surgeon tries to preserve splenic tissue especially for young patients [39-40]. Albendazole therapy is recommended 1 month before and after surgery, and that for reducing the size of the hydatid cyst that make the surgical procedure easier, and finally sterilizing the disseminated protoscoleces [32, 33].

CONCLUSION

Simultaneous Splenic and ovarian hydatid cysts are rare, and especially found in endemic areas. Radiological exams and lab tests allow physicians to establish diagnosis; CT scan is the key of the diagnosis of the splenic hydatid cyst that the main management is surgery. Splenectomy is the standard surgical management in the adult patients with cysts type 3, 4, 5, albendazole is very recommended to prevent recurrences.

REFERENCES

1. Mohammed, A. A., & Arif, S. H. (2021). Hydatid cyst of the ovary—a very rare type of cystic ovarian lesion: A case report. *Case Reports in Women's Health*, e00330.
2. Nazari, F. A., Muraveji, Q., & Baset, G. Y. (2021). Primary left ovarian hydatid cyst presenting as an abdominal mass—Case report. *International Journal of Surgery Case Reports*, 85, 106230.
3. Celebi, S., Basaranoglu, M., Karaaslan, H., & Demir, A. (2006). A splenic hydatid cyst case presented with lumbar pain. *Internal Medicine*, 45(17), 1023-1024.
4. Acharya, S., Ghimire, B., & Khanal, N. (2019). Spontaneous rupture of isolated splenic hydatid cyst without acute abdomen: A case report. *Clinical case reports*, 7(11), 2064-2067.
5. Celebi, S., Basaranoglu, M., Karaaslan, H., & Demir, A. (2006). A splenic hydatid cyst case presented with lumbar pain. *Internal Medicine*, 45(17), 1023-1024.
6. Kireşi, D. A., Karabacakoğlu, A., Ödev, K., & Karaköse, S. (2003). Uncommon locations of hydatid cysts Pictorial review. *Acta Radiologica*, 44(6), 622-636.
7. Eris, C., Akbulut, S., Yildiz, M. K., Abuoglu, H., Odabasi, M., Ozkan, E., & Gunay, E. (2013). Surgical approach to splenic hydatid cyst: single center experience. *International surgery*, 98(4), 346-353.

8. Akbulut, S., Sogutcu, N., & Eris, C. (2013). Hydatid disease of the spleen: single-center experience and a brief literature review. *Journal of Gastrointestinal Surgery*, 17(10), 1784-1795.
9. Ameer, H. B., Affes, N., Abdelhedi, C., Kchaou, A., Boujelbene, S., & Beyrouiti, M. I. (2015). Hydatid cyst of the spleen: tunisian series of 21 cases. *Indian Journal of Surgery*, 77(2), 515-519.
10. Humphreys, W.G., G.W. (1979). Johnston Splenic cysts: a review of 6 cases *Br. J. Surg.*, 66; 407-408
11. Urrutia, M., Mergo, P. J., Ros, L. H., Torres, G. M., & Ros, P. R. (1996). Cystic masses of the spleen: radiologic-pathologic correlation. *Radiographics*, 16(1), 107-129.
12. Robertson, F., Leander, P., & Ekberg, O. (2001). Radiology of the spleen. *European radiology*, 11(1), 80-95.
13. Lewall, D. B. (1998). Hydatid disease: biology, pathology, imaging and classification. *Clinical radiology*, 53(12), 863-874.
14. Dahniya, M.H., Hanna, R.M., Ashebu, S., Muhtaseb, S.A., el-Beltagi, A., Badr, S. (2001). The imaging appearance of HD at some unusual sites. *Br J Radiol*, 74; 283-9.
15. Tamarozzi, F., Sako, Y., Ito, A., Piccoli, L., Grisolia, A., Itoh, S., ... & Brunetti, E. (2013). Recombinant AgB8/1 ELISA test vs. commercially available IgG ELISA test in the diagnosis of cystic echinococcosis. *Parasite immunology*, 35(12), 433-440.
16. Rasheed, K., Zargar, S. A., & Telwani, A. A. (2013). Hydatid cyst of spleen: a diagnostic challenge. *North American journal of medical sciences*, 5(1), 10.
17. Ramia-Ángel, J. M., Gasz, A., de la Plaza-Llamas, R., Quinones-Sampedro, J., & Sancho, E. (2011). Hidatidosis of the spleen. *Polski przegląd chirurgiczny*, 83(5), 271-275.
18. Vasilescu, C., Tudor, S., Popa, M., Tiron, A., & Lupescu, I. (2010). Robotic partial splenectomy for hydatid cyst of the spleen. *Langenbeck's archives of surgery*, 395(8), 1169-1174.
19. Ameer, H. B., Affes, N., Abdelhedi, C., Kchaou, A., Boujelbene, S., & Beyrouiti, M. I. (2015). Hydatid cyst of the spleen: tunisian series of 21 cases. *Indian Journal of Surgery*, 77(2), 515-519.
20. Ozogul, B., Kisaoglu, A., Atamanalp, S. S., Ozturk, G., Aydinli, B., Yildirgan, M. İ., & Kantarcı, A. M. (2015). Splenic hydatid cysts: 17 cases. *Indian Journal of Surgery*, 77(2), 257-260.
21. Meimarakis, G., Grigolia, G., Loehe, F., Jauch, K. W., & Schauer, R. J. (2009). Surgical management of splenic echinococcal disease. *European journal of medical research*, 14(4), 165-170.
22. Dar, M. A., Shah, O. J., Wani, N. A., Khan, F. A., & Shah, P. (2002). Surgical management of splenic hydatidosis. *Surgery today*, 32(3), 224-229.
23. Ozdogan, M., Baykal, A., Keskek, M., Yorgancy, K., Hamaloglu, E., & Sayek, I. (2001). Hydatid cyst of the spleen: treatment options. *International surgery*, 86(2), 122-126.
24. Sharma, A. (2016). Splenectomy or partial splenectomy should be preferred treatment for large splenic hydatid cysts. *The American journal of tropical medicine and hygiene*, 94(6), 1436-1436.
25. Costi, R., Ruiz, C. C., le Bian, A. Z., Scerrati, D., Santi, C., & Violi, V. (2015). Spleen hydatidosis treated by hemi-splenectomy: A low-morbidity, cost-effective management by a recently improved surgical technique. *International Journal of Surgery*, 20, 41-45.
26. Gharaibeh, K.I. (2001). Laparoscopic excision of splenic hydatid cyst. *Postgrad Med J*, 77; 195-196.
27. Târcoveanu, E., Bradea, C., Vasilescu, A., Georgescu, Ş., Palaghia, M., Crumpei, F., ... & Lupăşcu, C. (2018). Splenic hydatid cyst: open or laparoscopic approach?. *Jurnalul de Chirurgie*, 14(1).
28. Hoteit, A., Alimoradi, M., Aljoubaei, M., Fakhruddin, N., & Hammoud, N. (2020). Primary splenic hydatid cyst treated with laparoscopic spleen preserving surgery: A case report. *International Journal of Surgery Case Reports*, 74, 95-98.
29. Čulafić, Đ. M., Kerkez, M. D., Mijać, D. D., Lekić, N. S., Ranković, V. I., Lekić, D. D., & Đorđević, Z. L. (2010). Spleen cystic echinococcosis: clinical manifestations and treatment. *Scandinavian journal of gastroenterology*, 45(2), 186-190.
30. Belli, S., Akbulut, S., Erbay, G., & Koçer, N. E. (2014). Spontaneous giant splenic hydatid cyst rupture causing fatal anaphylactic shock: a case report and brief literature review. *Turk J Gastroenterol*, 25(1), 88-91.
31. Rasheed, K., Zargar, S. A., & Telwani, A. A. (2013). Hydatid cyst of spleen: a diagnostic challenge. *North American journal of medical sciences*, 5(1), 10.
32. Ozogul, B., Kisaoglu, A., Atamanalp, S. S., Ozturk, G., Aydinli, B., Yildirgan, M. İ., & Kantarcı, A. M. (2015). Splenic hydatid cysts: 17 cases. *Indian Journal of Surgery*, 77(2), 257-260.
33. Atmatzidis, K., Papaziogas, B., Mirelis, C., Pavlidis, T., & Papaziogas, T. (2003). Splenectomy versus spleen-preserving surgery for splenic echinococcosis. *Digestive Surgery*, 20(6), 527-531.
34. Kismet, K., Ozcan, A. H., Sabuncuoglu, M. Z., Gencay, C., Kilicoglu, B., Turan, C., & Akkus, M. A. (2006). A rare case: spontaneous cutaneous fistula of infected splenic hydatid cyst. *World Journal of Gastroenterology: WJG*, 12(16), 2633.
35. Teke, Z., Yagci, A. B., Atalay, A. O., & Kabay, B. (2008). Splenic hydatid cyst perforating into the colon manifesting as acute massive lower gastrointestinal bleeding: an unusual presentation of disseminated abdominal echinococcosis. *Singapore Med J*, 49(5), e113-e116.

36. Ouafdel, J., Bougtab, A., Amraoui, A., Fikri-O, K., Assem, A., & Elallame, L. (1988). Kyste hydatique de la rate rompu dans l'estomac. *Médecine du Maghreb*, 26, 7-10.
37. Hidatigi, R. T. D. K. (2010). Splenic hydatid cyst attacking retroperitoneum. *Turkiye Parazitoloj Derg*, 34, 193-5.
38. Kantarçeken, B., Çetinkaya, A., Bülbüloğlu, E., & Demirpolat, G. (2010). Splenic hydatid cyst as a cause of sinistral portal hypertension and isolated gastric variceal bleeding. *The Turkish journal of gastroenterology: the official journal of Turkish Society of Gastroenterology*, 21(3), 317-320.
39. Arce, M. A., Limaylla, H., Valcarcel, M., Garcia, H. H., & Santivañez, S. J. (2016). Case Report: Primary Giant Splenic Echinococcal Cyst Treated by Laparoscopy. *The American journal of tropical medicine and hygiene*, 94(1), 161.
40. Diaconescu, M. R., Glod, M., Costea, I., Ciolpan, C., & Georgescu, S. (2008). Laparoscopic hand-assisted splenectomy for hydatid cyst. *Chirurgia (Bucharest, Romania: 1990)*, 103(1), 103-106.