

Vitamin D Deficiency Investigation in Oncologic Patient Undergoing Surgical Management of Medication Related Osteonecrosis of the Jaw: A Clinical Prospective Study

Dhekra Jlassi^{1,3*}, Nour Saida Ben Messaoud^{1, 2, 3}, Ghada Bouslama^{1,2,3}, Aya Mtiri^{1, 3}, Souha Ben Youssef^{1,2,3}, Abdellatif Boughzela^{1,2,3}

¹Oral Surgery Unit, Dental Medicine Department in University Hospital Farhat Hached, Sousse, Tunisia

²Research Laboratory: LR 12SP10: Functional and Aesthetic Rehabilitation of Maxillary, Tunisia

³University of Monastir, Faculty of Dental Medicine, 5019 Monastir, Tunisia

DOI: [10.36347/sasjs.2021.v07i11.010](https://doi.org/10.36347/sasjs.2021.v07i11.010)

| Received: 14.09.2021 | Accepted: 16.10.2021 | Published: 18.11.2021

*Corresponding author: Dhekra Jlassi

Abstract

Original Research Article

Medication-related osteonecrosis of the jaw (MRONJ) is defined as an area of exposed bone, or bone that can be probed through an intraoral or extraoral fistula persisted for greater than 8 weeks in patient with current or previous treatment with bisphosphonates, denosumab, or antiangiogenic therapy without history of radiation therapy to the jaw or obvious metastatic disease of the jaw. The physiopathology remains a controversial subject including the possible involvement of vitamin D deficiency. **Purpose:** discuss the involvement of vitamin D deficiency in MRONJ development. This through a series of five clinical cases and a review of the literature. **Observations:** A series of 5 clinical cases of MRONJ associated with vitamin D deficiency whose management was medico-surgical were included. The series included 2 women and 3 men of average age 54,8 years who were treated for malignant diseases and whose average serum vitamin D level was 10 ng / ml. Remission was complete in 4 cases and partial in 1 case. **Discussion:** Several epidemiological studies have shown a high prevalence of hypovitaminosis D in different apparently healthy populations. Moreover, Vitamin D deficiency has recently been incriminated as an added risk factor for MRONJ. It has been postulated through experimental and control case studies that systemic conditions associated with cancer patients with a vitamin D deficiency combined with tooth extraction may increase the risk of MRONJ. **Conclusion:** MRONJ is a known complication of Bisphosphonate. Additional processes would be involved in the genesis of MRONJ including the possible role of a vitamin D deficiency but the scientific evidence of their involvement is not yet fully characterized.

Keywords: Vitamin D, Oncologic Patient, Xtraoral, Denosumab, Hypovitaminosis.

Copyright © 2021 The Author(s): This is an open-access article distributed under the terms of the Creative Commons Attribution 4.0 International License (CC BY-NC 4.0) which permits unrestricted use, distribution, and reproduction in any medium for non-commercial use provided the original author and source are credited.

INTRODUCTION

MRONJ Medication-related osteonecrosis of the jaw (MRONJ) is defined as an area of exposed bone, or bone that can be probed through an intraoral or extraoral fistula persisted for greater than 8 weeks in patient with current or previous treatment with bisphosphonates, denosumab, or antiangiogenic therapy without history of radiation therapy to the jaw or obvious metastatic disease of the jaw [1]. Although the first case of MRONJ was reported over ten years ago by Marx, the pathophysiology of the disease has not been fully elucidated. This is explained by the persistence of missing links including the possible implication of a vitamin D deficiency.

Vitamin D (1, 25-(OH) 2D3) is a secosteroid whose well-known function is the maintenance of bones

and calcium/phosphorous homeostasis [2]. However, apart from these traditional roles, several other biological functions of vitamin D such as regulation of cellular proliferation and differentiation, apoptosis, immune modulation and Inhibition of tumor angiogenesis are increasingly recognized [2].

Since the major source of vitamin D is UVB radiation-induced photochemical and thermal conversion of 7-dehydrocholesterol in the skin [3], the main risk factors for developing hypovitaminosis D include lack of sun exposure and dark skin pigmentation [4]. Vitamin D deficiency and insufficiency has been found to be associated with multiple myeloma (MM), breast cancer and prostate cancer in several recent studies [5]. However, the implication of vitamin D status in MRONJ patients

has not been well established.

The purpose of this work was to discuss the involvement of vitamin D deficiency in MRONJ development through five clinical cases series and a review of the literature

MATERIALS AND METHODS

Study design: A prospective clinical study was carried out in oral medicine, oral surgery departement at Farahat Hached Hospital Sousse-Tunisia between 2018-2019. A totally of 6 patients were enrolled and followed up.

The inclusion criteria were: Patients diagnosed with MRONJ according to the American Association of Oral and Maxillofacial Surgeons (AAOMS) criteria [1], mandibular localization, patients treated for malignant diseases.

The exclusion criterion was: contraindications for Surgical Treatment and lack of follow-up. In order to achieve diagnosis clinical and radiological examinations were performed. All patients were evaluated and treated by the same oral surgeon.

Study variables

The variables were divided into demographic, clinical data, and treatment modality. Demographic variables included gender, age at diagnosis, primary disease that led to antiresorptive medications (breast cancer, multiple myeloma...), drug used, route of administration, length of administration, time of discontinuation of antiresorptive medication, others comorbidities.

Clinical data included diagnosis date, first symptom, anatomic location, triggering factor and disease stage at diagnosis determined by the AAOMS staging criteria. We used a single clinical laboratory to measure the serum levels of vitamin D (25-OHD).

Treatment was made according to AAOMS guidelines, Treatment strategy consisted of:

- Full mouth scaling, a one-week preoperative oral rinse with a 12% chlorhexidine mouthwash.
- Conservative treatment modality included: three-month antibiotic therapy: 1 month on preoperative and 2 months on postoperative, systemic administration of tocopherol 400mg and pentoxifylline 800mg prescription for 3 months.
- Surgical debridement approach to remove necrotic bone under local anesthesia.
- follow up at least for one year

Remission was considered achieved if complete healing of mucosa over the exposed bone had occurred with inflammatory and infectious signs relief, Remission was considered partial if the clinical symptoms have disappeared and the exposed bone area

was reduced.

Additionally, we examined the rate and the mean duration of vitamin D substitution prescribed by the oncologist after diagnosis of vit D deficiency.

RESULTS

From 2018 to 2019; a total of 5 patients: 2 woman and 3 men were selected and treated in our department, with the mean age at diagnosis of 54, 8. MRONJ developed under malignant disease in all patients: 2 patients were diagnosed with osseous metastasis from breast cancer and 1 with osseous metastasis from prostate cancer, 2 patients presented a multiple myeloma. The used drug was intravenously Zolendronic acid, the mean number of injection was 21.4, the mean length of administration was 26,6 months.

MRONJ development was triggered by tooth extraction in posterior mandibular area in four patients and spontaneous MRONJ in one case. Stage I, II AND III of MRONJ were confirmed in 1, 3 and 1 patients respectively.

In the 5 clinical cases presented, the dosages of vitamin D were made by assaying the reserve form: 25 (OH) D according to the CLIA technique (chemiluminescence immunological assay). The mean serum level of vitamin d was 11,2 ng/ml. All patients, both deficient and severe deficient, were offered Vit D supplementation by their oncologist, the average monthly dose of vitamin substitution was 1.2 ampoule (200.000IU); The mean duration of vitamin D substitution was 4 months.

To manage infection, one-month preoperative antibiotics were prescribed for all patients based on 2g amoxicillin and 1.5g metronidazole daily, 2 months on postoperative based on 2g amoxicillin daily.

Removal of the sequestrum and necrotic bone basing on tetracycline fluorescence guided surgery was performed for three patients (figure 1), superficial debridement of exposed bone was performed for one patient (figure 2).

4 patients had achieved complete remission; however, 1 patient had achieved partial remission. A summary of clinical, demographic and treatment variables are present in the table 1.

DISCUSSION

Sufficient concentration of Vit D is essential for regulation of a large number of physiological functions especially physiological regulations of Calcium Homeostasis and Bone Metabolism. The hardness and rigidity of bone is maintained through self-renew [6]. Bone tissue is continuously remodeled through the actions of osteoblasts, osteocytes, osteoclasts, and bone lining cells [7]. The activity of

these cells is controlled by various local and systemic factors, local factors such as growth factors, cytokines, and prostaglandins and systemic factors which are the major hormonal regulators of bone homeostasis, include parathyroid hormone (PTH), calcitonin, 1,25-dihydroxyvitamin D₃ (calcitriol), glucocorticoids, androgens, and estrogens. [8]. Vitamin D and its metabolites plays an essential role in the control of body calcium homeostasis. The goal of this control is to maintain serum calcium levels of about 10 mg/dL. To achieve this goal parathyroid hormone is secreted when the serum level of calcium is low. It helps regulate the level of blood calcium by: triggering the formation of calcitriol, which is the major stimulator of active intestinal calcium absorption [9], increases the amount of calcium resorbed by the kidneys from the urine and stimulates resorption of bone by osteoclasts. This demineralization process releases calcium into the blood stream [10].

Vitamin D is available in two major forms [3]: D₂ (ergocalciferol): mainly comes from plant sources and vitamin D₃ (cholecalciferol): is synthesized in the skin and occurs naturally in some animal-based foods. Thus, the major cause of vitamin D deficiency is the lack of sun exposure and malnutrition. The importance of the production of pre-vitamin D₃ is dependent to the intensity of sun exposure, skin pigmentation that absorbing ultraviolet light, thus reducing vitamin D production and epidermal concentration of Dihydroxycholesterol which decreases with age [11].

We documented a significantly Vitamin D deficiency in all patients included in this study, this may be due to the lack of sun exposure because of religious or cultural tradition, mainly the wear of skin-covering clothes. Also advanced age of our patients with a darker skin and a risk of malnutrition related to cancer treatment protocols may be involved in vitamin D deficiency.

The pathogenesis of MRONJ is not fully elucidated yet. According to current scientific evidence there are three major theories to explain the pathophysiology of MRONJ: the inhibition of osteoclasts, the inhibition of angiogenesis and the processes of inflammation-infection. Vitamin D can play a potential role in these three etiological pathways of MRONJ [1].

Effect of vitamin D on osteoclast activity: The result of an experimental study using animal model for MRONJ proved that vitamin D could reduce the inhibitory effects of BPs on osteoclasts activity [5].

Vitamin D and Angiogenesis: New recent studies support the important role of the active form of vitamin D 1, 25(OH) 2D₃ as a regulator of angiogenesis and vascular function. The positive

effect of vitamin D supplementation was observed in a larger number of diseases related to angiogenesis [12].

Role of vitamin D in inflammation and infection: Inflammation play a crucial role in the pathogenesis of MRONJ [13]. Clinical trials have proved that there's a link between vitamin D and inflammatory ratios generated by BPs, indeed it is suggested that vitamin D combined with BPs therapy significantly reduce systemic inflammation markers [5]. In fact, vitamin D is a key modulator of inflammation by reducing the presence of proinflammatory cytokines such as interleukin-1 (IL-1) and interleukin-6 (IL-6) and tumor necrosis factor-alpha (TNF- α) [14].

Bacterial species associated with periodontal disease is a local risk factor for MRONJ and it has been proven that certain bacteria are attenuated by vitamin D such as *Porphyromonasgingivalis*, *Aggregatibacter actinomycetemcomitans* [15].

The patients included in our study were all treated for malignant disease, vitamin D deficiency appear to be quite common in high-risk MRONJ patients. Patients with multiple myeloma showed a high prevalence of vitamin D deficiency in two recent studies. In 2017 A comparative cross-sectional study design was conducted by Aydinli F [16] including 31 newly diagnosed and followed up MM patients. Insufficiency vit D was diagnosed in 93% of patients (20 of 33 cases) and the mean vit-D level was 11.9 \pm 7.6ng/ml. The vit D level was significantly lower in cases whom a greater number of chemotherapy cycles and advanced stage of the disease was administered (p=0.033). Also, in 2016 Wang performed a cross-sectional study [17] of 111 MM patients who had received bortezomib and / or thalidomide for at least 12 weeks, Overall, patients had a median serum 25D level of only 32 ng/ml, the 25 (OH) D level was insufficient in 42% of patients (47/111) with 16% of patients (18/111) presenting a 25 (OH) D level <20ng / ml.

However, there is no clear consensus on the assessment and management of vitamin D insufficiency in cancer patients treated with BPs like our patients who have all been treated with zoledronic acid. The benefit of treatment may be attenuated by concomitant vitamin D deficiency associated with inadequate calcium supply; the administration of BPs mainly intravenous zoledronic acid without supplementation in vitamin D can cause hypomagnesemia and hypocalcemia [18]. Severe hypocalcemia may result in severe symptoms; seizures, tetany and disorder of bone remodeling. Vitamin D deficiency and hypocalcemia may contribute to the secondary hyperparathyroidism. Hyperparathyroidism effects may interfere with the effectiveness of BPs; as parathyroid hormone is a potent stimulant of osteoclast activity [19, 20].

Research was performed to evaluate the impact of vitamin D deficiency on the development of BRONJ, to our knowledge; three case-control studies and two experimental studies have been published [5], [21-24]. For clarity, the table 2 summarizes details of these studies.

In accordance with the literature, our findings showed the involvement of vitamin D deficiency on the development of BRONJ, however the scientific evidence of its involvement is not yet fully established. This may be due to the significant variability between different assays and laboratories for the measurement of vitamin D levels. This variability in vitamin D assays has a significant impact on patient classification and treatment recommendations. It also renders universal assay standardization a pressing call. For now, the 25(OH) D molecule is the major circulating form of vitamin D, it has a half-life of three weeks while 1, 25(OH) 2D has a half-life of only a few hours. Thus, the serum 25(OH) D level is currently considered the best indicator of vitamin D [25]. Even though the level of vitamin D reserves might not be adequate to define the active form of vitamin D.

The recommended level of optimal circulating 25(OH)D concentrations remain widely debated [26]. Indeed, the reference values are significantly variable depending on the approach used to determine them: PTH level, Calcemia, or bone mineral density. Currently a level of at least 30 ng/ml 25(OH)D is considered as sufficient [26], values between 29 and 20

ng/ml as insufficiency, levels less than 20 ng/ml as deficiency and levels below 7 ng/ml as severe deficiency [27]. Recent evidence clarifies that serum 25(OH)D levels should be interpreted with PTH levels. Which physiologically defines hypovitaminosis D as the concentration of 25(OH) D at which parathyroid hormone (PTH) start increasing [28].

Other than the necessity of single universal thresholds enabling possible comparisons across patients, the lack of studies is in favor of not finding a causal link between vitamin D deficiency and BRONJ pathophysiology. Mainly a matched case control studies conducted in BRONJ + and BRONJ - patients treated with bisphosphonates and matched by sex and age which are known to influence 25-OH-D, also adequate matching for factors influencing bone metabolism such as type of cancer and drug treatment is required.

CONCLUSION

It has been postulated through experimental and control case studies that systemic conditions associated with cancer patients with a vitamin D deficiency combined with tooth extraction may increase the risk of MRONJ. Moreover, Vitamin D deficiency has recently been incriminated as an added risk factor for MRONJ, but the scientific evidence of their involvement is not yet fully characterized. Nevertheless, a multicenter studies with larger number of BRONJ patients should be conducted to prove causal relationship.

Table-1

Age and gender	Medical history	Bisphosphonate Therapy	Aetiology of MRONJ	Stage and location of MRONJ	Vitamin D level VitaminD substitution	Surgical Management	Remission	Stage after treatment
J.SG Man, 56years	Hypertension Multiple myeloma	24 Zoledronic acid injections The mean length of administration was 24 months	Tooth extraction	Stage II MRONJ in the posterior mandible region	14.6ng / ml (deficiency) Substitution: 1 ampoule (200.000 UI) monthly for 4 months	Fluorescence-guided bone curettage using piezo inserts Use of Platelet rich fibrin (PRF) to promote healing	Complete remission after 6 months -Vitamin D Control: 35,4ng/ml.	Stage 0

Men, 44-year-old	OH Women, 56 years old	S.H Women, 53 years	A.H Man, 65 years
Multiple myeloma	breast cancer metastatic to bone	mammary adenocarcinoma bone metastases heart failure due to chemotherapy	Diabetes Hypertension Prostatic adenocarcinoma with bone metastases
18 zoledronate acid injections the mean length of administration was 18 months	10 Zoledronic acid injections the mean length of administration was 30 months	25 Zoledronic acid injections The mean length of administration was 25 months	30 Zoledronic acid injections The mean length of administration was 36 months
spontaneous MRONJ	Tooth extraction	Tooth extraction	Tooth extraction
stage III MRONJ in the posterior mandible region	stage II MRONJ in the posterior mandible region	Stage I, MRONJ in the posterior mandible region	stage II MRONJ in the posterior mandible region
16ng/ml (deficiency) Substitution: 1 ampoule (200.000 UI) monthly for 4 months	5ng/ml (severe deficiency) Substitution: 2 ampoule (200.000 UI) monthly for 4 months	10.3ng/ml (deficiency) Substitution: 1 ampoule (200.000 UI) monthly for 4 months	10.1ng/ml (deficiency) Substitution: 1 ampoule (200.000 UI) monthly for 4 months
fluorescence guided surgery Sequestrectomy Use of both combined Platelet rich fibrin (PRF) and free buccal fat pad graft fixation	fluorescence-guided bone curettage Platelet-rich fibrin application and both periosteal and transmucosal sutures	Sequestrectomy Superficial debridement of exposed bone	both periosteal and transmucosal sutures to prevent post-operative bone exposure
Complete remission after 6 months	Complete remission After 3 months	Complete remission after 6 months -Vitamin D Control: 25,4ng/ml.	Partial remission after 3 months -The patient was lost to follow-up
Stage 0	Stage 0	Stage 0	Stage 1

Table-2

Author and year of publication	Type of study	Objectives	Material and methods	Results	Critical component Biases and Confounding
Saim Yank2016 "Histopathological features of bisphosphonates related osteonecrosis of the jaw in rats with and without vitamin D supplementation" (5)	Experimental study performed in rats	To investigate the effect of vitamin-D3 supplementation on induced bisphosphonates related osteonecrosis of the jaw	80 RATS were divided into four groups: -Dexamethasone was administered to induce osteoporosis -Zoledronic acid was administered twice per week over the course of 7 weeks -Dental extraction was performed by drilling around the tooth at 7th week * In study-group-1: vitamin-D was administered Vitamin D was administered in preoperative just before surgical tooth extraction. *In study-group-2 (Vit.D + post.): Vitamin D was administered in postoperative, just after surgical tooth extraction. *In Study group 3 (Vit.D + OCNM +): Vitamin D was administered after development of MRONJ. * Control group (Vit.D-): the animals did not receive any vitamin	- The control- group had a significantly lower osteoclast number than the preoperative- (p = 0.010) and postoperative (p = 0.026) groups - Macroscopic osteonecrosis was significantly higher in the control group than the osteonecrosis group (p = 0.011).	Results from animal experimental studies are imprecise comparing to clinical studies.
Akishige Hokugo 2010 "Increased prevalence of bisphosphonate related osteonecrosis of the jaw(ONJ) with vitamin D deficiency in rats." (23)	Experimental study performed in rats	The objective of this study was to establish an animal model of bisphosphonate-related ONJ by testing the combination of these risk factors: intravenous injection of zoledronate; maxillary molar extraction, and vitamin D deficiency	10 rats were divided on four groups: -Vit.D (-) / ZOL: Induction of a vitamin D deficiency and administration of a bolus of zoledronate every 2 weeks. - ZOL: an intravenous injection of a bolus of zoledronate - Vit.D (-): induction of vitamin D deficiency without administration of zoledronate - Control group: an intravenous injection of vehicle solution (0.9% NaCl) - Maxillary left molar teeth were extracted from all groups at 3 weeks after initiating the treatment. - Then 1, 2, 4, and 8 weeks after tooth extraction, maxillae were harvested from the control	ONJ lesions were most prevalent in the VitD(-)/ZOL group (66.7%; four positive rats of six total rats), followed by the ZOL group (14.3%; one of seven). None of animals in the control (n = 9) and VitD(-) (n = 7) groups developed ONJ lesions The Fisher exact test indicated that ONJ prevalence in the VitD(-)/ZOL group was significantly greater than in all other groups (p < .05)	Sample size determination is not mentioned Imprecise results from animal research

Author and year of publication	Type of study	Objectives	Material and methods	Results	Critical component Biases and Confounding
Nils Heim and al. 2017 "Vitamin D deficiency may increase the prevalence of Medication related osteonecrosis of the jaw "(21)	Case-control study	To investigate vitamin D deficiency as a risk factor for MRONJ	63 patients who received antiresorptive medication were divided into two groups: - One group (n=45); consisted of patients who presented a stage 2 ONJ - Second group (patients (n=18) with no exposed bone. -Serum levels of vitamin D (25-OHD) were analyzed. -The t test was used to compare the 2 groups	- Serum levels of 25-OHD were significantly higher in the MRONJ (-) group (29.5 ng/ml), than in the MRONJ (+) group (20.49 ng/ml). - Blood levels of calcium were also significantly higher in MRONJ (-) group (2.25 mmol/L; 0.11 SD) than in MRONJ (+) group (2.175 mmol/L; 0.16 SD).	Selection bias: -heterogeneous patients' repartition: * MRONJ +: 80% of patients (36/45) patients treated for malignant diseases * MRONJ-: 55.5% of patients (10/18) treated for osteoporosis
ALBERTO BEDOGNI ,2012 "ostéomalacia: the missing Link in the Pathogenesis is of Bisphosphon ate-Related Osteonecrosis s of the Jaw" (22)	Case-control study To reveal static and dynamic histomorphometric evidence of osteomalacia in biopsies from patients with and without BRONJ	To reveal static and dynamic histomorphometric evidence of osteomalacia in biopsies from patients with and without BRONJ	-43 patients received treatment with BPs, were divided into two subgroups: * Study group (n = 22) (OCNM +): patients with BRONJ * Control group (n = 21) (OCNM-): patients without BRONJ - bone biopsies were performed from jaws. - Biopsies with evidence of osteomyelitis or necrosis at histology were excluded from the study - Osteomalacia was defined as a mineralization lag time >100 days, a corrected mean osteoid thickness >12.5 mm, and an osteoid volume >10%.	According to histomorphometry, 77% of patients with BRONJ were osteomalacic compared with 5% of patients without BRONJ,	Confusion bias: the lack of matching on vitamin D deficiency factors (clothing style; age; sex; average duration of daily sunlight exposure)
Alberto Bedogni 2019 "Is vitamin D deficiency a risk factor for osteonecrosis of the jaw in patients with cancer? A matched casecontrol study"(24)	A matched case control study	to investigate vitamin D deficiency as a risk factor for BRONJ cancer patients.	A total of 51 BRONJ + patients and 73 BRONJ - treated with bisphosphonates were matched by sex (same) and age (within 5 years). Serum 25-hydroxy-vitamin D (25-OH-D), parathyroid hormone, bone alkaline phosphatase. vitamin D deficiency defined as 25-OH-D < 50 nmol/l	A total of 51 BRONJ + and 73 BRONJ - patients were studied. The frequency (95% CI) of vitamin D deficiency was 59%(45%e72%) in BRONJ +and 62%(48%e75%) in BRONJ - patients. This amounts to a difference of 3% (22%e16%, p ¼ 0.77) for BRONJ+ patients. Serum 25-hydroxy-vitamin D and parathyroid hormone were similar in BRONJ- and BRONJ+ patients. vitamin D deficiency is not a risk factor for BRONJ	the relatively low number of studied patients.

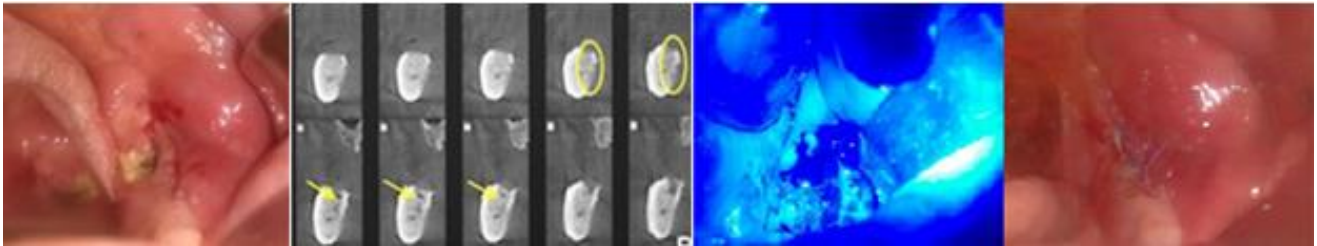


Fig-1: A: Intra oral examination revealed: unhealed extraction socket with the presence of exposed bone persistent for two months, B: oblique-coronal sections: Erosion of the lingual cortex and beginning formation of a sequestrum on the lingual side, C and D: Fluorescence-guided bone surgery to distinguish necrotic and viable bone.

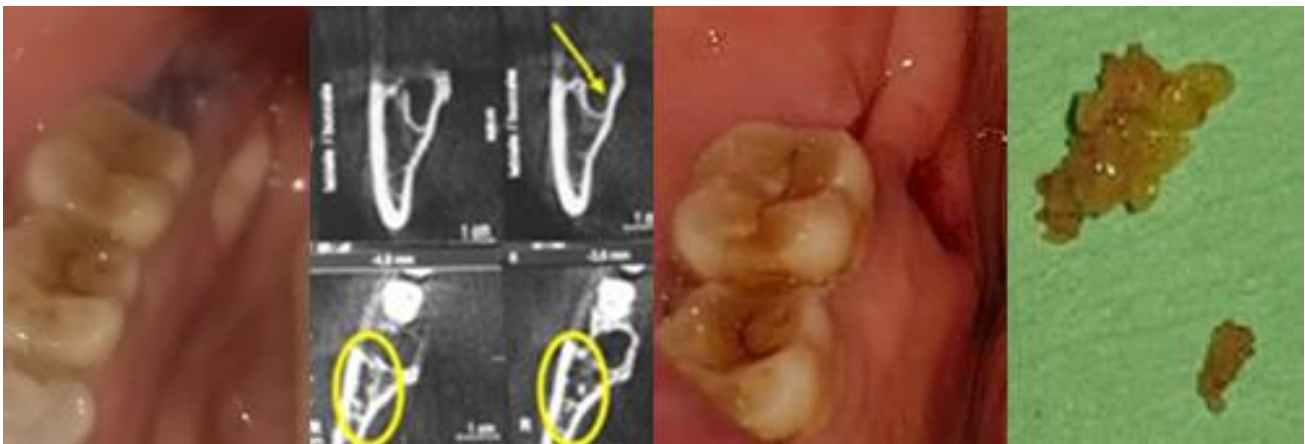

Fig-2: a: asymptomatic exposed bone in the lingual cortex after two months of the molar 48 extraction, b: oblique-coronal sections: a: osteosclerosis of the alveolar walls; distal abnormal bony trabeculae appearance with enlargement of the mandibular canal, c: conservative debridement of sequestrum bone

REFERENCE

1. Wat, W. Z. M. (2016). Current controversies on the pathogenesis of medication-related osteonecrosis of the jaw. *Dentistry journal*, 4(4), 38.
2. Umar, M., Sastry, K. S., & Chouchane, A. I. (2018). Role of vitamin D beyond the skeletal function: a review of the molecular and clinical studies. *International journal of molecular sciences*, 19(6), 1618.
3. Del Valle, H. B., Yaktine, A. L., Taylor, C. L., & Ross, A. C. (Eds.). (2011). Dietary reference intakes for calcium and vitamin D.
4. Arabi, A., El Rassi, R., & Fuleihan, G. E. H. (2010). Hypovitaminosis D in developing countries—prevalence, risk factors and outcomes. *Nature Reviews Endocrinology*, 6(10), 550-561.
5. Yanik, S., Aras, M. H., Erkiş, S., Bozdağ, Z., Demir, T., & Çetiner, S. (2016). Histopathological features of bisphosphonates related osteonecrosis of the jaw in rats with and without vitamin d supplementation. *Archives of oral biology*, 65, 59-65.
6. Weatherholt, A. M., Fuchs, R. K., & Warden, S. J. (2012). Specialized connective tissue: bone, the structural framework of the upper extremity. *Journal of Hand Therapy*, 25(2), 123-132.
7. Upadhyay, R.K. (2017). Role of Calcium Bio-Minerals in Regenerative Medicine and Tissue Engineering. *J Stem Cell Res Ther*, 2(6): 00081.
8. Florencio-Silva, R., Sasso, G. R. D. S., Sasso-Cerri, E., Simões, M. J., & Cerri, P. S. (2015). Biology of bone tissue: structure, function, and factors that influence bone cells. *BioMed research international*, 2015.
9. Christakos, S., Dhawan, P., Porta, A., Mady, L. J., & Seth, T. (2011). Vitamin D and intestinal calcium absorption. *Molecular and cellular endocrinology*, 347(1-2), 25-29.
10. Drake, T.M., Gupta, V. (2020). Calcium. 2020 Oct 5. In: StatPearls [Internet]. Treasure Island (FL): StatPearls Publishing; 2020 Jan-.
11. Bikle, D. (2015). Vitamin D: production, metabolism, and mechanisms of action.
12. Lappe, J., Watson, P., Travers-Gustafson, D., Recker, R., Garland, C., Gorham, E., ... & McDonnell, S. L. (2017). Effect of vitamin D and calcium supplementation on cancer incidence in older women: a randomized clinical trial. *Jama*, 317(12), 1234-1243.
13. Cannell, J. J., Grant, W. B., & Holick, M. F. (2014). Vitamin D and inflammation. *Dermato-endocrinology*, 6(1), e983401.
14. Lorenzo-Pouso, A. I., Pérez-Sayáns, M., García, A., & Carballo, J. (2018). Vitamin D

- supplementation: Hypothetical effect on medication-related osteonecrosis of the jaw. *Medical hypotheses*, 116, 79-83.
15. Li, H., Li, B., Wang, Q., Xiao, Y., Chen, X. M., & Li, W. (2014). Attenuation of inflammatory response by 25-hydroxyvitamin D3-loaded polylactic acid microspheres in treatment of periodontitis in diabetic rats. *The Chinese journal of dental research: the official journal of the Scientific Section of the Chinese Stomatological Association (CSA)*, 17(2), 91-98.
 16. Yokuş, O., Hilmi, D. M., Aydinli, F., Eren, R., & Altindal, S. (2017). Vitamin D deficiency and its effects on patients with multiple myeloma. *Hematol Transfus Int J*, 5(2), 00112.
 17. Wang, J., Udd, K. A., Vidisheva, A., Swift, R. A., Spektor, T. M., Bravin, E., ... & Berenson, J. R. (2016). Low serum vitamin D occurs commonly among multiple myeloma patients treated with bortezomib and/or thalidomide and is associated with severe neuropathy. *Supportive Care in Cancer*, 24(7), 3105-3110.
 18. Gröber, U., Holick, M.F., Kisters, K. (2011). Vitamin D and drugs. *Med Monatsschr Pharm*, 34; 377-87.
 19. Berruti, A., Dogliotti, L., Tampellini, M., Lipton, A., Hirsh, V., Saad, F., ... & Hei, Y. L. (2006). Effect of zoledronic acid (Z) treatment based on serum parathyroid hormone (PTH) levels in patients (pts) with malignant bone disease. *Journal of Clinical Oncology*, 24(18_suppl), 8610-8610.
 20. Carmel, A. S., Shieh, A., Bang, H., & Bockman, R. S. (2012). The 25 (OH) D level needed to maintain a favorable bisphosphonate response is ≥ 33 ng/ml. *Osteoporosis International*, 23(10), 2479-2487.
 21. Heim, N., Warwas, F. B., Wilms, C. T., Reich, R. H., & Martini, M. (2017). Vitamin D (25-OHD) deficiency may increase the prevalence of medication-related osteonecrosis of the jaw. *Journal of Cranio-Maxillofacial Surgery*, 45(12), 2068-2074.
 22. Bedogni, A., Saia, G., Bettini, G., Tronchet, A., Totola, A., Bedogni, G., ... & Dalle Carbonare, L. (2012). Osteomalacia: the missing link in the pathogenesis of bisphosphonate-related osteonecrosis of the jaws?. *The oncologist*, 17(8), 1114.
 23. Hokugo, A., Christensen, R., Chung, E. M., Sung, E. C., Felsenfeld, A. L., Sayre, J. W., ... & Nishimura, I. (2010). Increased prevalence of bisphosphonate-related osteonecrosis of the jaw with vitamin D deficiency in rats. *Journal of bone and mineral research*, 25(6), 1337-1349.
 24. Bedogni, A., Bettini, G., Bedogni, G., Basso, D., Gatti, D., Valisena, S., ... & Bertoldo, F. (2019). Is vitamin D deficiency a risk factor for osteonecrosis of the jaw in patients with cancer? A matched case-control study. *Journal of Cranio-Maxillofacial Surgery*, 47(8), 1203-1208.
 25. Ha Cam Thuy Nguyen. Vitamin D3 25-Hydroxyvitamin D. Department of Endocrinology, University of Pittsburgh Medical Center. Medscape
 26. Khajavi, A., & Amirhakimi, G. H. (1977). The rachitic lung: pulmonary findings in 30 infants and children with malnutritional rickets. *Clinical pediatrics*, 16(1), 36-38.
 27. Ringe, J. D., & Kipshoven, C. (2012). Vitamin D-insufficiency: An estimate of the situation in Germany. *Dermato-endocrinology*, 4(1), 72-80.
 28. Wang, W. H., Chen, L. W., Lee, C. C., Sun, C. Y., Shyu, Y. C., Hsu, H. R., ... & Wu, I. W. (2017). Association between parathyroid hormone, 25 (OH) vitamin D, and chronic kidney disease: a population-based study. *BioMed research international*.