

## Reliability of Clinical Examination and Ultrasonography for the Assessment of Axillary Lymph Node Status in Breast Cancer Patients in Bangladesh

Dr. Azizur Rahman<sup>1\*</sup>, Dr. K M Shaiful Islam<sup>2</sup>, Dr. Md. Mamun Morshed<sup>3</sup>, Dr. Shahnewas<sup>4</sup>, Dr. Nahida Afroz Shuma<sup>5</sup>  
Dr. Md. Russell<sup>6</sup>

<sup>1</sup>Specialist Surgeon, United Hospital Limited, Dhaka, Bangladesh

<sup>2</sup>Resident Surgeon (RS), Dept. of Pediatric Surgery, Dhaka Medical College Hospital, Dhaka, Bangladesh

<sup>3</sup>Consultant, Dept. of Anaesthesia Analgesia & Intensive Care Medicine, Bangabandhu Sheikh Mujib Medical University, Dhaka, Bangladesh

<sup>4</sup>Assistant Register, National Institute of Traumatology, Orthopedics & Rehabilitation (NITOR), Dhaka, Bangladesh

<sup>5</sup>Medical Officer, Oncology Unit, Delta Hospital Limited, Darussalam, Mirpur-1, Dhaka, Bangladesh

<sup>6</sup>Associate Professor of Surgical Oncology, Dept. of Surgery, Bangabandhu Sheikh Mujib Medical University, Dhaka, Bangladesh

DOI: [10.36347/sasjs.2021.v07i11.014](https://doi.org/10.36347/sasjs.2021.v07i11.014)

| Received: 20.10.2021 | Accepted: 23.11.2021 | Published: 25.11.2021

\*Corresponding author: Dr. Azizur Rahman

E-Mail ID: [aziz42rahman@gmail.com](mailto:aziz42rahman@gmail.com)

### Abstract

### Original Research Article

**Background:** In the treatment arena of oncology, there has been growing interests in developing the clinical prediction tools to estimate the risk and severity of patients with breast cancer having axillary nodal metastases. Clinical examination and ultrasonography (USG) for the assessment of axillary lymph node status in breast cancer patients is a traditional diagnostic method in detecting breast cancer and its status. But we have very limited research-based data regarding the effectiveness of clinical examination and USG for the assessment of axillary lymph node status in breast cancer patients. **Aim of the study:** The aim of this study was to assess the reliability of clinical examination and ultrasonography for the assessment of axillary lymph node status in breast cancer patients. **Methods:** This was a prospective observational study conducted in the Department Surgery & Oncology, Dhaka Medical College Hospital, BSMMU & NICRH Dhaka, Bangladesh during the period from January 2014 to December 2015. In total 100 patients of several age groups with breast cancer patients attended, diagnosed and treated in the mentioned hospital were selected as the study population. Proper clinical examination and ultrasonography for the assessment of axillary lymph node status were done for every participant. All data were processed, analyzed by MS Office and SPSS program as per need. **Results:** According to the validity test, the sensitivity, specificity, positive predictive value, negative predictive value, accuracy and likelihood ratio (LR) of the clinical examination in assessment of auxiliary lymph node status in breast cancer patients were 53.7%, 85.0%, 93.5%, 31.5%, 60.0% and 3.58% respectively. As per the validity test, the sensitivity, specificity, positive predictive value, negative predictive value, accuracy and likelihood ratio (LR) of the USG in assessment of auxiliary lymph node status in breast cancer patients were 73.8%, 85.0%, 95.2%, 44.7%, 76.0% and 4.91 respectively. In this study USG had a good likelihood ratio for ruling in (or out) lymph node status in breast cancer patients than clinical examination. As positive likelihood ratio (+LR) in USG (4.91) is more than that of clinical examination (3.58), USG is better than clinical examination in assessment of auxiliary lymph node status in breast cancer patients. **Conclusion:** As per the findings of this study, we can conclude that, USG is better than clinical examination in assessment of auxiliary lymph node status in breast cancer patients. Clinicians as well as oncologists can take the ultrasonography findings as the most potential diagnostic indications in treating patients with breast cancer.

**Keywords:** Reliability, Clinical examination, Ultrasonography Axillary lymph node, Breast cancer.

Copyright © 2021 The Author(s): This is an open-access article distributed under the terms of the Creative Commons Attribution 4.0 International License (CC BY-NC 4.0) which permits unrestricted use, distribution, and reproduction in any medium for non-commercial use provided the original author and source are credited.

## INTRODUCTION

In the treatment arena of oncology, there has been growing interests in developing the clinical prediction tools to estimate the risk and severity of patients with breast cancer having axillary nodal metastases. Although several diagnostic methods are applied in detecting and/or assessing the axillary lymph node status in breast cancer patients besides clinical examination, physicians are using ultrasonography

(USG) in such purposes for long time. So, both the clinical examination and ultrasonography (USG) for the assessment of axillary lymph node status in breast cancer patients can be considered as the traditional diagnostic method in detecting breast cancer and its status. In the world, breast cancer is the most common malignancy among females, with over 1 million new cases in every year.[1] Due to the radical nature of breast cancer, surgery has now been reduced to a minimum by the use of breast conserving

procedures[2,3] and axillary lymph node dissection.[4] On the other hand, lymph node status is an important prognostic factor for breast cancer.[5] Nodal stage also affects the selection of adjuvant therapeutic modalities.[6] Several imaging techniques are available for the assessment of lymph node status, including ultrasonography, mammography, magnetic resonance imaging (MRI), positron emission tomography or computed tomography.[7] Axillary ultrasonography is a useful approach in excluding N2 and N3 invasive ductal metastases.[8] Basically, ultrasound scanning is routinely available in diagnostic breast clinics. Previous experience of USG in identification of axillary lymph nodes is mixed.[9] Partly, ultrasound scanning of the axilla may be dependent upon the expertise of the radiologist and the quality of the ultrasound equipment. The major objective of this study was to assess the reliability of clinical examination and ultrasonography for the assessment of axillary lymph node status in breast cancer patients.

## METHODOLOGY

This was a prospective observational study which was conducted in the Department of Surgery & Oncology, Dhaka Medical College Hospital, BSMMU & NICRH, Bangladesh during the period from January 2014 to December 2015. In total 100 patients of several age groups with consecutive primary breast cancer patients who had LN in USG was hypoechoic, irregular shape and anterior posterior diameter was more than transverse diameter diagnosed and treated in the mentioned hospital were selected as the study population. Proper clinical examination and ultrasonography for the assessment of axillary lymph node status were done for every participant. Ethical approval had taken from ethical committee of the mentioned hospital. Proper written consents were taken from all the participants before data collection. According to the exclusion criteria of this study, patients with palpable axillary disease, ipsilateral recurrent breast malignancy, clinical and radiologic T4 status, and neoadjuvant chemotherapy were excluded. The lymph nodes were classified as suspicious if its cortical thickness was 2.3 mm or if it had an irregular nodular cortex and/or a diminished or absent hilum.[10] Patient and tumor characteristics were retrieved from the original patient registers. Patient's data regarding the age BMI were recorded. Besides these, the size, number and location of tumors were assessed and recorded. Proper data regarding the sizes as well as the number of lymph node according to clinical examination and USG were recorded and analyzed very carefully. Patient data were collected by using a predesigned questioner. All data were processed, analyzed and disseminated by MS Office and SPSS program as per need.

## RESULT

In this study, the median age of the participants was 55 years. Among total 100 patients, 46

had palpable auxiliary lymph node and 62 have suspicious lymph node on clinical examination and USG respectively. There was no statistically significant difference in age both in clinical examination and USG findings between positive and negative cases. Most of the patients were over weighted (66.0%) followed by 18.0% and 16.0% were obese and normal weighted respectively. BMI inversely correlated with the clinical examination result but not significantly. Among total participants, most of the tumors were located in the upper outer quadrant (57%) followed by 22.0%, 17.0% and 4.0% were located in the upper inner quadrant, lower outer quadrant and in other location respectively. There was no statistically significant difference in tumor location on clinical examination and USG for the assessment of auxiliary lymph node status in breast cancer patients. As per the grading of tumor according to the clinical examination and USG in assessment of auxiliary lymph node status in breast cancer patients we observed, most of the tumors were of Grade II(67%) followed by 21.0% and 12.0% were of grade I and grade III respectively. There was no statistically significant difference in tumor grading on clinical examination and USG for the assessment of auxiliary lymph node status in breast cancer patients. As per the size of tumor according to clinical examination and USG in assessment of auxiliary lymph node status in breast cancer patients we observed, maximum 49.0% tumors were type T1 followed by 39.0% and 12.0% were T3 and T1 type respectively. There was statistically significant difference in size of tumor on both clinical examination and USG for the assessment of auxiliary lymph node status in breast cancer patients. As per the number of lymph node according to clinical examination and USG in assessment of auxiliary lymph node status in breast cancer patients we observed, maximum 46.2% patients had lymph node range 4-9 followed by 28.8% and 25.0% patients had range 1-3 and >9. Both clinical examination and USG showed positive result in increasing with the number of lymph node. There was statistically significant difference in number of lymph node on both clinical examination and USG for the assessment of auxiliary lymph node status in breast cancer patients. As per the size of lymph node according to clinical examination and USG in assessment of auxiliary lymph node status in breast cancer patients we observed, maximum 52.5% patients had lymph node with the size of 1-2 cm followed by 25.0% and 22.5% patients had lymph node with the size of >2cm and <1cm. Both clinical examination and USG showed positive result in increasing the size of lymph node. There was statistically significant difference in size of lymph node on both clinical examination and USG for the assessment of auxiliary lymph node status in breast cancer patients. In this study, out of 100 cases, 46 were diagnosed as auxiliary lymph node by clinical examination and among them 43 were confirmed by histopathological evaluation, they were true positive. The other two cases were not confirmed by histopathological evaluation, they were false positive.

Out of remaining 54 cases were not diagnosed as auxiliary lymph node by clinical examination, 37 cases were confirmed by histopathological evaluation, they were true negative and remaining 17 cases were true negative because they were not diagnosed as auxiliary lymph node either by USG or by histopathology. In this study, according to the validity test, the sensitivity, specificity, positive predictive value, negative predictive value, accuracy and likelihood ratio (LR) of the clinical examination in assessment of auxiliary lymph node status in breast cancer patients were 53.7%, 85.0%, 93.5%, 31.5%, 60.0% and 3.58 respectively. In our study, out of 100 cases 62 were diagnosed as auxiliary lymph node by USG and among them 59 were confirmed by histopathological evaluation, they were true positive. The other 3 cases were not confirmed by histopathological evaluation, they were false positive. Out of remaining 38 cases (not diagnosed as auxiliary

lymph node by USG), 21 cases were confirmed by histopathological evaluation, they were true negative and remaining 17 cases were true negative because they were not diagnosed as auxiliary lymph node either by USG or by histopathology. As per the validity test, the sensitivity, specificity, positive predictive value, negative predictive value, accuracy and likelihood ratio (LR) of the USG in assessment of auxiliary lymph node status in breast cancer patients were 73.8%, 85.0%, 95.2%, 44.7%, 76.0% and 4.91 respectively. In this study USG had a good likelihood ratio for ruling in (or out) lymph node status in breast cancer patients than clinical examination. As positive likelihood ratio (+LR) in USG (4.91) is more than that of clinical examination (3.58), USG is better than clinical examination in assessment of auxiliary lymph node status in breast cancer patients.

**Table 1:** Grading of tumor according to clinical examination and USG in assessment of auxiliary lymph node status in breast cancer patients (N=100)

Grading of tumor	Clinical examination		USG		Total
	Positive	Negative	Positive	Negative	
	n (%)	n (%)	n (%)	n (%)	
Grade I	9 (19.6)	12 (22.2)	12 (19.4)	9 (23.7)	21 (21.0)
Grade II	28 (60.9)	39 (72.2)	41 (66.1)	26 (68.4)	67 (67.0)
Grade III	9 (19.6)	3 (5.6)	9 (14.5)	3 (7.9)	12 (12.0)
P- Value	0.099		0.58		

**Table 2:** Size of tumor according to clinical examination and USG in assessment of auxiliary lymph node status in breast cancer patients (N=100)

Size of tumor	Clinical examination		USG		Total
	Positive	Negative	Positive	Negative	
	n (%)	n (%)	n (%)	n (%)	
T1 (<2 cm)	1 (2.2)	11 (20.4)	2 (3.2)	10 (26.3)	12 (12.0)
T2 (2–5 cm)	24 (52.2)	25 (46.3)	33 (53.2)	16 (42.1)	49 (49.0)
T3 (>5 cm)	21 (45.7)	18 (33.3)	27 (43.5)	12 (31.6)	39 (39.0)
P- Value	0.018 <sup>s</sup>		0.003 <sup>s</sup>		

**Table 3:** Number of lymph node according to clinical examination and USG in assessment of auxiliary lymph node status in breast cancer patients (N=100)

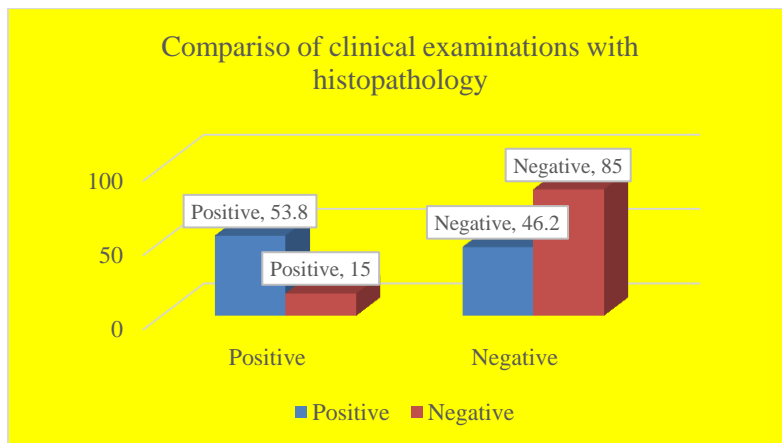
Number of lymph node	Clinical examination		USG		Total
	Positive	Negative	Positive	Negative	
	n (%)	n (%)	n (%)	n (%)	
N1 (1 - 3)	7 (16.3)	16 (43.2)	10 (16.9)	13 (61.9)	23 (28.8)
N2 (4 - 9)	18 (41.9)	19 (51.4)	29 (49.2)	8 (38.1)	37 (46.2)
N3 (>9)	18 (41.9)	2 (5.4)	20 (33.9)	0 (0.0)	21 (25.0)
P- Value	0.001 <sup>s</sup>		0.001 <sup>s</sup>		

**Table 4:** Size of lymph node according to clinical examination and USG in assessment of auxiliary lymph node status in breast cancer patients (N=100)

Size of lymph node	Clinical examination		USG		Total
	Positive	Negative	Positive	Negative	
	n (%)	n (%)	n (%)	n (%)	
<1 cm	0 (0.0)	18 (48.6)	4 (6.8)	14 (66.7)	18 (22.5)
1 - 2 cm	24 (55.8)	18 (48.6)	35 (59.3)	6 (33.3)	42 (52.5)
>2 cm	19 (44.2)	1 (2.8)	20 (33.9)	0 (0.0)	20 (25.0)
P- Value	0.001 <sup>s</sup>		0.001 <sup>s</sup>		

**Table 5:** Comparison between clinical examination and histopathology in assessment of auxiliary lymph node status in breast cancer patients (N=100)

Clinical examination	Histopathology		Total
	Positive	Negative	
Positive	43 (53.8)	3 (15.0)	46 (46.0)
Negative	37 (46.2)	17 (85.0)	54 (54.0)



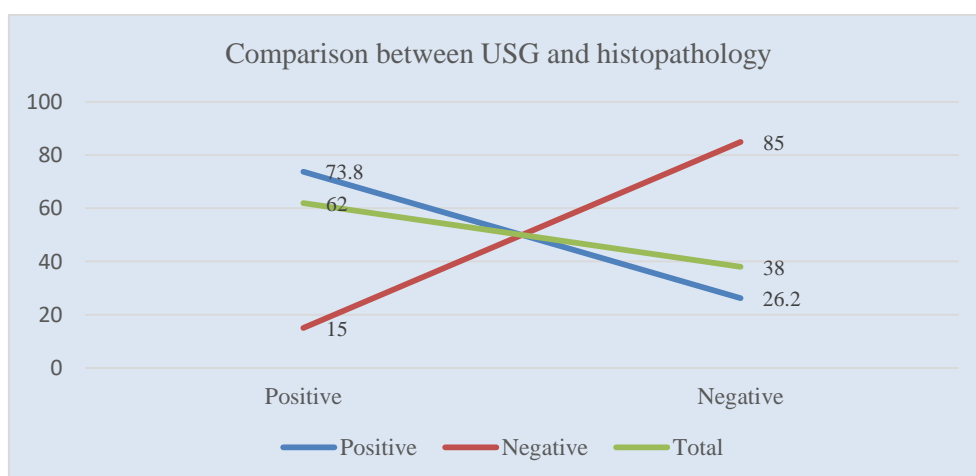
**Figure I:** Comparison of clinical examinations with histopathology

**Table 6:** Validity test of clinical examination comparing with histopathology in assessment of auxiliary lymph node status in breast cancer patients (N=100)

Validity test	Value	95% CI	
		Min	Max
Sensitivity	53.70	48.4	56.5
Specificity	85.0	63.5	96.0
Positive predictive value (PPV)	93.5	84.1	98.2
Negative predictive value (NPV)	31.50	23.50%	35.50%
Accuracy	60.0	51.40%	64.40%
Likelihood ratio (LR)	3.58	1.32	13.99

**Table 7:** Comparison between USG and histopathology in assessment of auxiliary lymph node status in breast cancer patients (N=100)

USG	Histopathology		Total
	Positive	Negative	
Positive	59 (73.8)	3 (15.0)	62 (62.0)
Negative	21 (26.2)	17 (85.0)	38 (38.0)



**Figure II:** Comparison between USG histopathology

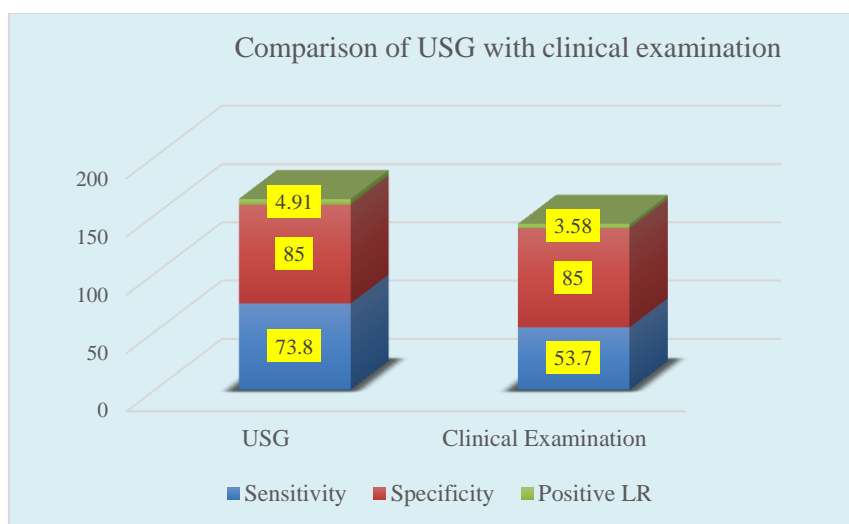
**Table 8:** Validity test of USG comparing with histopathology in assessment of auxiliary lymph node status in breast cancer patients (N=100)

Validity test	Value (%)	95% CI	
		Min	Max
Sensitivity	73.8	68.4	76.5
Specificity	85	63.8	95.9
Positive predictive value (PPV)	95.2	88.3	98.7
Negative predictive value (NPV)	44.7	33.6	50.5
Accuracy	76	67.5	80.4
Likelihood ratio (LR)	4.91	1.89	18.8

**Table 9:** Comparison of USG with clinical examination in assessment of auxiliary lymph node status in breast cancer patients (N=100)

Test	Sensitivity	Specificity	Positive likelihood ratio (+LR)
USG	73.8	85.0	4.91
Clinical examination	53.7	85.0	3.58

$$\text{Positive Likelihood Ratio (+LR)} = \text{Sensitivity} / (1 - \text{Specificity})$$

**Figure III:** Comparison of USG with clinical examinations with histopathology

## DISCUSSION

The aim of this study was to assess the reliability of clinical examination and ultrasonography for the assessment of axillary lymph node status in breast cancer patients. The median age of the participants was 55 years. In a study the mean age of the participants was 60 years (range 28-87 years). In our study, among total participants, most of the tumors were located in the upper outer quadrant (57%) followed by 22.0%, 17.0% and 4.0% were located in the upper inner quadrant, lower outer quadrant and in other location respectively. As per the grading of tumor according to the clinical examination and USG in assessment of auxiliary lymph node status in breast cancer patients we observed, most of the tumors were of Grade II(67.0%) followed by 21.0% and 12.0% were of grade I and grade III respectively. There was no statistically significant difference in tumor grading on clinical examination and USG for the assessment of auxiliary lymph node status in breast cancer patients. Routine clinical examination of axilla showed no palpable nodes in 45(52.0%) patients and palpable nodes in 4(48.0%)

patients.[11] The involvement of axillary lymph nodes as a prognostic factor in breast cancer has been accepted from the time of Halsted.[12] In this current study, according to the validity test, the sensitivity, specificity, positive predictive value, negative predictive value, accuracy and likelihood ratio (LR) of the clinical examination in assessment of auxiliary lymph node status in breast cancer patients were 53.7%, 85.0%, 93.5%, 31.5%, 60.0% and 3.58% respectively. Ultrasound examination combined with fine-needle aspiration has been reported to increase the specificity to 100.0 but decrease the sensitivity to 53.0%.[13] Another study reported similar findings that ultrasonography-guided fine-needle aspiration had a low sensitivity (39.5%) and high specificity (95.7%) for detecting ALN metastasis.[14] In our study, out of 100 cases 62 were diagnosed as auxiliary lymph node by USG and among them 59 were confirmed by histopathological evaluation, they were true positive. The other 3 cases were not confirmed by histopathological evaluation, they were false positive. As per the validity test, the sensitivity, specificity,

positive predictive value, negative predictive value, accuracy and likelihood ratio (LR) of the USG in assessment of axillary lymph node status in breast cancer patients were 73.8%, 85.0%, 95.2%, 44.7%, 76.0% and 4.91% respectively. In a study<sup>15</sup> they claimed, the sensitivity and specificity of US (Ultrasonography) and fine-needle aspiration cytology of 1124 patients were 42.2 and 97.1%, respectively. As the number of axillary nodes increased, the sensitivity increased. The percentage (%) of false-negative US (Ultrasonography) results was 18.9%; patients in this sub-group were significantly younger, more often had lymph vascular invasion, had larger tumors and were more likely to have estrogen receptor-positive tumors.[15] In this study USG had a good likelihood ratio for ruling in (or out) lymph node status in breast cancer patients than clinical examination. As positive likelihood ratio (+LR) in USG (4.91) is more than that of clinical examination (3.58), USG is better than clinical examination in assessment of axillary lymph node status in breast cancer patients.

#### Limitation of the study:

Though it was a single centered study with a small sample size, the findings of this study may not reflect the exact scenario of the whole country.

### CONCLUSION & RECOMMENDATION

In this study USG had a good likelihood ratio for ruling in (or out) lymph node status in breast cancer patients than clinical examination. As per the findings of this study, we can conclude that, USG is better than clinical examination in assessment of axillary lymph node status in breast cancer patients. Clinicians as well as oncologists can take the ultrasonography findings as the most potential diagnostic indications in treating patients with breast cancer. For getting more specific information regarding this issue we would like to recommend for conducting more studies in several places with larger sized samples.

### REFERENCES

1. Bonafede MM, Kalra VB, Miller JD, et al. Value analysis of digital breast tomosynthesis for breast cancer screening in a commercially-insured US population. *Clinicoecon Outcomes Res* 2015; 7:53-63.
2. Maughan KL, Lutterbie MA, Ham PS. Treatment of breast cancer. *Am Fam Physician* 2010; 81:1339-46.
3. Warren LE, Punglia RS, Wong JS, et al. Management of the regional lymph nodes following breast-conservation therapy for early-stage breast cancer: an evolving paradigm. *Int J Radiat Oncol Biol Phys* 2014; 90:772-7.
4. Williams PA, Suggs J, Mangana SH. Axillary lymph node treatment in breast cancer: an update. *J Miss State Med Assoc* 2014; 55:145-7.
5. Hernandez-Aya LF, Chavez-Macgregor M, Lei X, et al. Nodal status and clinical outcomes in a large cohort of patients with triple-negative breast cancer. *J Clin Oncol* 2011; 29:2628-34.
6. Wang CW, Kuo WH, Chang KJ, et al. Should adjuvant radiotherapy to the supraclavicular fossa be routinely given in patients with breast conservative treatment? *J Surg Oncol* 2007; 96:144-50.
7. Valente SA, Levine GM, Silverstein MJ, et al. Accuracy of predicting axillary lymph node positivity by physical examination, mammography, ultrasonography, and magnetic resonance imaging. *Ann Surg Oncol* 2012; 19:1825-30.
8. Neal CH, Daly CP, Nees AV, et al. Can preoperative axillary US help exclude N2 and N3 metastatic breast cancer? *Radiology* 2010; 257: 335-41.
9. Tate J J T, Lewis V, Archer T, Guyer P G, Royale G T, Taylor I. Ultrasound detection of axillary lymph node metastases in breast cancer. *Eur J Surg Oncol* 1989; 15: 139-141.
10. Deurloo EE, Tanis PJ, Gilhuijs KG, Muller SH, Kroger R, Peterse JL, Rutgers EJ, Valdes Olmos R, Schultze Kool LJ. Reduction in the number of sentinel lymph node procedures by preoperative ultrasonography of the axilla in breast cancer. *Eur J Cancer* 2003; 39: 1068-1073.
11. Rajesh YS, Ellenbogen IS, Banerjee B. Preoperative axillary ultrasound scan: its accuracy in assessing the axillary nodal status in carcinoma breast doi:10.1054/brst.2001.0352. *The Breast* (2002) 11, 49-52.
12. Halsted W S. The results of operations for the cure of cancer of the breast performed at The Johns Hopkins Hospital from June 1889 to January 1894. *Johns Hopkins Hospital Rep.* 4 1894; 297-350.
13. García Fernández A, Fraile M, Giménez N, et al. Use of axillary ultrasound, ultrasound-fine needle aspiration biopsy and magnetic resonance imaging in the preoperative triage of breast cancer patients considered for sentinel node biopsy. *Ultrasound Med Biol* 2011; 37: 16-22.
14. Park SH, Kim MJ, Park BW, et al. Impact of preoperative ultrasonography and fine-needle aspiration of axillary lymph nodes on surgical management of primary breast cancer. *Ann Surg Oncol* 2011; 18: 738-44.
15. MOORMAN AM, BOUREZ RLJH, DE LEEUW DM, E A. Pre-operative ultrasonographic evaluation of axillary lymph nodes in breast cancer patients: for which group still of additional value and in which group cause for special attention. 2015 <http://dx.doi.org/10.1016/j.ultrasmedbio.2015.06.013> *Ultrasound in Med. & Biol.*, Vol. 41, No. 11, pp. 2842-2848.