

An Interesting Case of Hermansky Pudlak Syndrome- A Rare Case Report

Dr. K. Ezhilvendhan¹, Dr. Harshitha S^{2*}, Dr. Kamalabala Krishnan³, Dr. Aprajita Gautam⁴

¹Professor, Department of Ophthalmology, Vinayaka Mission Kirupananda Variyar Medical College & Hospitals, Salem 636308, Tamilnadu, India

^{2,3,4}Postgraduate Resident, Department of Ophthalmology, Vinayaka Mission Kirupananda Variyar Medical College & Hospitals, Salem 636308, Tamilnadu, India

DOI: [10.36347/sjmcr.2021.v09i11.017](https://doi.org/10.36347/sjmcr.2021.v09i11.017)

| Received: 08.10.2021 | Accepted: 20.11.2021 | Published: 30.11.2021

*Corresponding author: Dr. Harshitha S

Abstract

Case Report

Oculo cutaneous albinism [OCA] is a autosomal recessive disorder associated with reduction in the pigment of skin, hair and eyes with strabismus and nystagmus leading to misrouting of optic nerve fibers from eye to brain during development. Reduction in skin pigmentation leads to the increased risk of skin cancer due to photosensitivity. They can occur in isolated forms or associated with syndromes. Syndromic OCA includes oculocutaneous albinism with hermansky pudlak syndrome. Seven types of OCA [1-6] with mutation in different genes have been identified.

Keywords: Strabismus, Nystagmus, Visual acuity.

Copyright © 2021 The Author(s): This is an open-access article distributed under the terms of the Creative Commons Attribution 4.0 International License (CC BY-NC 4.0) which permits unrestricted use, distribution, and reproduction in any medium for non-commercial use provided the original author and source are credited.

INTRODUCTION

Hermansky pudlak syndrome [HPS], is a rare autosomal recessive disorder characterised by abnormal biogenesis of lysosome related organelles manifests with bleeding diathesis, oculocutaneous albinism and pulmonary fibrosis in the form of interstitial lung disease [1]. Pulmonary fibrosis is highly prevalent in HPS-1, HPS-2 and HPS-4 [1]. 10 genetic types of HPS have been identified. It's prevalence is 1 to 9 in 1,000,000 individuals. In the region of Puerto Rico, HPS type 1 is common. Hypopigmentation in HPS is mainly due to the immature and abnormal melanosome with normal melanin biosynthesis within the melanocytes.

Oculocutaneous albinism is a recessive genetic disorder. 7 major types of OCA are OCA1 which can be further classified as OCA1A and OCA1B, then OCA 2, OCA 3 and OCA 4 [2]. OCA1 is due to the mutation in TYR gene, the gene is responsible for tyrosinase enzyme production that helps in melanin production. OCA 2 occurs due to the mutation in OCA 2 gene or P gene and OCA 3 occurs due to the mutation in TYRP1 gene. OCA 4 occurs due to the mutation in the SLC45A2 gene [membrane associated transport protein]. OCA 5 type occurs most commonly in pakistan population. OCA 6 type occurs due to the mutation in the SLC24A5 [3]. OCA 7 occurs due to mutation in C10orf11.

CASE REPORT

43 year female referred from MICU as a known case of Type 1 respiratory failure with Interstitial lung disease presented to us for ophthalmic evaluation with complaints of defective vision in both eyes for past 2 years. On general examination, she was breathless and on ventillation support. She had Generalized hypopigmentation of skin, hair and eyes was present. She had Right eye exotropia with both eye horizontal jerky nystagmus. She had petechiae all over the body more on her upper limbs.

She had bilateral inspiratory wheeze present and other systems were normal. She had history of Menorrhagia for past 3 years.

On Ophthalmic examination, her unaided visual acuity was Right eye 6/60 with pinhole improving upto 6/18 and Left eye 6/24 with pinhole improving upto 6/18. Her best corrected visual acuity with spectacle correction in Right eye with -3.00Dsph improved only upto 6/24 and left eye with -2.50Dsph improved only upto 6/24. Her near vision correction was both eyes with +1.25Dsph improved upto N/6. On Anterior segment examination in slit-lamp, both eyes anterior segment was normal with hypopigmented, light brown colored Iris with trans-illumination positive. On Dilated fundus examination with 90D lens, both eyes Foveal hypoplasia was present with albinotic

hypopigmented blonde fundus with hypopigmented retina with underlying choroidal vasculature are seen.

On Spectral-domain Optical coherence tomography, both eyes showed foveal hypoplasia with loss of foveal contour with normal macular thickness. On systemic investigation, her NECT of chest showed Structural distortion with small cystic lesions and tractional bronchiectatic changes in both lung lower lobe basal segments, suggestive of Interstitial lung disease with excessive hemomediastinum. On blood investigation her complete blood profile was normal with Platelet count of 100,000/mcl indicating Thrombocytopenia and Coagulation test profiles showed Prolonged Partial thromboplastin and Activated tissue thromboplastin time with Normal INR ratio.

She was diagnosed to have oculocutaneous albinism with hermannsky pudlak syndrome and treated for her ILD and dark goggles were prescribed along with spectacle for her vision.

She was also referred to dermatologist for her petechial haemorrhage and treated for the same. She was adviced to use sunscreen for UV protection and to prevent photosensitive damage.

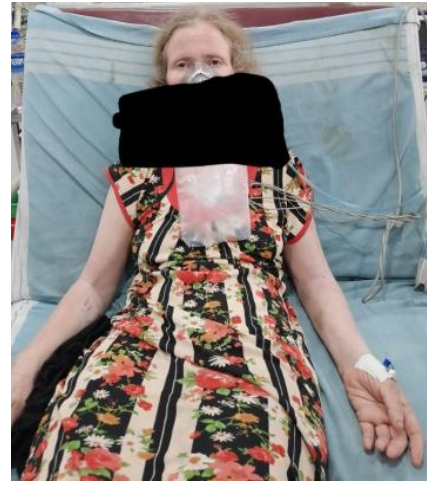

Fig 1: Showing patient with Albinism

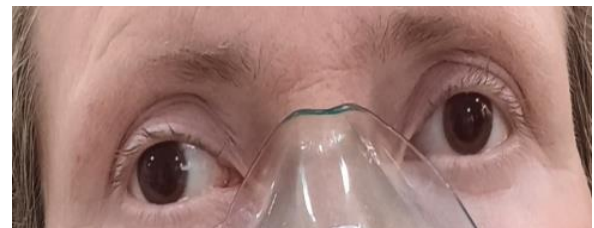

Fig 2: Light brown colored iris with R/E Exotropia

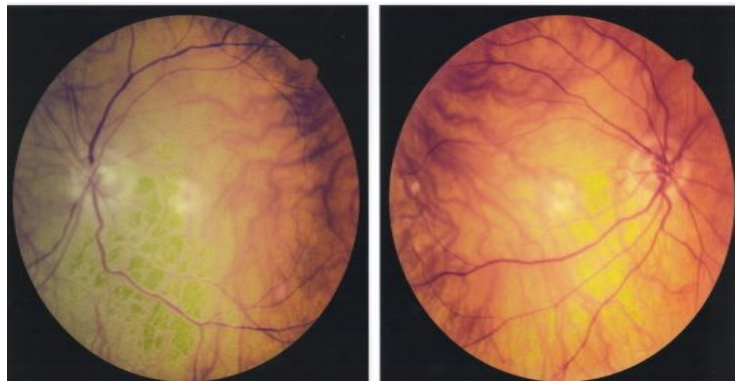


Fig 3: Both eye fundus showing albinotic fundus

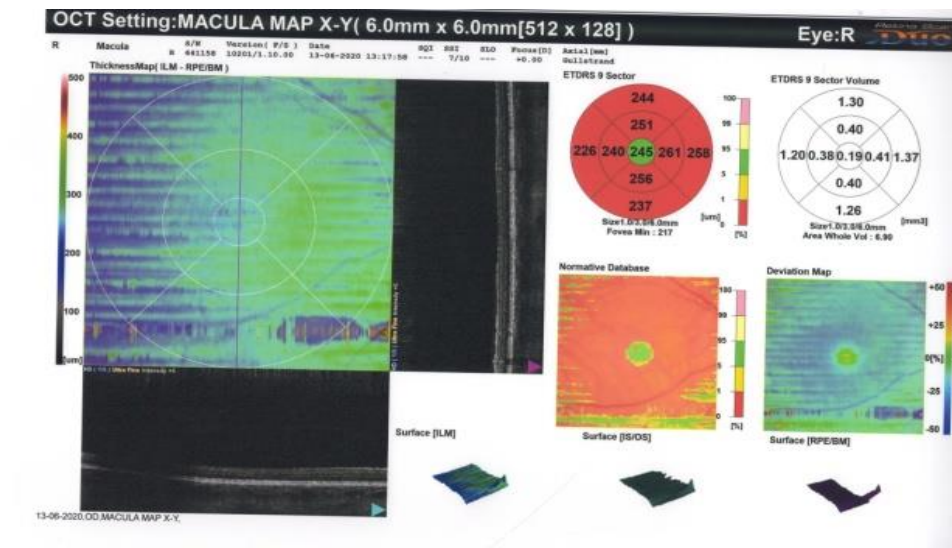


Fig 4: Showing SD-OCT image R/E with foveal hypoplasia

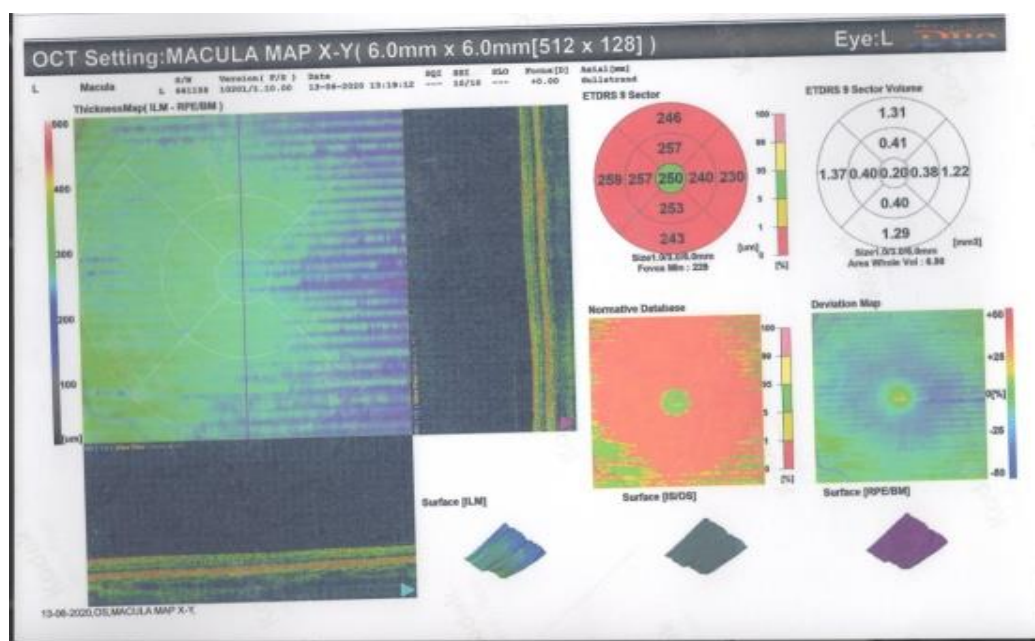


Fig 5: SD-OCT image L/E foveal hypoplasia

Table 1: Showing types of oculocutaneous albinism with corresponding gene defects

Oculocutaneous albinism Types	Gene mutated
OCA 1A	TYR 1[tyrosinase gene]
OCA 1B	TYR 1 gene
OCA 2	OCA 2 gene or P gene
OCA 3	TYRP 1 gene
OCA 4	SLC45A2 gene
OCA 5	Not identified, Gene locus on Chromosome 4[4q24]
OCA 6	SLC24A5 gene
OCA 7	C10orf11

DISCUSSION

The degree of skin and hair hypopigmentation varies with the type of Oculocutaneous albinism [OCA]. Bleeding is the main factor for mortality in these patients. Anti-fibrotics [Pirfenidone] [Nintedanib-tyrosine kinase inhibitor] for pulmonary fibrosis and procoagulants and platelet transfusion for platelet dysfunction are recommended. Prophylactic administration of desmopressin can be started in this patient. Aspirin and indomethacin are usually contraindicated in these patients, since they aggravate the platelet abnormality [4].

However HRCT is the best modality in screening these patients for pulmonary fibrosis, presents with bilateral ground glass opacities with honeycombing and traction bronchiectasis. On lung tissue biopsy with haematoxylin and eosin staining there will be aggregation of alveolar macrophages with vacuolated type 2 hyperplastic alveolar epithelial cells will be present.

Future therapy may involve novel anti fibrotic drugs and gene therapy and gene editing will be holistic novel approach for the treatment of HPS. HPS 1

construct trails of lentiviral vector after transduction they showed correction of HPS 1 gene , thus repairing the gene defect [5].

Glasses [bifocals] and dark goggles and regular usage of sunscreen and skin checkups for early detection of skin cancer are preferred in these patients [6].

CONCLUSION

The diagnosis of Oculo cutaneous albinism [OCA] with Hermansky pudlak syndrome [HPS] is based on the history and clinical findings of hypopigmentation of skin, hair, iris and albinotic retina with foveal hypoplasia associated with Interstitial lung disease, bleeding problems with platelet dysfunction.

Multi-disciplinary approach with early detection and treating the cause with prophylactic management can increase the cure rate from fatal complications.

However due to clinical overlap between OCA subtypes and genetic subtypes of HPS, Molecular diagnosis is necessary to establish the gene defect.

REFERENCES

1. Dimson, O., Drolet, B. A., & Esterly, N. B. (1999). Hermansky-Pudlak syndrome. *Pediatr Dermatol*, 16, 475-477.
2. King, R. A., & Summers, C. G. (1988). Albinism. *Dermatol Clin*, 6, 217-228.
3. Oetting, W. S., & King, R. A. (1999). Molecular basis of albinism: mutations and polymorphisms of pigmentation genes associated with albinism. *Human mutation*, 13(2), 99-115.
4. Chemaly, S., & Young, L. R. (2016). Síndrome de Hermansky y Pudlak. *Clin Chest Med*, 37(3), 505-511.
5. Gahl, W. A., Brantly, M., Troendle, J., Avila, N. A., Padua, A., Montalvo, C., ... & Gochuico, B. (2002). Effect of pirfenidone on the pulmonary fibrosis of Hermansky-Pudlak syndrome. *Molecular genetics and metabolism*, 76(3), 234-242.
6. Witkop, C. J. (1979). Albinism: hematologic-storage disease, susceptibility to skin cancer, and optic neuronal defects shared in all types of oculocutaneous and ocular albinism. *The Alabama journal of medical sciences*, 16(4), 327-330.