

Surgical Treatment of Post-Traumatic Diaphragmatic Ruptures

Mohamed Lemine Ahmed Salem*, Ilham Bzikha, Jalila Ters, Tarek Anis, El bachir Benjelloun, Abdelmalek Ousadden, Khalid Ait Taleb, Ouadii Moaquit, Hicham El Bouhadouti

Department of General Surgery USMBA Fez

DOI: [10.36347/sasis.2021.v07i12.002](https://doi.org/10.36347/sasis.2021.v07i12.002)

| Received: 26.10.2021 | Accepted: 30.11.2021 | Published: 04.12.2021

*Corresponding author: Mohamed Lemine Ahmed Salem

Abstract

Original Research Article

Diaphragmatic ruptures represent a rare clinical entity, but potentially serious and often integrated into multiple traumas. Our study was about 17 cases collected in the visceral surgery department of CHU Hassan II in Fez, over a period of 8 years from January 2012 to December 2020. We reviewed the literature, in order to highlight the main characteristics of these lesions. In our series, the mean age of our patients was 46 years, with a predominance of men and a sex ratio of 3,2. Left RTDs are more common, but the incidence of right RTDs is increasing. Clinically, dyspnea and abdominal pain are the main functional signs, each presenting 58.82% of all symptoms. Radiologically, abdominal CT is performed in all patients and confirmed the diagnosis. The treatment was surgical in all patients: a midline laparotomy was performed in 14 patients (82%), on the other hand laparoscopy was performed in 3 patients (18%). The stomach and colon are the most herniated organs. The modalities of repair of the diaphragmatic rupture were simple silk raffia in 88% of cases and prosthetic repair in 12% of cases. The mortality of trauma victims of a ruptured diaphragm is mainly due to associated injuries, especially severe head trauma. The morbidity is mainly pulmonary; it is represented by functional sequelae, which must be prevented by respiratory physiotherapy.

Keywords: Diaphragm, Thoracoabdominal trauma, Post traumatic hernia, Surgery.

Copyright © 2021 The Author(s): This is an open-access article distributed under the terms of the Creative Commons Attribution 4.0 International License (CC BY-NC 4.0) which permits unrestricted use, distribution, and reproduction in any medium for non-commercial use provided the original author and source are credited.

INTRODUCTION

Post-traumatic diaphragmatic hernias are defined as the passage of abdominal viscera into the thorax through a post-traumatic diaphragmatic breach [1].

A rupture of the diaphragm can be difficult to detect in the acute phase, because its signs are not very specific and the imaging, which visualizes the ascended organs but more difficult the rupture itself, can be faulted. Thus, it is often unrecognized in the acute phase, and may appear late. Once diagnosed, the surgical treatment is the abdominal suture, often preferred to the thoracic route, which has limited indications. The laparoscopic approach is a new approach, legitimate in a stable trauma patient.

The objectives of our work are

- Discuss the epidemiological and clinical profile of DR.
- Discuss the value of the various additional examinations required to establish the diagnosis.
- Focus on the different therapeutic attitudes and their indications.

- Describe the evolutionary aspect and the interest of the follow-up of these patients.

MATERIAL AND METHOD

We conducted a retrospective study involving 17 patients hospitalized in the emergency departments and visceral surgery A and B of the CHU Hassan II in Fez, a period of 9 years from January 2012 to December 2020.

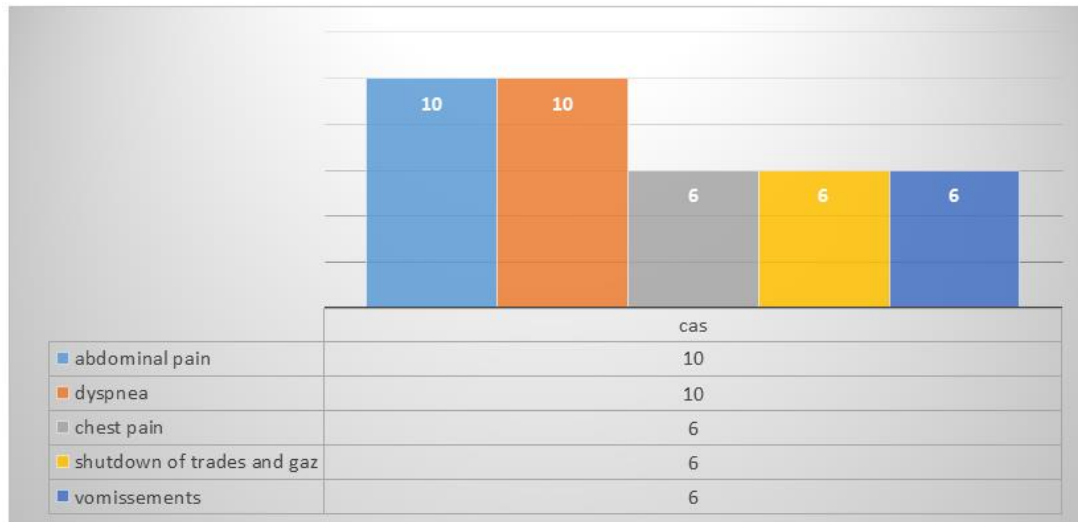
During this work, we collected the epidemiological, clinical, therapeutic and evolutionary data of the patients.

RESULT AND ANALYSIS

The average age of our patients was 46 years with extremes ranging from 17 to 69 years. There is a male predominance with a sex ratio M / F 3, 2.

The circumstances of the trauma were a road accident (47%), a fall from a great height (11.7 %) and a stabbing assault (35.3 %) (Figure 1).

In our series, dyspnea and abdominal pain are the main functional signs.



The work-up included a chest x-ray in 8 patients 47%, and a thoraco-abdominal CT scan which is performed in all our patients and which objectified: diaphragmatic ascent: 12 cases, strangulation of a DR: 8 cases.

The therapeutic management consisted of resuscitation measures, medical treatment and surgical treatment.

Six of our patients were admitted in a state of shock who received preoperative resuscitation measures. The treatment was surgical in all our patients. Median laparotomy was performed in 14 cases (82% of operated patients) and laparoscopy was performed in three patients (18%). The diaphragmatic lesion was mainly located on the left (88%).

Only two cases were reported on the right (12%). No bilateral lesions were detected. The dimensions of diaphragmatic ruptures greater than 5 cm in 12 patients (70%).

In our series, diaphragmatic rupture has always been associated with an ascent of one or more intrathoracic abdominal organs. The most commonly found are: in left ruptures: The stomach: was herniated in 9 cases, the colon and omentum: in 10 cases. And in the right ruptures: the liver was herniated in one case, the colon only once.

The diaphragmatic lesions were sutured by stitches separated in X to the no absorbable suture in 15 patients (88%). Prosthetic repair was necessary in 2 patients 12%.

Numbre of patients	Herniated visceral	Percentage	State of the viscera	Gesture
3 patients	Stomach	17.64%	Normal (2 cas) Necrosis (1 cas)	Reduction Atypical resection
2 patients	Stomach/Colon/ greater omentum	11.76%	Normal (2 cas)	Reduction
2 patients	Colon/Stomach/Hail	11.76%	Normal (1 cas) Gastric perforation (1 cas)	Reduction Gastric perforation suture
1 patient	Liver	5.88%	Normal	Reduction
1 patient	Stomach/Colon/Spleen	5.88%	Normal	Reduction
1 patient	Hail	5.88%	Necrosis	Resection/Stoma
6 patients	Colon	41.2%	Normal (4 cas) Necrosis (2 cas)	Reduction Resection/Colostomy

Thoracic drainage was performed in 15 patients at the level of the 4th intercostal space at the mid axillary line. The average duration of this drainage was 3 days (3-7 days).

The postoperative consequences were marked by postoperative peritonitis following the release of colo-colic anastomosis in only one case (5.88).

At long-term follow-up was marked by a recurrence of the diaphragmatic hernia in only one case, and 2 cases of our patients presented an eventration.

<u>Early complications</u>			
Pulmonary : 8		47%	
➤ Atelectasis	5		30%
➤ Pneumonia	2		11,76%
➤ Pleurisy	1		5,88%
Abdominal : 1		5.88%	
➤ Peritonitis	1		5,88%
Infection of the wall	4	23.52%	
<u>Late Complications</u>			
Supraumbilical median eventration	2		11.76%
Recurrence	1		5.88%

And none of our patients died.

DISCUSSION

The epidemiological study found that the rupture of the diaphragm is most often a lesion of young adult males [2, 3], which is consistent with the results of our study.

The diaphragm can be broken by two mechanisms: by contusion (encountered in road accidents), by wound (whether wound with a knife or a firearm). Road accidents are the leading cause of diaphragm ruptures in the various series, including ours.

In our series, the diaphragmatic rupture was located at the level of the left dome in 88% of patients. This clear predominance may be linked to the relative fragility of the left dome and to the buffer role played by the liver on the shock wave transmitted [4]. Bilateral ruptures are exceptional and occur in less than 2% of cases [5, 6]. In our study, none of our patients presented with a bilateral rupture.

The diagnosis of diaphragmatic hernias is still late; in 18 to 50% of cases, it is only placed at a distance from the causal trauma [7].

The circumstances of the diagnosis are varied: either accidental discovery: during a laparotomy or thoracotomy (45% of diaphragmatic ruptures) [7]. In the acute phase of the trauma, or at a distance from the trauma, sometimes years later. In this case, the diagnosis is revealed by a digestive or respiratory complication: occlusive syndrome or respiratory distress.

In our series, patients with stabbing assault (2 patients) presented with a diaphragmatic hernia years after the trauma (5 years for one and 2 years for the other). Therefore, one should systematically look for diaphragmatic wounds in thoracoabdominal wounds and their suture before they widen and subsequently develop a diaphragmatic hernia.

Chest x-ray remains the simplest examination to confirm the diagnosis given its availability, the chest x-ray after the installation of a nasogastric tube must be systematically performed. Its interest lies mainly in the detection of a diaphragmatic hernia [8].

In our series, the images most often found were: an ascension of the left diaphragmatic dome (35%) and clarity in the left hemi thorax (23%).

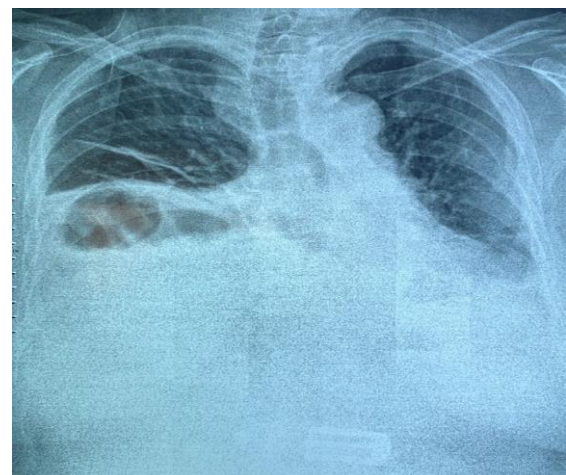


Image-1: Chest x-ray showing a right intrathoracic hydro-aeric image (CHU HASSAN II)

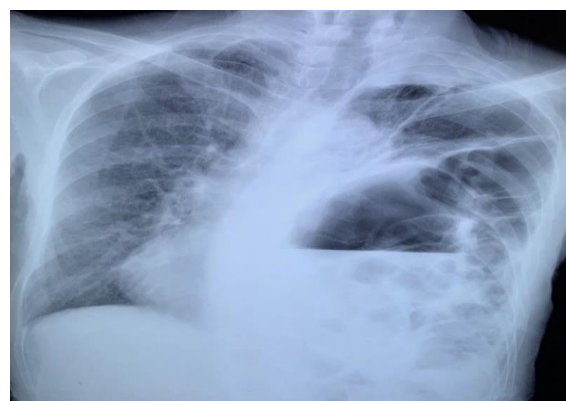

Image-2: Presence of the colon in left intrathoracic (CHU Hassan II).

Performing a chest scan remains essential. Indeed, the chest x-ray is not sufficient (28 to 70% of cases of ruptures detected). Thoracic abdominal CT provides additional diagnostic evidence, and above all makes it possible to assess the associated traumatic thoracic and abdominal injuries.

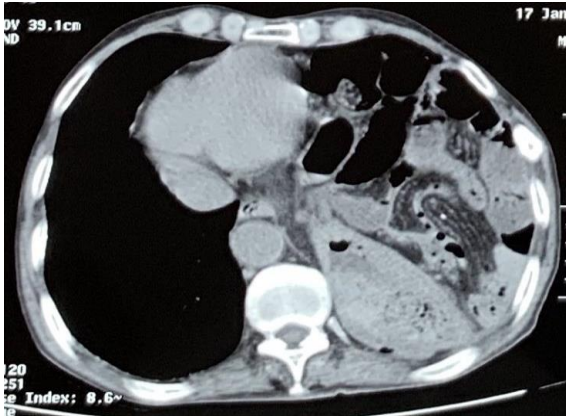


Image-3: TAP CT showing the presence of the small intestine and the intrathoracic stomach (CHU Hassan II)

Thoracoscopy has been shown to be an effective diagnostic and therapeutic means in acute cases less than 24 hours old. It should not be used after this time because the beginner adhesions make it less reliable.

In our series, this technique is not used, as the diagnosis of diaphragmatic rupture is already made by chest x-ray or CT.

A recognized diaphragmatic rupture constitutes an indication for surgery, as soon as the diagnosis is made. It has no tendency to self-repair. The progressive risk, in addition to possible pain or non-specific disorders, is volvulus of an ascended organ, the prognosis of which is poor.

The basis of treatment is the reintegration of the abdominal viscera, the repair of the diaphragmatic breach and the systematic drainage of the pleural cavity.

The organs once reintegrated into the abdomen should be explored, as well as the rest of the abdominal cavity. In exceptional cases of strangulation, digestive resection may be necessary if the ischemic elements appear to be irreversible [3].

If the treatment is early, repair can be done by simply bringing the edges together using X-shaped points of non-absorbable suture [9, 10].

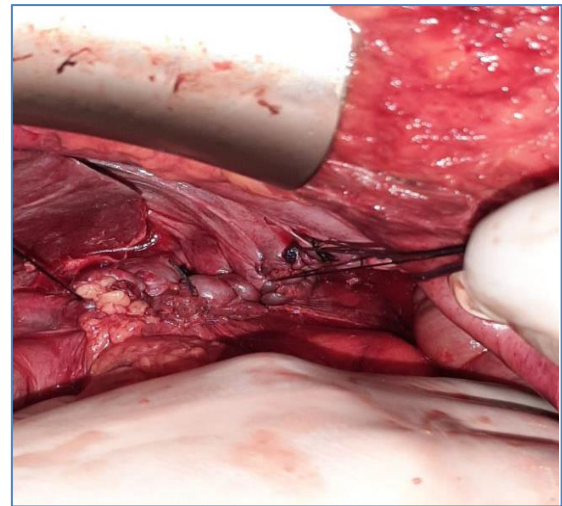


Image-4: Raphie de la RD by stitches separated at the silk 1 (BOC CHU Hassan II).

Prosthetic repair: If the treatment is done away from the diaphragmatic rupture or during loss of substance. The prosthesis must go far beyond the limits of the diaphragmatic breach to be fixed on healthy muscle by separate transfixing points.

Chest drainage is on the whole simpler than that for abdominal injuries and usually does not exceed the skills of a visceral surgeon. In the absence of an associated parenchymal lesion, the pulmonary drain is removed as soon as the pulmonary re-expansion is obtained.

In our series, we resort to laparotomy, given the ease of the first step and the Lower morbidity compared to thoracotomy.

The post-operative consequences are often simple. The prognosis is not bad on its own. The severity is related to the associated lesions.

The mortality of trauma victims of a ruptured diaphragm is estimated between 20 and 60% [2]. A Turkish study aimed at determining the factors influencing mortality during diaphragmatic ruptures concluded that among the various parameters studied: hemorrhagic shock, the grade of the diaphragmatic lesion and the presence of splenic lesion are correlated with a mortality rate raised [11].

In our series, the evolution was good with a low rate of postoperative complications.

CONCLUSION

Diaphragmatic ruptures represent a rare clinical entity, but potentially serious and often integrated into multiple trauma.

Our study insisted on the various clinical presentations of these RDs, on the diagnostic means that can be used both radiological and videoscopic, as well as on the therapeutic means and indications.

Early diagnosis continues to be a challenge for radiologists and surgeons alike. The clinical symptomatology, which is not very specific, is often masked by other lesions that put the prognosis into play.

Chest x-ray, performed systematically in cases of multiple trauma, can confirm the diagnosis by showing digestive elements or the path of the nasogastric tube in the chest, but its sensitivity is low.

CT remains the last resort in case of diagnostic doubt. Laparoscopy, a very reliable diagnostic tool, allows therapeutic procedures to be performed.

Therapeutically: Any diaphragmatic rupture diagnosed must be surgically repaired as soon as possible to avoid strangulation of the ascended viscera in the thorax, the prognosis of which is poor. Diaphragmatic rupture can be addressed by laparotomy or thoracotomy, depending on the surgeon's experience and the presence or absence of associated thoracic and / or abdominal lesions.

The diaphragmatic defect is repaired by separate stitch suturing with a non-absorbable suture. In peripheral disinsertion, the diaphragm is reinserted either to persistent fibrous tissue, to the original rib, or to the intercostal muscles of the overlying intercostal space. In old and large ruptures, the use of prosthetic material is sometimes necessary.

In fact, we find that, on the one hand, the morbidity and mortality of diaphragmatic ruptures is directly linked to their ignorance and diagnostic delay and that, on the other hand, an identified rupture may have a deferred surgical treatment.

REFERENCES

1. Kuo, I. M., Liao, C. H., Hsin, M. C., Kang, S. C., Wang, S. Y., Ooyang, C. H., & Fang, J. F. (2012). Blunt diaphragmatic rupture-a rare but challenging entity in thoracoabdominal trauma. *The American journal of emergency medicine*, 30(6), 919-924.
2. Fair, K. A., Gordon, N. T., Barbosa, R. R., Rowell, S. E., Watters, J. M., & Schreiber, M. A. (2015). Traumatic diaphragmatic injury in the American College of Surgeons National Trauma Data Bank: a new examination of a rare diagnosis. *The American Journal of Surgery*, 209(5), 864-869.
3. Hofmann, S., Kornmann, M., Henne-Bruns, D., & Formentini, A. (2012). Traumatic diaphragmatic ruptures: clinical presentation, diagnosis and surgical approach in adults. *GMS Interdisciplinary plastic and reconstructive surgery DGPW*, 1.
4. Favre, J. P., Cheynel, N., Benoit, L., & Favoulet, P. (2005). Traitement chirurgical des ruptures traumatiques du diaphragme. *EMC-chirurgie*, 2(3), 242-251.
5. Mihos, P., Potaris, K., Gakidis, J., Paraskevopoulos, J., Varvatsoulis, P., Gougoutas, B., ... & Lapidakis, E. (2003). Traumatic rupture of the diaphragm: experience with 65 patients. *Injury*, 34(3), 169-172.
6. Asensio, J.A., Petrone, P. (2004). Diaphragmatic injury. In: Cameron JL (ed) Current surgical therapy. 8th ed. Elsevier Mosby Co, Philadelphia, 946-55.
7. F Wounds and contusions of the abdomen EMC-Chir, 2004: 18- 31.
8. Genotelle, N., Lherm, T., Gontier, O., Le Gall, C. (2004). Caen Endless right hemothorax revealing a hepatic wound with diaphragmatic rupture *Annales Française d'Anesthésie et de Réanimation* 23; 831-834.
9. Rashid, F., Chakrabarty, M. M., Singh, R., & Iftikhar, S. Y. (2009). A review on delayed presentation of diaphragmatic rupture. *World Journal of Emergency Surgery*, 4(1), 1-7.
10. Testini, M., Girardi, A., Isernia, R. M., De Palma, A., Catalano, G., Pezzolla, A., & Gurrado, A. (2017). Emergency surgery due to diaphragmatic hernia: case series and review. *World Journal of Emergency Surgery*, 12(1), 1-18.
11. Post-traumatic diaphragmatic hernias About 16 cases A. LAFRIKH, B. FINECH *, A. EL IDRISSE DAFALI * General Surgery Department, Ibn Tofail Hospital, Mohammed VI University Hospital, Marrakech.