

Primary Biliary Lymphoma Mimicking Cholangiocarcinoma

Oumaima Kassou*, Yassine Hama

Department of Surgery "A", Ibn Sina University Hospital, Mohammed V University, Rabat, Morocco

Original Research Article

*Corresponding author

Oumaima Kassou

Article History

Received: 12.10.2018

Accepted: 25.10.2018

Published: 30.11.2018

DOI:

10.21276/sasjs.2018.4.11.1



Abstract: Non-Hodgkin lymphoma located in the bile duct is an exceptional presentation. Clinical and radiographic manifestations are similar to cholangiocarcinoma. This diagnostic dilemma may lead to the indication of unnecessary and potentially morbid surgical resections. We report the case of a 74-year-old patient with a biliary lymphoma mimicking cholangiocarcinoma.

Keywords: Bile ducts; Cholangiocarcinoma; Lymphoma.

INTRODUCTION

Non-Hodgkin lymphoma located in the bile duct is an exceptional presentation. Clinical and radiographic manifestations are similar to cholangiocarcinoma. This diagnostic dilemma may lead to the indication of unnecessary and potentially morbid surgical resections.

OBSERVATION

We report the case of a 74-year-old patient with a satisfactory general health status (WHO 2) and an ASA score of one, who had a history of cholecystectomy for chronic cholecystitis a year earlier. The patient was admitted at our department for jaundice, rapid weight loss (10kg in 1 month) without fever. His lab results showed elevated total bilirubin levels at 53.05mg/L, gamma glutamyl transferase (GGT) levels at 123 U/l, with barely increased transaminases levels. Serology results for hepatitis were negative. At this stage, the diagnosis was suggestive of postoperative stricture due to bile duct injury from his previous surgery. An ultrasound (US) showed a mass in the mid portion of the common bile duct in close contact with the portal vein and multiple lymph nodes.

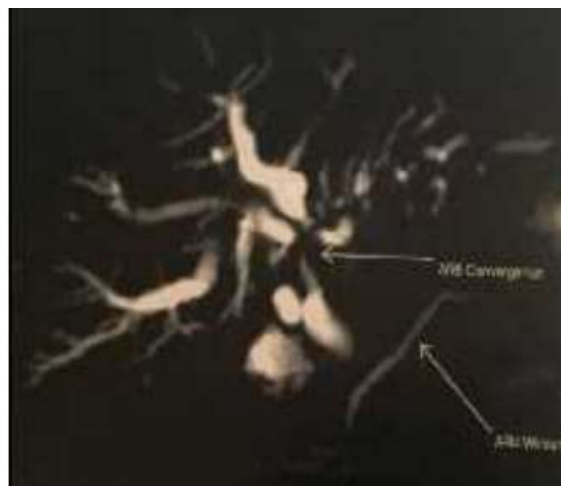

Fig-1: The Magnetic resonance cholangio-pancreatography showed a neoplastic process of the biliary confluence (Bismuth I)

Magnetic resonance imaging showed a tumor-like process at the hepatic hilum in close contact with the portal vein without any signs of invasion of the hepatic artery and the presence of surrounding lymph

nodes highly suggestive of a cholangiocarcinoma (Figure 1).

Additional endoscopic ultrasonography (EUS) also suggested a cholangiocarcinoma of the common bile duct (Figure 2).

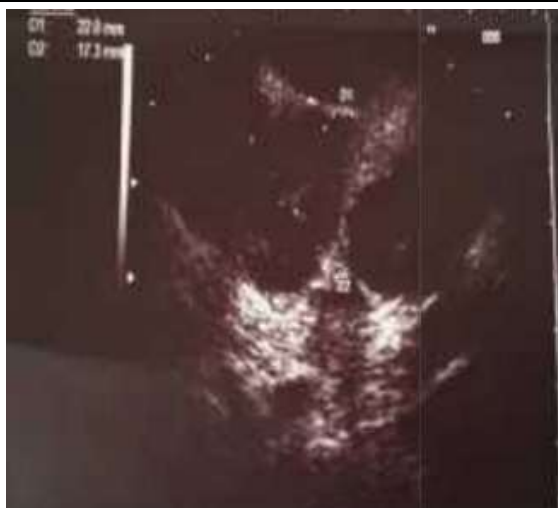

Fig-2: Tumoral stenosis of the distal part of the main bile duct on EUS

Endoscopic retrograde cholangiopancreatography (ERCP) showed a 3 cm long bile duct stricture from the proximal portion of the common bile duct just above the insertion zone of the cystic duct to

upper biliary confluence. A plastic stent (Figure 3) was put in place to restore bile flow and surgery was then indicated.

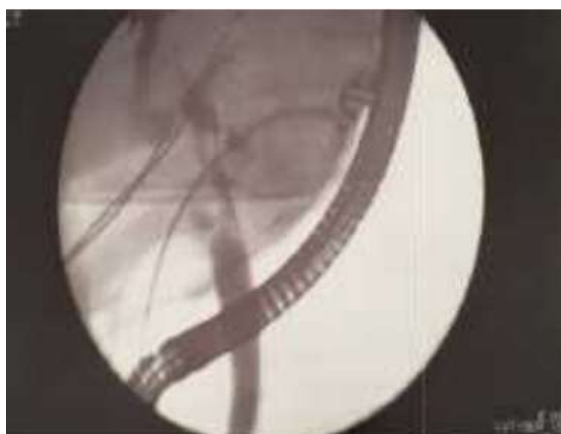


Fig-3: A plastic biliary stent to assure the internal biliary drainage (CPRE image)

A resection of the common bile duct and the superior biliary confluence was performed with bilioenteric anastomosis via three ductal orifices. The immediate postoperative course was noticeable for two fits of bacterial cholangitis that were successfully treated with oral antibiotics. Histology studies found a malignant tumor proliferation of lymphoid architecture

and diffuse in nature. The mitotic rate was low. Additional immunohistochemistry showed positive membrane expressions of CD20, CD5, CD23 (Figure 4 a, b, c), and Ki67 was positive in 15% of cells while Cyclin-D1 was found to be negative. The histopathology study concluded on B-Cell Non-Hodgkin lymphoma (NHL) of the bile duct.

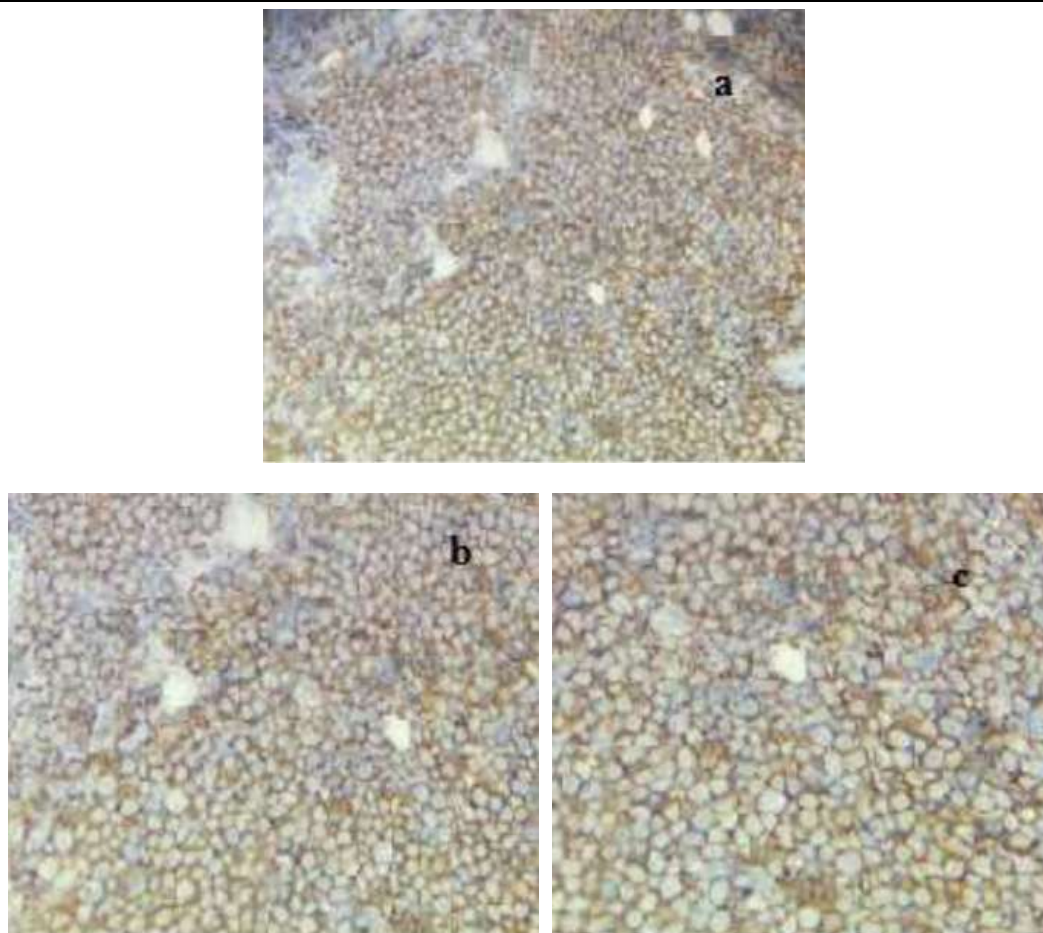


Fig-4(a, b, c): positive membrane expressions of CD20 (a); CD23 (b); CD5 (c)

A multidisciplinary meeting with oncologists decided on putting the patient on a CHOP chemotherapy regimen

DISCUSSION

Diffuse Large B-Cell Lymphoma (DLBCL) is the most common lymphoid tumor and the most common histological subtype of NHL. Its frequency amongst malignant causes of bile duct obstruction is estimated at 1-2 % [1]. The incidence of bile duct lymphoma appears to be higher in men (55%) [1,2] with a predominance among American Caucasians [1]. The average age of diagnosis is 48 years [2] and the occurrence of primary lymphoma of the bile duct is extremely rare, it mimics other malignant causes of bile duct obstruction. To our knowledge, only 29 cases have been published in the literature so far [1]. The most common clinical sign cited in the literature was the occurrence of jaundice associated with dark urine and pale stool. Other non-specific clinical signs such as abdominal pain, vomiting, pruritis, fever and weight loss have also been reported in some cases [3]. Jaundice is, however, rarely the presenting symptom of NHL and obstruction of the bile duct was usually secondary to extrinsic compression by peri-hepatic, peri-pancreatic or portal lymph nodes [4]. Lab tests and radiological imaging such as US, Computed Tomography (CT),

Magnetic Resonance Imaging (MRI), EUS, and cholangiography may show cholestasis but not signs specific to biliary lymphoma. These tests tend to be suggestive of other more frequent diagnoses such as sclerosing cholangitis, cholangiocarcinoma, pancreatic carcinoma or Klatskin tumor [1]. However, Yoon et al have suggested, despite the rarity of published documents, that radiologists should raise the possibility of a primitive biliary lymphoma when cholangiography shows a slight narrowing of extra-hepatic bile duct lumen without mucosal irregularities. And this despite the diffuse thickening of the duct walls on MRI and CT imaging [5]. For all the cases reported in the literature, neither clinical presentation, lab results, nor radiological findings were suggestive of the diagnosis of primary biliary lymphoma [1]. Given the rarity of reported cases, there is no consensus on the treatment of primary NHL of the bile duct [1, 2, 7]. Often misdiagnosed, surgery is performed with an oncology-type resection, and diagnosis is established only after pathology examination and immuno-histochemistry studies of the surgical specimen. This creates a management dilemma, given the chemo-sensitive nature of the disease and the possibility of complete remission on chemotherapy alone. CHOP (cyclophosphamide, hydroxydaunorubicine, oncovin, prednisone) is the most used chemotherapy regimen or

COP associated with other agents such as bleomycin and methotrexate [6]. Some authors recommend the placement of biliary stents before the start of chemotherapy [7, 8]. Diagnostic surgical exploration would allow for lymph node biopsies and specify the extent of invasion. However, on the other hand, surgical resection of the lesion remains controversial. Radiation therapy appears to have no place in the management of biliary lymphomas given the significant adverse effects that may result in this particular location [2].

CONCLUSION

Obstructive jaundice is an unusual clinical presentation of Non Hodgkin Lymphoma. However, it should be considered in the differential diagnosis of malignant bile duct obstruction. Early diagnosis can help avoid major surgical resection and delay in chemotherapy, which is considered the standard of care for the disease.

Conflicts of Interest: The authors have no conflicts of interest to declare.

Informed Consent: Written informed consent was obtained from the patient for publication of this Case Report and any accompanying images.

REFERENCES

1. Zakaria A, Al-Obeidi S, Daradkeh S. Primary non-Hodgkin's lymphoma of the common bile duct: A case report and literature review. *Asian journal of surgery*. 2017 Jan 1;40(1):81-7.
2. Corbinais S, Caultet-Maugendre S, Pagenault M and all. lymphome T primitive de la voie biliaire principale. *Gastroenterol. Clin Biol*. 2000;24 ,843-847
3. Ödemiş B, Parlak E, Başar Ö, Yüksel O, Şahin B. Biliary tract obstruction secondary to malignant lymphoma: experience at a referral center. *Digestive diseases and sciences*. 2007 Sep 1;52(9):2323-32.
4. Das K, Fisher A, Wilson DJ, dela Torre AN, Seguel J, Koneru B. Primary non-Hodgkin's lymphoma of the bile ducts mimicking cholangiocarcinoma. *Surgery*. 2003 Sep 1;134(3):496-500.
5. Yoon MA, Lee JM, Kim SH, Lee JY, Han JK, Choi BI, Kim SW, Jang JJ. Primary biliary lymphoma mimicking cholangiocarcinoma: a characteristic feature of discrepant CT and direct cholangiography findings. *Journal of Korean medical science*. 2009 Oct 1;24(5):956-9.
6. Dudgeon DJ, Brower M. Primary chemotherapy for obstructive jaundice caused by intermediate-grade non-Hodgkin lymphoma. *Cancer*. 1993 May 1;71(9):2813-6.
7. Ross WA, Egwim CI, Wallace MJ, Wang M, Madoff DC, Lee JH. Outcomes in lymphoma patients with obstructive jaundice: a cancer center experience. *Digestive diseases and sciences*. 2010 Nov 1;55(11):3271-7.
8. Chaudhari D, Khan S, Saleem A, Taylor T, Reddy C, Borthwick T, Young M. Obstructive jaundice as an initial manifestation of non-Hodgkin lymphoma: treatment dilemma and high mortality. *Case reports in medicine*. 2013;2013.