

# Reconstruction of Post-Burn Flexion Contractures of the Knee Joint with Perforator plus Fasciocutaneous Flaps

Dr. Jayabrata Maitra<sup>1\*</sup>, Dr. Saurav Sethia<sup>2</sup>, Dr. Priyanka Chilbule<sup>3</sup>

<sup>1-3</sup>Senior Resident, Dept. of Plastic Surgery, IPGME&R, Kolkata, India

DOI: [10.36347/sasjs.2021.v07i12.004](https://doi.org/10.36347/sasjs.2021.v07i12.004)

| Received: 04.11.2021 | Accepted: 10.12.2021 | Published: 13.12.2021

\*Corresponding author: Dr. Jayabrata Maitra

## Abstract

## Original Research Article

A post-burn flexion contracture of the knee joint is a disabling condition which interferes with an upright posture and a bipedal locomotion. Islanded perforator flaps have been used to resurface the tissue defect which is produced as a result of the contracture release. Despite their various advantages, they are limited by an increased tendency to undergo venous congestion. Perforator-plus flaps can be used to overcome this limitation, while retaining the merits of the islanded perforator flaps. Fifty four patients with post flame burn flexion contractures of the knee joints underwent surgical releases and coverages by various local fasciocutaneous perforator-plus flaps. The patients were followed up for 6 months and the various aspects of the functional and the aesthetic rehabilitations were assessed. All the local fasciocutaneous perforator-plus flaps resurfaced the tissue defect over popliteal fossa with good colour and texture match and maintenance of the contour. None of the flaps had any significant early or delayed complications which necessitated reoperations. All the patients were satisfied with the functional and aesthetic outcomes. Local fasciocutaneous perforator-plus flaps can be considered as one of the primary treatment modalities for the surgical release and reconstruction of post burn flexion contractures of the knee.

**Keywords:** Post burn contracture, knee contracture, fasciocutaneous flap, perforator plus flap, flap reconstruction.

**Copyright © 2021 The Author(s):** This is an open-access article distributed under the terms of the Creative Commons Attribution **4.0 International License (CC BY-NC 4.0)** which permits unrestricted use, distribution, and reproduction in any medium for non-commercial use provided the original author and source are credited.

## INTRODUCTION

Vastly improved standard of care in burn patients has resulted in a decrease in overall mortality. This is associated with an urgent requirement of rehabilitation of burn survivors to address long term functional deficits and improve their quality of life [1].

The incidence of burn cases has been estimated to range from 60-70 lakhs annually in India [2]. Post burn contractures may develop as a result of delayed surgical intervention or inadequate post-operative care in the form of splintage and physiotherapy at ill equipped peripheral units. This, results in an enormous burden on the health care infrastructure [2].

Contracture in major joint like the knee results in severe functional deficits in locomotion, preventing the patient from leading a productive life. Thorough surgical release of the flexion contracture of these joint results in a large wound requiring coverage with pliable soft tissue in order to maintain joint functions.

Mere skin grafting for these cases without intensive long term physiotherapy [3, 4] is generally

associated with a high rate of recurrent contracture. Traditional techniques such as cross-leg flaps required immobilization for weeks [5] and were associated with significant morbidity.

Use of muscle or musculocutaneous flaps [6-8] result in unnecessary bulk, poor aesthesis and varying degrees of functional loss to an already crippled extremity. Better donor site aesthesis and reduced morbidity can be achieved with conventional fasciocutaneous flaps which are simple and reliable and they provide a durable pliable coverage.

Islanded perforator flaps [9, 10] based only on the dissected musculocutaneous perforators can address the delicate balance between the flap vascularity and the reach in the lower limb to an extent with minimal donor site functional compromise and better aesthesis. However torsional forces associated with these designs frequently cause venous compromise of the flaps and is a major cause of failure [11, 12].

In perforator-plus flap design peninsular fasciocutaneous flaps are raised including one or more

perforators in their base [13, 14]. This technique not only reinforces the venous drainage of the flap but also provides a dual blood supply through the perforator and the subdermal plexus. To facilitate defect coverage and a tension free inset the pedicle may be narrowed by back cuts as required [14]. This particular flap design can be safely used in the knee and the upper and middle thirds of the leg [15, 16]. Chance of a flap failure is mitigated by designing the flap with an identified perforator in the flap base [17, 18].

The aim of this study was to evaluate the applicability of perforator-plus flaps in the reconstruction of post burn flexion contractures of the knee joint.

## AIMS & OBJECTIVES

The aims and objectives of this study are

1. To evaluate the applicability of perforator-plus flaps in the reconstruction of post burn flexion contractures of the knee joint.
2. To study different types of perforator-plus flaps used in reconstruction of post burn flexion contractures of the knee joint.
3. To evaluate incidence of complications of perforator-plus flaps.
4. To evaluate average hospital stay & overall outcome of patients undergoing perforator-plus flap surgery

## MATERIALS AND METHODS

### Study setting

After getting clearance from the Ethical Committee, the present work was conducted at a tertiary care hospital.

### Time lines

Study was conducted from 1<sup>st</sup> March 2018 to 31<sup>st</sup> October 2019, a 20 month period.

### Definition of study population

Patients in the age group of 10-60y presenting with post-flame burn flexion contractures of the knee joint & managed by a complete incisional or excisional release of the contracture, followed by coverage with local perforator-plus flaps in the Department of Plastic & Reconstructive Surgery.

### INCLUSION CRITERIA

1. Patients in the age group of 10-60yrs
2. Patients presenting with post-flame burn flexion contractures of the knee joint managed by a complete incisional or excisional release of the contracture, followed by coverage with local perforator-plus flaps.
3. Patients undergoing contracture release and reconstruction as an one stage procedure.

### EXCLUSION CRITERIA

1. Patients with age <10yr & >60 yr.

2. Patients with peripheral vascular diseases
3. Patients with known co morbidities which may hinder flap survival( e.g. diabetes)
4. Patients with extensive tissue defects that cannot be covered with fasciocutaneous flaps.

### SAMPLE SIZE

54 patients

### Sampling design

The study was carried out on cases chosen by simple random sampling from all the patients of age group of 10-60yrs. presenting post-flame burn flexion contractures of the knee joint managed by a complete incisional or excisional release of the contracture, followed by coverage with local perforator-plus flaps.

### Study design

Prospective study

### Instruments and equipments used

Standard instruments & equipment used for flap surgery, hand held Doppler with 8Hz probe, goniometer.

### PARAMETERS TO BE STUDIED

1. Age of patient
2. Sex of patient
3. Side of the burn injury (left/right).
4. Duration since burn injury
5. Degree of contracture.
6. Source vessel for the fasciocutaneous flap used for coverage.
7. Flap dimension.
8. Operating time.
9. Duration of hospital stay.
10. Duration of follow up.
11. Early complications
12. Delayed complications.
13. Aesthetic acceptability

### Study tools

1. Consent form
2. Pre-designed Performa
3. Aforesaid equipment & instruments

### Study techniques

The degree of contracture in each patient was assessed with a goniometer and the surface area requiring coverage was estimated by comparing with the normal side. The approximate dimensions of the flap were determined by planning in reverse.

The type of fasciocutaneous flap which had to be raised was then planned. Any perforator which supplied the proposed flap territory was marked with the help of a hand-held Doppler with an 8 Hz probe.

Following contracture release the flap raised by the combination of a sharp and a blunt dissection, thus preserving the supra and the subfascial plexuses.

The perforator(s) at the flap base with a strong intra-operative Doppler signal(s) and a visible pulsation(s) was/were preserved. The skin pedicle was narrowed with back cuts if it was needed, to facilitate the reach and inset without significant dog-ears. The flap inset was then accomplished without any tension on the pedicle. The donor site was covered by a split-thickness skin graft. The flap was covered by a light dressing and the limb was kept elevated post-operatively.

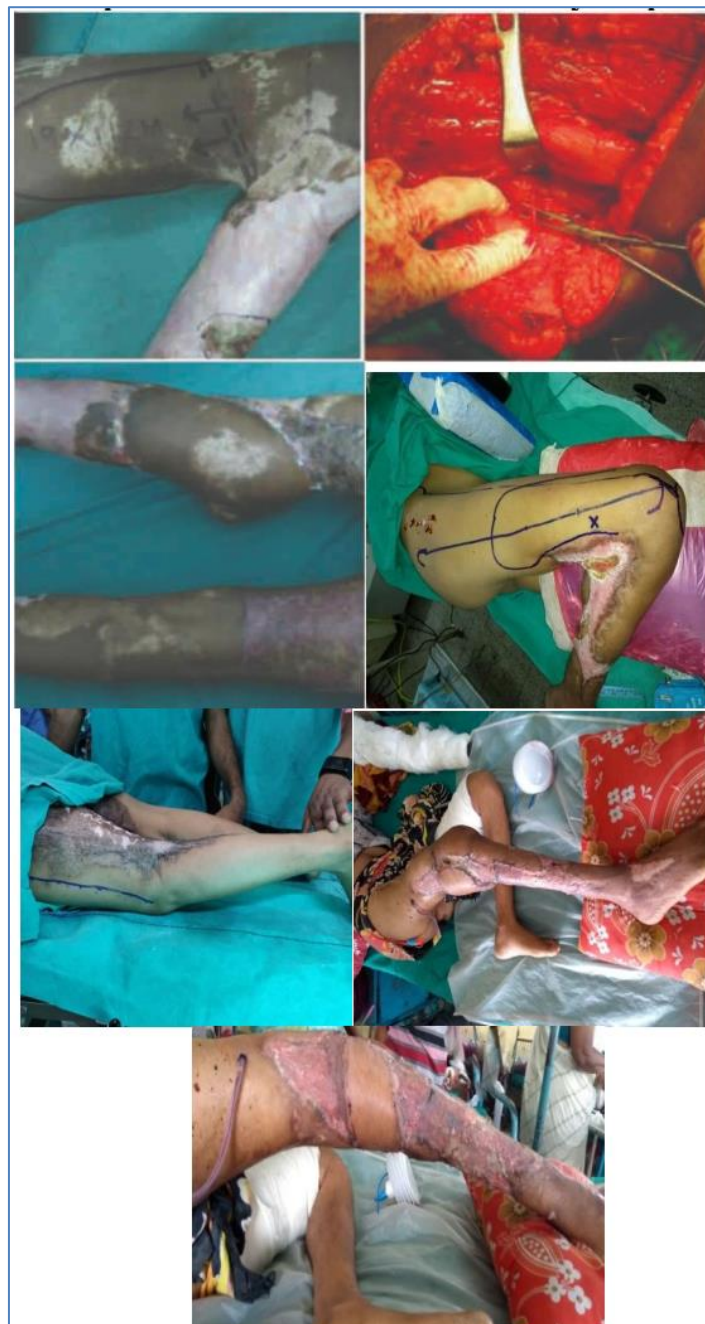Prophylactic antibiotics were given for 5 days. The dressing over the graft was removed on the 5th post-operative day and the sutures were removed on the

10th day. No post-operative splinting was applied. The limb mobilization was began after 1 week and gradual weight-bearing started two weeks post-operatively. The patient was followed up two weekly in the first month after discharge and monthly thereafter, for 6 months.

**Plans for Analysis of Data**

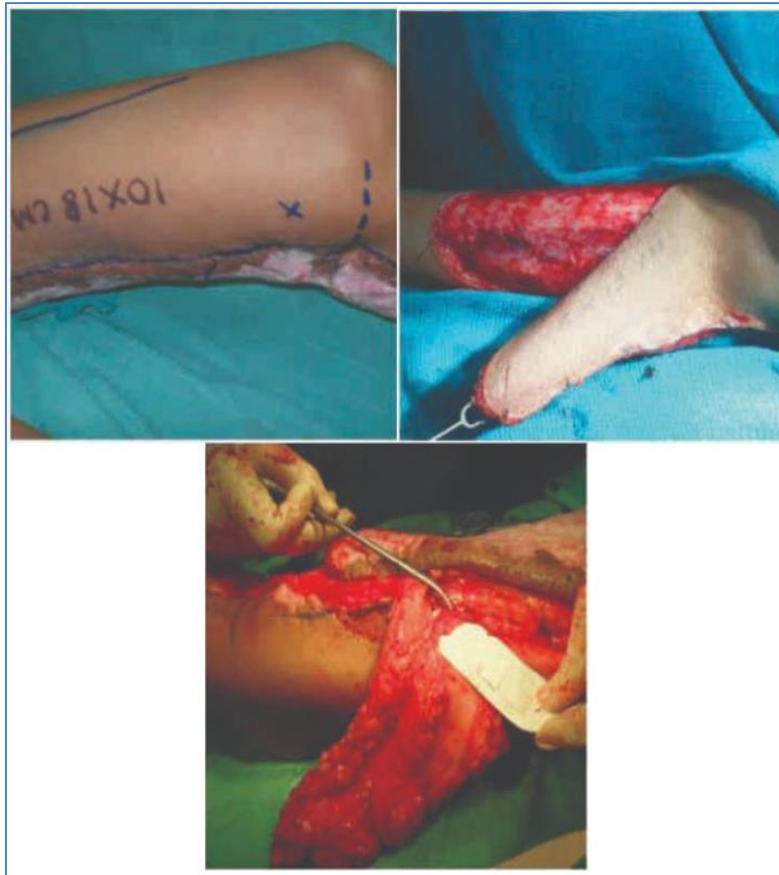Data analysis was done by comparing with other standard studies done previously. The findings were critically studied on the background of present knowledge and the experience of the past work.

**PHOTOGRAPHS**

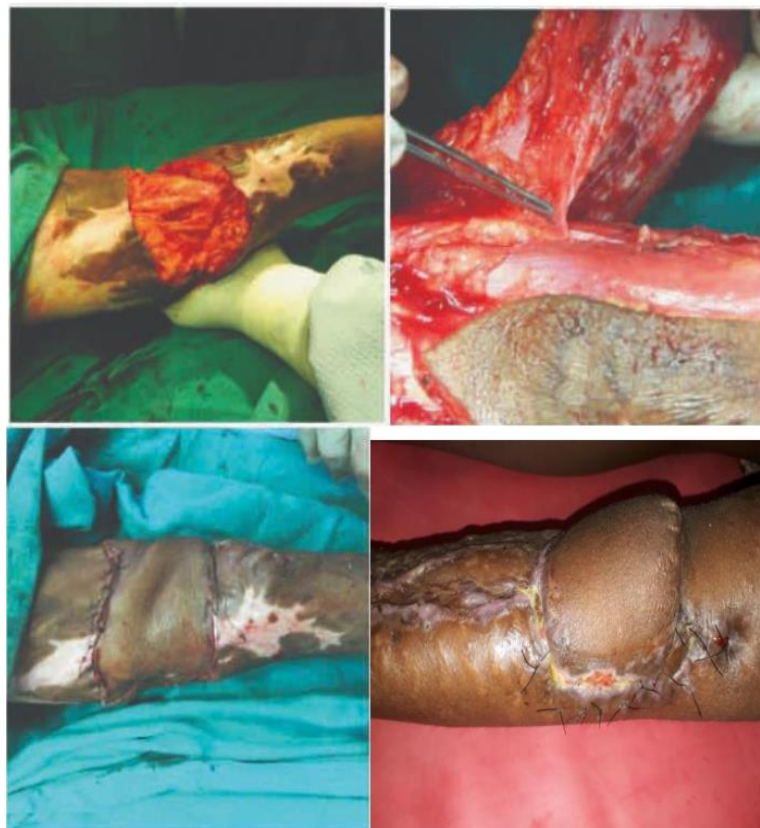

**Superior Lateral Genicular Artery Flap**

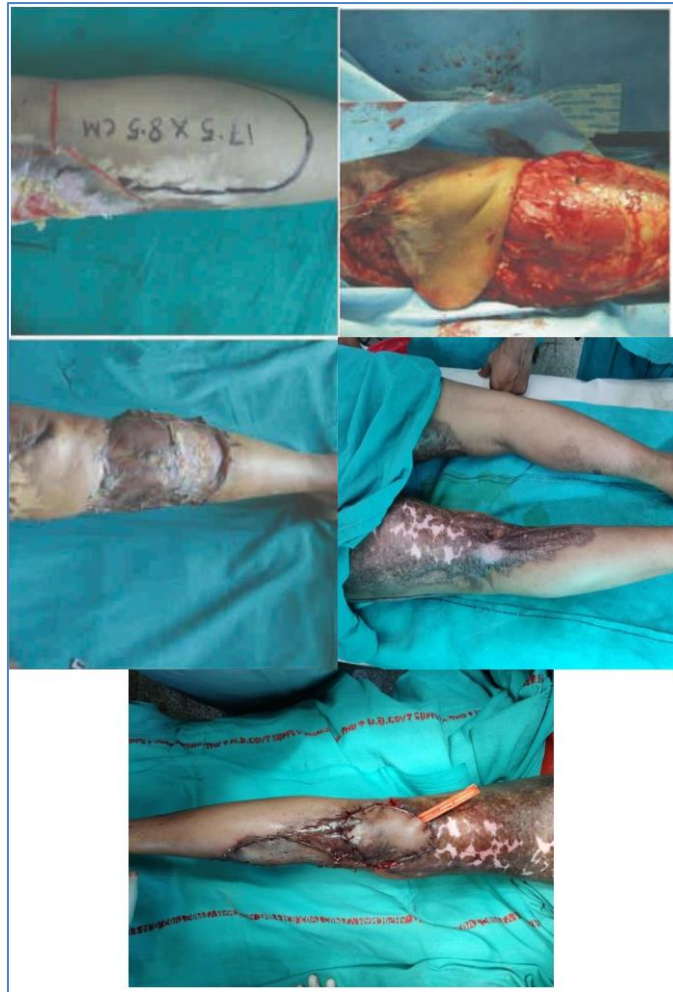



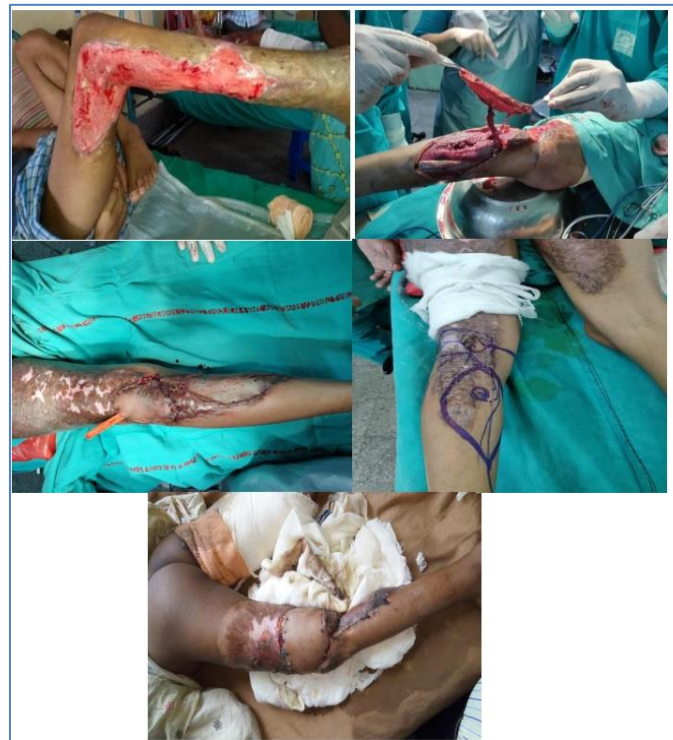**Superior medial genicular artery perforator-plus flap**



**Saphenous artery perforator-plus flap**



**Lateral sural artery perforator-plus flap.**



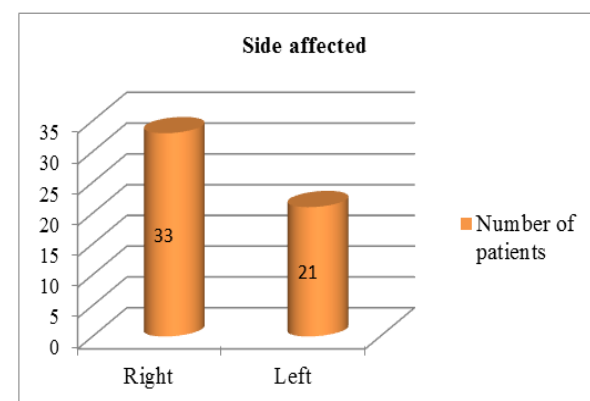
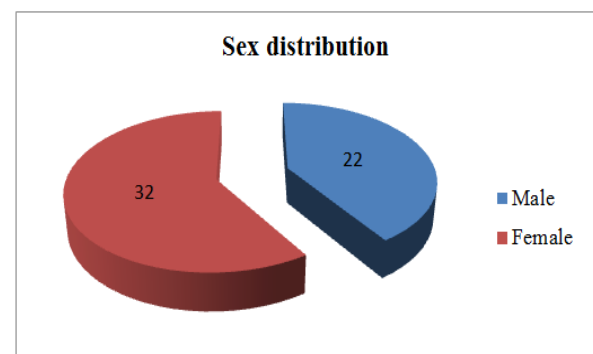
**Medial sural artery perforator flap**

## RESULTS AND ANALYSIS

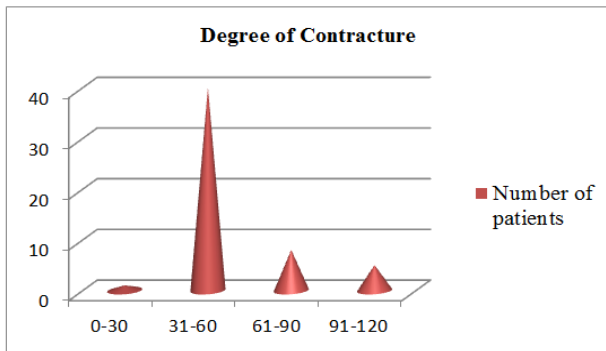
A total of 54 patients of post-flame burn flexion contractures of the knee joints were operated between 1<sup>st</sup> March 2018 to 31<sup>st</sup> October 2019. 33 cases had involvement of the right side, 21 had involvement of the left side. All the patients had flexion contractures of the knee joints, with hypertrophic scarring and a hypopigmentation. Of the 54 patients in the study, 22 were males and 32 were females. The age range of the study population was 14-58 years ( mean -38.3 years ). The duration after the burn injury ranged from 6 to 18 months (mean -10.3 months). The degree of the flexion contracture ranged from 30-120 degrees, with an average of 55.7 degrees. All the cases were operated under spinal or general anaesthesia and they underwent incisional or an excisional complete releases in the prone position and coverage with local fasciocutaneous perforator-plus flaps. All the cases included a single perforator at the base. The pre-operative Doppler assessment of the perforator was done in all cases. The source vessel was the superior medial genicular artery in 14 cases, it was the superior lateral genicular artery in 13 cases, it was the lateral sural artery in 2 cases and the medial sural arteries in 11 cases and it was the saphenous artery in 14 cases. The flap dimensions ranged from 16x8 cm to 10.3x5.5 cm. All the flaps adequately covered the tissue defects over the flexural aspects of the knee joints. They were inset in a tension-free manner, with the maintenance of a good contour, colour and texture match. The operating time spanned from 70 to 128 mins (mean- 100.6 mins). None of the cases needed splintage and all the limbs were mobilized on the 5th post-operative day. The total duration of the hospital stay ranged from 6-14 days (average 10.4 days). Wound infection and dehiscence of the inset sutures occurred in 7 cases. Flap tip necrosis occurred in 5 cases each of superior lateral genicular artery flap and medial sural artery perforator-plus flap and 3 cases of superior medial genicular artery flap and 2 cases of saphenous artery perforator plus flaps. Marginal flap necrosis developed in 3 cases of saphenous artery perforator plus flap, in 2 cases of superior lateral genicular artery flap and in one case each of the medial sural artery perforator-plus flap and superior medial genicular artery flap. There was no venous congestion in any flap. All the local complications were managed under local anaesthesia with debridement and by secondary suturing or healing by secondary intention. There were minor graft losses over the donor sites in 4 cases of saphenous artery perforator plus flaps, 2 cases of superior medial genicular artery flap and 1 case each of medial and lateral sural artery perforator-plus flaps, which were treated conservatively. Two cases of superior medial genicular perforator-plus flap developed paresthesia over the antero-medial thigh, no other case had any significant evidence of a collateral damage like distal limb oedema, sensory loss or muscle weakness. All the patients were followed up for 6 months. 31 cases had some hypertrophic scarring over the grafted areas and 8 cases had dog ear deformity.

However, since none of the patients had any grafts over the flexural aspects of the knees, there were no incidences of recontractures and hence, there was no need of reoperations. The flaps provided a long-term stable pliable coverage over the popliteal fossa with a good colour and texture match and maintenance of the contour. The flaps were not bulky and only one patient desired revision surgery for a dog-ear correction, which was accomplished on an outpatient basis. All the patients, at 6 months follow-up, were satisfied with the function and aethesis of the limbs. They were able to maintain an unassisted symmetrical upright posture and a bipedal locomotion and they could squat without difficulty. Apart from 1 patient, the rest were able to sit crosslegged on the floor without much difficulty.

Age Range (yrs)	Number of patients
10-20	4
21-30	13
31-40	10
41-50	16
51-60	11
<b>Total</b>	<b>54</b>

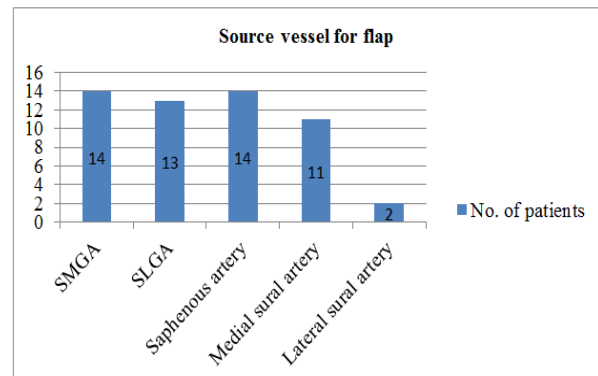


Duration	Number of patients
>1 year	17
<1 year	37
<b>Total</b>	<b>54</b>



Hospital stay	Number of patients
<10 days	22
>10 days	32
<b>Total</b>	<b>54</b>

Operative Time (mins)	Number of patients
<90min	9
>90min	45
<b>Total</b>	<b>54</b>

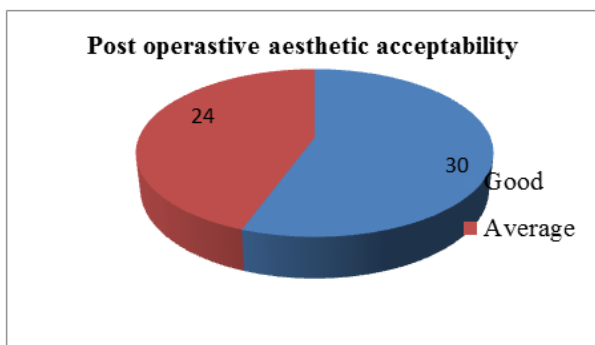


### Early postoperative Complications

Procedure	Flap tip necrosis	Skin graft loss at donor site	Infection	Marginal flap necrosis
SMGA flap	3	2	3	1
SLGA flap	5	0	2	2
Saphenous artery flap	3	4	0	3
Medial sural artery flap	5	1	2	1
Lateral sural artery flap	0	1	0	0
<b>Total</b>	<b>16</b>	<b>8</b>	<b>7</b>	<b>7</b>

### Delayed postoperative complications

Complication	Number of patients
Hypertrophic scar	31
Paresthesia	2
Dog ear deformity	8
<b>Total</b>	<b>41</b>



application for reconstruction following surgical release of post burn flexion contractures of the knee could not be found in the published literature till date. Additionally in an islanded perforator flap the safe length of flap that may be harvested is generally limited to one third of total limb length. It has been observed that risk of flap failure in these cases rises unacceptably (six-fold higher) for greater increase in flap dimensions [21]. For perforator-plus technique it can be postulated that owing to the dual blood supply a flap of larger dimension may be feasible.

## DISCUSSION

An adequately sized perforator can be utilized as the source vessel for the harvest of almost the entire tissues of its corresponding angiosome [19].

Perforator plus flaps are an evolution of flap surgery [13]. This innovative concept results in robust blood supply to the flap via the perforator and the subdermal plexus and also improves the venous drainage of the flap territory [20]. An evaluation of a various of perforator plus flaps specifically in

In the lower limb the distal thigh and the proximal leg serve as the donor region for various perforator plus flaps on account of the rich vascular plexus around the knee joint. The average vessel diameter of the perforators in this region is 0.7mm and the area of skin supplied is around 47 cm<sup>2</sup> [22].

Based on an anatomic knowledge of the location of various perforators and pre operative localization with a hand held Doppler probe, robust and pliable perforator-plus flaps can be harvested to cover



the tissue defects, following a surgical release of the knee contracture.

## CONCLUSION

Post burn scarring, massive edema, thin non-expendable soft tissues in the lower limb are some of the factors which complicate the issue of finding suitable flap coverage options for reconstruction following the release of post burn flexion contractures of the knee. This study evaluates the applicability of perforator-plus flaps for this complex problem with significant functional ramifications for the patient. It can be concluded that perforator-plus flaps are a preferable option in the reconstruction of post burn flexion contractures of the knee joint as:

- It is easy to harvest the flaps.
- Operative duration is around 90-120min.
- Not very bulky & provide better contour.
- These flaps have a constant pedicle so better flap survival.
- Aesthetic acceptability was good in most patients.
- Post operative splinting was avoided in all patients.
- Early mobilization of the joint with very less discomfort.
- Very few postop complications.

## REFERENCE

1. Hawkins, H.K., Pereira, C.T. (2007). Pathophysiology of the burn scar *Total Burn Care 2007 3<sup>rd</sup> ed* Philadelphia Saunders Elsevier, 608-19.
2. Hanumadass, M.L. (2003). Some thoughts on organization of delivery of burn care in India *Indian J Burns*, 11;18-20
3. Su, C. W., Alizadeh, K., Boddie, A., & Lee, R. C. (1998). The problem scar. *Clinics in plastic surgery*, 25(3), 451-465.
4. Chvapil, M., & Koopmann Jr, C. F. (1984). Scar formation: physiology and pathological states. *Otolaryngologic Clinics of North America*, 17(2), 265-272.
5. PH, J. (1950). Cross-leg flaps; a review of 60 cases. *British Journal of Plastic Surgery*, 3(1), 1-5.
6. Cormack, G. C., & Lamberty, B. G. (1985). The blood supply of thigh skin. *Plastic and reconstructive surgery*, 75(3), 342-354.
7. Laitung, J.K. (1989). The lower postero-lateral thigh flap *Br J Plast Surg*, 42(2); 133-39.
8. Maruyama, Y., & Iwahira, Y. (1989). Popliteo-posterior thigh fasciocutaneous island flap for closure around the knee. *British journal of plastic surgery*, 42(2), 140-143.
9. Ghali, S., Bowman, N., & Khan, U. (2005). The distal medial perforators of the lower leg and their accompanying veins. *British journal of plastic surgery*, 58(8), 1086-1089.
10. Topalan, M., Bilgin, S. S., Ip, W. Y., & Chow, S. P. (2003). Effect of torsion on microarterial anastomosis patency. *Microsurgery: Official Journal of the International Microsurgical Society and the European Federation of Societies for Microsurgery*, 23(1), 56-59.
11. Sharma, R. K., Mehrotra, S., & Nanda, V. (2005). The perforator "plus" flap: A simple nomenclature for locoregional perforator-based flaps. *Plastic and reconstructive surgery*, 116(6), 1838-1839.
12. Mehrotra, S. (2010). Perforator plus flaps: optimizing results while preserving function and esthesis. *Indian journal of plastic surgery: official publication of the Association of Plastic Surgeons of India*, 43(2), 141.
13. Wong, C. H., & Tan, B. K. (2007). Perforator-sparing transposition flaps for lower limb defects: anatomic study and clinical application. *Annals of plastic surgery*, 58(6), 614-621.
14. Wong, C. H., & Tan, B. K. (2007). Perforator-plus flaps or perforator-sparing flaps: Different names, same concept. *Plastic and reconstructive surgery*, 120(6), 1746-1747.
15. Roberts, A. H. N., & Dickson, W. A. (1988). Fasciocutaneous flaps for burn reconstruction: a report of 57 flaps. *British journal of plastic surgery*, 41(2), 150-153.
16. Tenenhaus, M., Lukacs, L. A., Ogawa, R., & Rennekampff, H. O. (2008). A brief historical review of flaps and burn reconstruction. *Wounds: a compendium of clinical research and practice*, 20(7), 214-218.
17. Taylor, G. I. (1987). PALMER JH-The vascular territories (angiosomes) of the body: experimental study and clinical applications. *Br J Plast Surg*, 40, 113-141.
18. Sharma, R. K. (2010). Perforator plus flap: evolution of the concept and its place in plastic surgeons repertoire. *Indian Journal of Plastic Surgery*, 43(02), 148-150.
19. Panse, N. S., Bhatt, Y. C., & Tandale, M. S. (2011). What is safe limit of the perforator flap in lower extremity reconstruction? Do we have answers yet?. *Plastic surgery international*, 2011.
20. Blondeel, P. N., Morris, S. F., Hallock, G. G., & Neligan, P. C. (Eds.). (2013). *Perforator flaps: anatomy, technique, & clinical applications*. CRC Press.
21. Zumiotti, A. V., Teng, H. W., Briceño, N. Q., Lotierzo, P. H., Ishida, L. H., Montag, E. D. U. A. R. D. O., & FERREIRA, M. C. (2005). Lateral flap of the thigh based upon the lateral superior genicular artery: An anatomic and histomorphometric study and clinical applications. *Acta ortop bras*, 13(1), 24-27.
22. Wallace, C. G., Kao, H. K., Jeng, S. F., & Wei, F. C. (2009). Free-style flaps: a further step forward for perforator flap surgery. *Plastic and reconstructive surgery*, 124(6S), e419-e426.