

Giant Pleomorphic Adenoma of the Parotid Gland: Case Report

Marouane Balouki^{1*}, Noureddine Errami¹, Bouchaib Hemmaoui¹, Mohammed Zalagh¹, Ali Jahidi¹, Fouad Benariba¹

¹ENT Department, Military Teaching Hospital of Mohammed V, Mohammed V University, Rabat, Morocco

DOI: [10.36347/sasjm.2022.v08i01.002](https://doi.org/10.36347/sasjm.2022.v08i01.002)

Received: 02.12.2021 | Accepted: 07.01.2022 | Published: 14.01.2022

*Corresponding author: Marouane Balouki

ENT Department, Military Teaching Hospital of Mohammed V, Mohammed V University, Rabat, Morocco

Abstract

Case Report

The pleomorphic adenoma (PA) is the most common tumor of the parotid gland. The diagnosis is easy, based on clinical and radiological signs, especially MRI. We report the case of a patient who was 68-year-old with no specific history, had a painless swelling on the right side of her face, gradually increased in size over a period in excess of 20 years. On clinical examination, the parotid mass was firm in consistency, and mobile without fixity to the adjacent structures, it measured 10 cm to 15 cm. The CT Scan revealed a heterogeneous mass of the superficial lobe of the right parotid gland. The treatment was surgical, a right superficial parotidectomy was released under anesthesia general. Histological examination of the operating room confirmed the diagnosis of a pleomorphic adenoma of the parotid without signs of malignancy. The outcomes are favorable; patient woke up without postoperative complications especially no signs of facial palsy. The surgery of the parotid exposes to possible facial paralysis which is widely described in the literature. The PA presents a risk of degeneration after a long period of development. Therefore, early diagnosis and treatment is essential to avoid malignant changes of the mass.

Keywords: Parotid, pleomorphic adenoma, parotidectomy, facial paralysis.

Copyright © 2022 The Author(s): This is an open-access article distributed under the terms of the Creative Commons Attribution 4.0 International License (CC BY-NC 4.0) which permits unrestricted use, distribution, and reproduction in any medium for non-commercial use provided the original author and source are credited.

INTRODUCTION

Pleomorphic adenoma is the most common benign tumor of the parotid gland. It has a tendency of malignant transformation. The surgical excision of this lesion continues is the main treatment. In the case of giant tumors, the mass has a functional, esthetic, and social impact. They raise prognostic issues because of the risk of degeneration. We report a case of a giant pleomorphic adenoma involving the parotid glands and try to explain the reasons for the diagnostic delay and describe therapeutic specificities.

CLINICAL OBSERVATION

It was a 68-year-old patient with no specific history, who presented a painless swelling on the right side of her face, gradually increased in size over a period in excess of 20 years. On clinical examination the parotid mass measured 15 centimeters, it was firm in consistency, and mobile without fixity to the adjacent structures. Despite its large size the looking skin was normal and there was no sign of facial nerve paralysis and no cervical lymphadenopathy (Figure 1).

The CT Scan revealed a heterogeneous mass of the superficial lobe of the right parotid gland, measuring 15 centimeters (Figure 2). Therefore, the

patient underwent a right superficial parotidectomy with preservation of the facial nerve under general anesthesia (Figure 3).

The outcomes are favorable; the patient woke up without postoperative complications especially no signs of facial palsy (Figure 4). Histological examination of the operating room confirmed the diagnosis of a pleomorphic adenoma of the parotid without signs of malignancy.

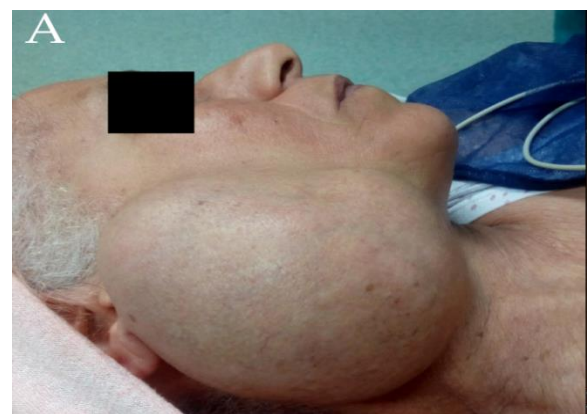

Figure 1: Clinical Photograph to show the right parotid mass measured 15 cm in a 68-year-old female patient

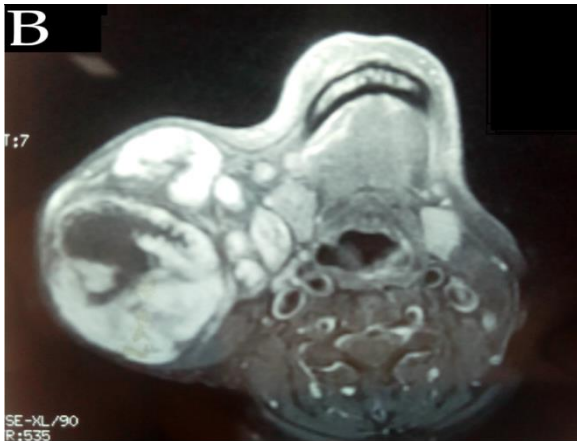


Figure 2: CT scan image in axial section shows a heterogeneous mass of the superficial lobe of the right parotid gland

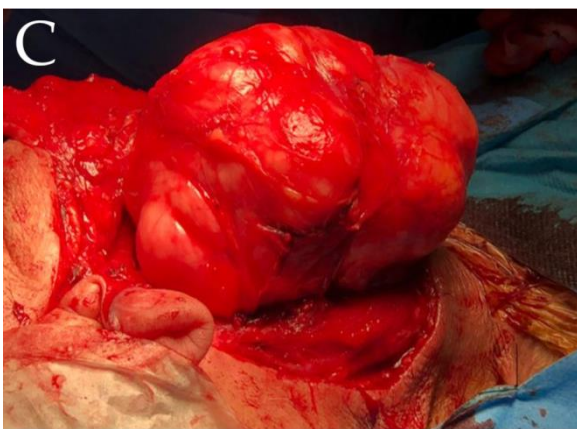


Figure 3: an intraoperative view of a right superficial parotidectomy with preservation of the facial nerve under general anesthesia

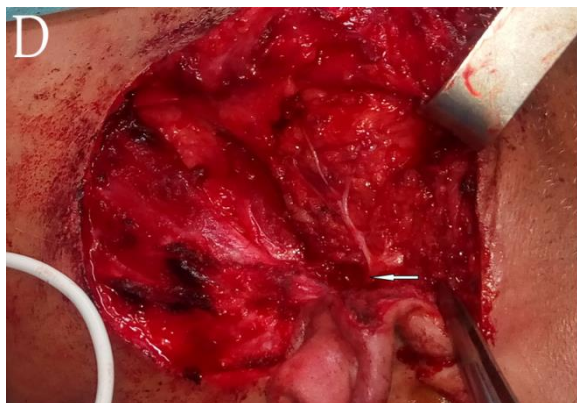

Figure 4: An intraoperative view showing the course of the right facial nerve that was respected during the operation (white arrow)

DISCUSSION

The pleomorphic adenoma (PA) or mixed tumor is the most common epithelial tumors that develop in the glands main salivary [1]. It represents 70 to 80% of tumors benign parotid. This tumor is localized in 90% cases at the level of the superficial lobe of the parotid. She is characterized by its risk of

recurrence and degeneration. The surgery puts you at risk of facial nerve damage.

Giant adenomas they develop slowly, sometimes over 20 years, and appear as a huge nodular mass, sometimes in cauliflower, painless and covered by a stretched and thinned skin [2, 3]. They are heterogeneous in consistency, firm, hard and cystic and are sometimes necrotic, hemorrhagic or with parapharyngeal extension [2, 4, 5].

The absence of facial paralysis, cervical lymphadenopathy or skin infiltration points to a benign tumor. The factors of diagnostic and therapeutic delay are multiple: lack of access to healthcare, financial means, information or refusal of surgery [2]. Standard radiology, CT and MRI make it possible to specify the extension and direct the lesion to benign. Only pathological examination makes the diagnosis [4-6]. Macroscopically, the tumor is usually well circumscribed, bumpy on the surface, and encapsulated in appearance. In cut, it is heterogeneous in appearance with cystic areas, intra tumoral bleeding and fleshy areas [7]. Microscopically, there is a proliferation of epithelial and myoepithelial cells in an abundant myxoid and / or chondroid stroma [2, 3]. The curative treatment is surgical. Parotidectomy The most recommended attitude is total conservative treatment of the facial nerve. Some authors recommend a superficial parotidectomy in case of lesion limited to the superficial lobe [2]. Simple information on the nature of the injury, the potential for development, the advantages of early surgical management could limit the incidence.

CONCLUSION

Untreated pas can enlarge gradually up to several kilograms in weight. These giant adenomas are more common in females and may enlarge over a period of several decades. Some of these long standing tumors show malignant changes. Therefore, early diagnosis and treatment of PA is essential.

Conflict of interest: The authors do not declare any conflict of interest.

Patient consent: informed consent was obtained from the patient.

Ethical Statement: The research was conducted according to the ethical statement

Financial Disclosure: The authors declared no financial support

REFERENCES

1. Achour, I., Chakroun, A., Rhaiem, Z. B., Charfeddine, I., Hammami, B., & Ghorbel, A. (2015). Chirurgie de l'adénome pléomorphe de la parotide. *Revue de Stomatologie, de Chirurgie*

- Maxillo-faciale et de Chirurgie Orale*, 116(3), 129-131.
2. De Silva, M. N., Kosgoda, K. M. S., Tilakaratne, W. M., & Murugadas, P. (2004). A case of giant pleomorphic adenoma of the parotid gland. *Oral Oncology Extra*, 40(3), 43-45.
 3. Kici, S., & Peytral, C. (2001). Adénome pléomorphe géant de la parotide: A propos d'un cas et revue de la littérature. In *Annales d'oto-laryngologie et de chirurgie cervico-faciale* (Vol. 118, No. 5, pp. 330-332).
 4. Rodríguez-Ciurana, J., Rodado, C., Sáez, M., & Bassas, C. (2000). Giant parotid pleomorphic adenoma involving the parapharyngeal space: report of a case. *Journal of oral and maxillofacial surgery*, 58(10), 1184-1187.
 5. Ruiz-Laza, L., Infante-Cossio, P., Garcia-Perla, A., Hernandez-Guisado, J. M., & Gutierrez-Perez, J. L. (2006). Giant pleomorphic adenoma in the parapharyngeal space: report of 2 cases. *Journal of oral and maxillofacial surgery*, 64(3), 519-523.
 6. Auriol, M., & Le Charpentier, Y. (2001). Tumeurs des glandes salivaires. Anatomopathologie. *Encycl Méd Chir, Stomatologie*, 22- 057-B-15 (Paris).
 7. Buenting, J. E., Smith, T. L., & Holmes, D. K. (1998). Giant pleomorphic adenoma of the parotid gland: case report and review of the literature. *Ear, nose & throat journal*, 77(8), 634-640.