

Amyand's Hernia: A Rare Presentation

Mulkipatil S.Y¹, P. Stalin H^{2*}

¹Assistant Professor Department of General Surgery KIMS Hubli, Karnataka, India

²Department of General Surgery, KIMS Hubli, Karnataka, India

*Corresponding author: P. Stalin H

| Received: 26.12.2018 | Accepted: 05.01.2019 | Published: 22.01.2019

DOI: [10.21276/sasjs.2019.5.1.9](https://doi.org/10.21276/sasjs.2019.5.1.9)

Abstract

Case Report

The presence of an appendix in a hernia sac (Amyand's hernia) is a rare entity and the incidence of having an appendix in the hernias sac is less than 1%. Usually, the appendix has been shown to be a part of a sliding hernia and it may be adherent to the sac, most commonly to the mesoappendix rather than the appendix itself and it makes up all or some part of the postero-medial wall of a hernias sac. The clinical presentation varies, depending on the extent of inflammation in the hernia sac and the presence or absence of peritoneal contamination. The presence of vermiform appendix, whether normal or inflamed in the inguinal hernia, is referred to as Amyand's hernia. In the available literature if there is a type 2 Amyand's Hernia then ideal treatment would be appendectomy through hernia followed by primary repair of hernia (no mesh). But in our case we have performed appendectomy of inflamed appendix through the hernia followed by Lichtenstein tension free mesh repair because of high chances of recurrence in the future. Patient has no signs/symptoms of surgical site infection.

Keywords: Amyand's hernia, appendix, inguinal hernia, appendectomy, mesh repair.

Copyright @ 2019: This is an open-access article distributed under the terms of the Creative Commons Attribution license which permits unrestricted use, distribution, and reproduction in any medium for non-commercial use (NonCommercial, or CC-BY-NC) provided the original author and source are credited.

INTRODUCTION

The first description of an appendix in an inguinal hernia is attributed to Amyand (sergeant surgeon to King George I and II) who, in 1735, found a perforated appendix in an 11-year-old boy who presented with a right inguinal hernia and faecal fistula. A vermiform appendix in an inguinal hernia sac, with or without appendicitis, is called Amyand's hernia. This unusual situation is estimated to occur in approximately one percent of adult inguinal hernia cases. The finding of acute appendicitis in Amyand's hernia is much less common. Inguinal hernia repair is one of the most common operations in surgical practice. The surgeon may encounter unusual findings, such as a vermiform appendix partly or fully contained in the hernia sac, inflamed or non-inflamed, stretched or curved, and adhered or not adhered to the sac walls [1-3]. The incidence of Amyand's hernia has varied in the literature, ranging from 0.19% to 1.7% of reported hernia cases. The incidence of appendicitis within an inguinal hernia is even rarer; with an estimated rate at 0.07–0.13% [4].

CASE REPORT

A 50 years old male, heavy worker admitted in our hospital in March 2018 presenting with a right groin swelling since 2 months. He was a known case of

hypertension for he was receiving regular medical treatment. A right groin swelling had been protruding for 2 months prior to hospital admission, which increased in size when standing and reduced on sleeping. Mild pain had been noted for 1 week. Our impression was reducible inguinal hernia and the patient was admitted for surgical intervention. Blood pressure was well controlled. Laboratory data were within normal limits. Ultrasound revealed indirect reducible inguinal hernia with defect size of 1.5cms and bowels as contents. The patient was scheduled for elective surgery. The oblique conventional incision was used to achieve a better approach.

Intraoperative findings

- Indirect hernial sac was identified.
- For our surprise an appendix was found completely within the indirect sliding hernia sac.
- Appendix was mildly inflamed and base of the appendix was healthy.
- The mobilized caecum and ascending colon were far away from the paracolic space, apparently sliding until occupying the neck of the hernial sac.

Procedure

Appendectomy was performed after opening the hernial sac, hemostasis was achieved and wound

was washed with normal saline and betadine solution. Lichtenstein tension free mesh repair was done with prolene mesh 5x10cms. The patient's postoperative condition was uneventful and he was discharged on the post op day 2. He was followed up at our OPD one

week later and the surgical area looked healthy with no signs of surgical site infection. Pathology revealed an acute appendicitis with mixed inflammatory cells in the appendiceal wall, presenting many eosinophils and small foci of granulomatous lesion.

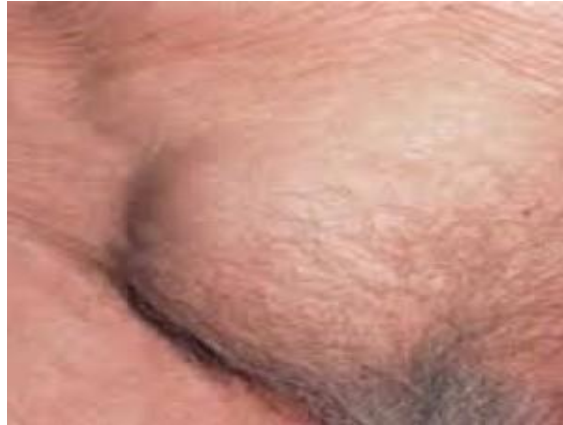

Fig-1: Preoperative image of right inguinal hernia

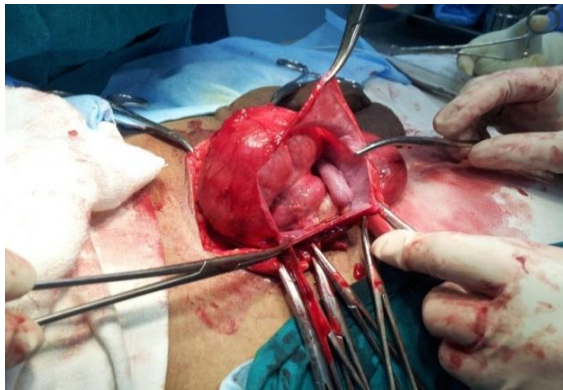

Fig-2: Intraoperative image showing appendix as hernial sac content

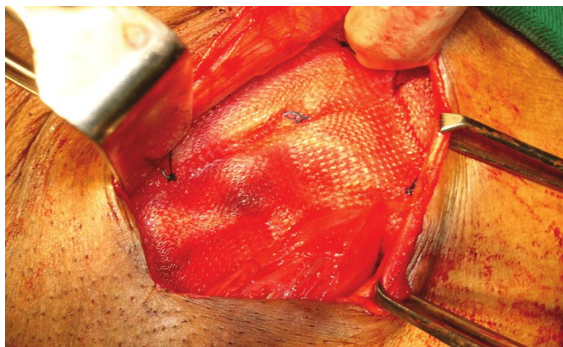


Fig-3: Mesh repair with prolene mesh

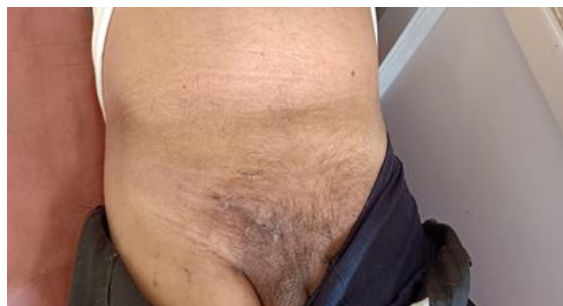

Fig-4: Post op image (after 1 month) showing surgical site healed by primary intention

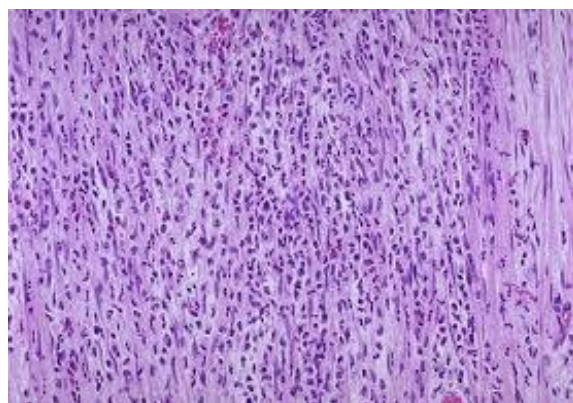


Fig-5: Microscopy image of appendectomy specimen

DISCUSSION

Acute appendicitis within an inguinal hernia accounts for 0.1% of all cases. Inflammation of the appendix is attributed to external compression of the appendix at the neck of the hernia. The inflammatory status of the vermiform appendix determines the surgical approach and the type of hernia repair. Most literatures agree that if appendicitis exists, the repair of the hernia should be performed with Bassini or Shouldice techniques, without making use of synthetic meshes or plugs within the defect due to the high risk of suppuration of such materials. In the case of a normal appendix, incidentally found within the hernia sac, the performance of a prophylactic appendectomy along with the hernia repair is not favored by many authors. Appendectomy adds the risk of infection to an otherwise clean procedure. Superficial wound infection

increases morbidity; and deep infection may contribute to hernia recurrence. In addition, surgical manipulation to achieve visualization of the entire appendix and its base, by enlarging the hernial defect or distending the neck of the hernial sac, increases the possibility of recurrence by weakening the anatomic structures around the defect. There are authors who recommend reduction of the appendix and mesh hernioplasty if there is no acute appendicitis, and appendectomy followed by endogenous hernia repair if an inflamed appendix is found.

Although these general rules are certainly acceptable, there are more clinical scenarios to keep in mind. Losanoff and Basson have distinguished four basic types of Amyand's hernias, which should be treated differently.

Classification	Description	Surgical management
Type 1	Normal appendix within an inguinal hernia	Hernia reduction, mesh repair, appendectomy in young patients
Type 2	Acute appendicitis within an inguinal hernia, no abdominal sepsis	Appendectomy through hernia, primary repair of hernia, no mesh
Type 3	Acute appendicitis within an inguinal hernia, abdominal wall, or peritoneal sepsis	Laparotomy, appendectomy, primary repair of hernia, no mesh
Type 4	Acute appendicitis within an inguinal hernia, related or unrelated abdominal pathology	Manage as types 1 to 3 hernia, investigate or treat second pathology as appropriate

The absence of inflammation in Type 1 advocates elective hernioplasty. Using a prosthetic material in such cases carries the expectation of improved longevity of the repair. It avoids tension on the suture lines and circumvents the metabolic problems related to collagen deficiency, which is known to exist in hernia patients. Whether to remove or leave behind a normal appendix in this clinical scenario cannot be determined because no evidence-based information exists. The decision is rather based on surgeon's choice relating to the patient's age, life expectancy, and life-long risk of developing acute appendicitis and the size and overall anatomy of the appendix. Pediatric or

adolescent patients have a significantly higher risk of developing acute appendicitis and should therefore have their appendices removed, compared to middle-aged or elderly individuals in whom the appendix should probably be left intact. Long, curved appendices have a higher risk of inflammation. Additionally a long appendix which stretches the cecum may cause chronic pain if left behind. Manipulations to detach and reduce the appendix in the abdomen may stimulate the inflammatory process. Velimezis et al. identified a 78-year-old man with a recurrent hernia and an inflamed non-perforated vermiform appendix that was subsequently resected and due to the recurrence

necessitated a tension free hernia repair with a successful outcome and no signs of infection or recurrence up to 36 months follow up [5]. Ali et al describes three cases of type 2 Amyand's hernia, similar to our case, that was successfully treated with an appendectomy and tension free hernia repair with no surgical site infections or signs of recurrence in follow up of one month to three years Amyand's hernia, which necessitated [6]. Furthermore, consideration of appendectomy in young patients must take into account the size of the hernia, since prosthetic material is contraindicated but large hernias are more likely to recur if repaired by making use of endogenous tissue only.

CONCLUSION

In the available literature if there is a type 2 Amyand's Hernia then ideal treatment would be appendectomy through hernia followed by primary repair of hernia (no mesh). But in our case we have performed appendectomy of inflamed appendix through the hernia followed by Lichtenstein tension free mesh repair because of high chances of recurrence in the future considering patients occupation. Moreover postoperatively there were no signs/symptoms of surgical site infection. In conclusion; a hernia surgeon may encounter unexpected intraoperative findings, such as an Amyand's hernia. The decision as to whether one should perform a simultaneous appendectomy and hernia repair is multifactorial. It is important to be aware of all clinical settings and an appropriate and individualized approach should be applied.

REFERENCES

1. House MG, Goldin SB, Chen H. Perforated Amyand's hernia. *South Med J*. 2001;94:496–98.
2. Logan MT, Nottingham JM. Amyand's hernia: a case report of an incarcerated and perforated appendix within an inguinal hernia and review of the literature. *Am Surg*. 2001;67:628–29.
3. D'Alia C, Schiavo ML, Tonante A, Taranto F, Gagliano E, Bonanno L, Di Giuseppe G, Pagano D, Sturniolo G. Amyand's hernia: case report and review of the literature. *Hernia*. 2003 Jun 1;7(2):89-91.
4. Sharma H, Gupta A, Shekhawat NS. Amyand's hernia: a report of 18 consecutive patients over a 15-year period. *Hernia*. 2007;11:31–35.
5. Velimezis G, Vassos N, Kapogiannatos G, Koronakis D, Perrakis E, Perrakis A. Incarcerated recurrent inguinal hernia containing an acute appendicitis (Amyand hernia): an extremely rare surgical situation. *Archives of medical science: AMS*. 2017 Apr 1;13(3):702.
6. Ali SM, Malik KA, Al-Qadhi H. Amyand's hernia: study of four cases and literature review. *Sultan Qaboos University Medical Journal*. 2012 May;12(2):232.