

Case Report of Transient Abnormal Myelopoiesis in New-born with Down's Syndrome

Dr. Hiral Shah (MD Pathology)^{1*}, Dr Tulsi Jariwala (M.B.B.S D.C.P)¹, Dr. Tejal Chaudhari (M.B.B.S D.C.P)²

¹Consultant at Desai Metropolis Health Services Pvt. Ltd, Surat, and Gujarat, India

²Consultant at Desai Metropolis Health Services Pvt. Ltd, Navsari, and Gujarat, India

DOI: [10.36347/sjmcr.2022.v10i02.002](https://doi.org/10.36347/sjmcr.2022.v10i02.002)

Received: 19.12.2021 | Accepted: 26.01.2022 | Published: 04.02.2022

*Corresponding author: Dr. Hiral Shah

Consultant at Desai Metropolis Health Services Pvt. Ltd, Surat, and Gujarat, India

Abstract

Case Report

Introduction: A unique white cell abnormality called transient abnormal myelopoiesis [TAM] is found in approximately 10% of neonates with Down's syndrome. **Material & method:** Medical record of a case of confirmed TAM in Down's syndrome was reviewed in retrospect at Desai Metropolis laboratory. The co-relation of prenatal ultrasonographic findings, maternal screen results, fetal blood analysis, flow cytometry, karyotyping and the postnatal clinical course were done. **Result:** A case of TAM associated with Down's syndrome was confirmed in November 2021. A complete blood count done on 2nd day of life showed abnormal leukocytosis with blast cells. TAM spontaneously resolved after 15 days of birth. **Conclusion:** Fetal TAM is a self-limiting condition which requires supportive care. In the neonatal period, most cases of TAM have a favorable outcome from this preleukemic condition, but some progress to leukemia. Investigation of TAM will continue to strongly influence basic and clinical research into development of hematological malignancies.

Keywords: Transient abnormal myelopoiesis, Down's syndrome, Immunophenotype.

Copyright © 2022 The Author(s): This is an open-access article distributed under the terms of the Creative Commons Attribution 4.0 International License (CC BY-NC 4.0) which permits unrestricted use, distribution, and reproduction in any medium for non-commercial use provided the original author and source are credited.

INTRODUCTION

A unique white cell abnormality called transient abnormal myelopoiesis [TAM] is found only in fetuses with Down's syndrome [1].

It manifests in approximately 10% of neonates with Down's syndrome [2]. Two forms of megakaryocytic leukemia namely transient abnormal myelopoiesis (TAM) and acute megakaryoblastic leukemia (AMKL) are seen frequently in such children [3].

The pathophysiology of TAM involves a number of factors, including the proliferation of abnormal hematopoietic precursors in the fetal liver caused by genetic instability in the presence of trisomy 21 and by the acquisition of mutations in the GATA1 gene, located on chromosome X, which is essential for erythroid and megakaryocytic maturation [4].

MATERIAL & METHOD

We report a case of a male infant, born to a mother with a positive screen for Trisomy 21, having marked leukocytosis with few immature cells and 50% blast cells in peripheral blood at 2nd day of life. Complete work up was done and the phenomenon of transient abnormal myelopoiesis (TAM) was confirmed by immunophenotyping using flow-cytometry. The co-relation of prenatal ultrasonographic findings, maternal screen results, fetal blood analysis, flow cytometry, karyotyping and the postnatal clinical course were done. This is a self-limiting condition which requires supportive care and it resolves within few months.

CASE

We received a case of 2 days old male child, whose post-natal peripheral blood showed significant leukocytosis with blasts, immature cells and thrombocytosis.

| <i>Erythrocytes</i> | |
|----------------------------|--------------------|
| Hemoglobin | 14.8 gm/dL |
| RBC Count | 4.25 mill/cu.mm |
| PCV | 46.70% |
| MCV | 110 fL |
| MCH | 34.8 pg |
| MCHC | 31.6 g/dL |
| RDW | 21.40% |
| Nucleated RBC | 90 per 100 WBCs |
| <i>Leucocytes</i> | |
| Total Leucocytes count | 48,600 cells/cu.mm |
| Blasts | 50% |
| Myelocyte | 2% |
| Neutrophils | 34% |
| Lymphocytes | 10% |
| Monocytes | 3% |
| Eosinophils | 1% |
| Basophils | 0% |
| <i>Platelets</i> | |
| Platelet count | 7,32,000 / μ l |
| MPV | 8.7 fL |

In the physical examination, the pediatrician observed typical Down's syndrome faces. He was admitted to the neonatal intensive care unit and treated by supportive care. During admission, he developed jaundice with elevated liver function test results. Blood

gas analysis revealed mild acidosis with normal serum electrolytes and normal CRP.

The result of a Complete Blood Count is shown in Table

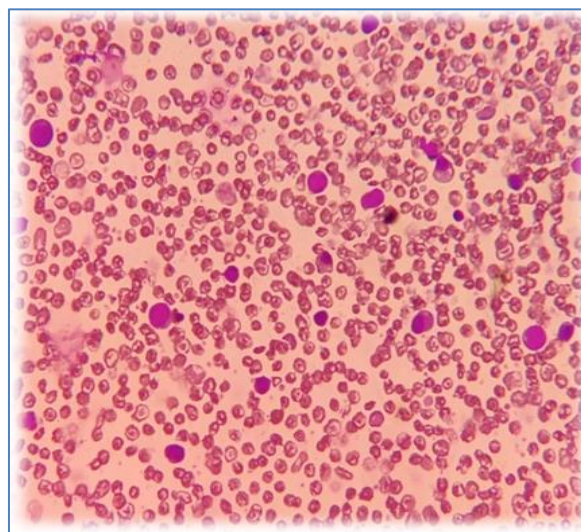


Image shows PAS positivity in BLASTS

The Immunophenotypes of blast cells in this case showed following results

| Markers | Inference on gated cells | Intensity |
|-----------------------|--------------------------|-----------|
| B CELL MARKERS | | |
| CD 19 | Negative | |
| CD20 | Negative | |
| cCD79a | Negative | |
| T CELL MARKERS | | |
| cCD3 | Negative | |
| sCD3 | Negative | |
| CD7 | Positive | DIM |
| CD5 | Negative | |
| CD4 | Positive | DIM |

| MYELOID AND OTHER MARKERS | | |
|---------------------------|----------|-----------------|
| cMPO | Negative | |
| CD117 | Positive | DIM to MODERATE |
| CD13 | Negative | |
| CD33 | Positive | DIM to MODERATE |
| CD15 | Negative | |
| CD11b | Negative | |
| HLA - DR | Positive | DIM |
| CD64 | Negative | |
| CD14 | Negative | |
| CD10 | Negative | |
| TdT | Positive | |
| CD34 | Positive | HETEROGENOUS |
| CD56 | Positive | HETEROGENOUS |
| CD38 | Positive | HETEROGENOUS |
| CD36 | Positive | VARIABLE |
| CD45 | Positive | DIM to MODERATE |
| CD123 | Negative | |
| cCD41 | Positive | |
| cCD61 | Positive | |

The Flowcytometric analysis revealed abnormal mega-karyoblasts. Findings favored clinical

diagnosis of abnormal transient myelopoiesis associated with Down's syndrome.

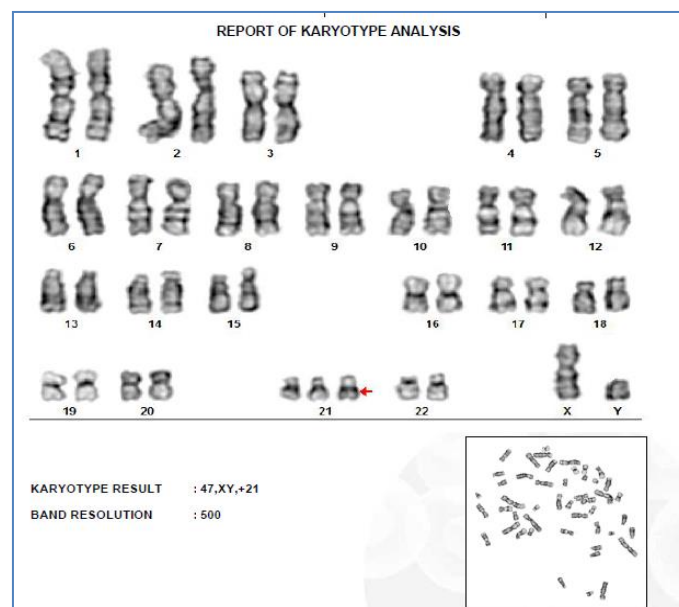


Image shows leucoerythroblastic picture with BLASTS and nRBCs

The diagnosis of Down's syndrome was confirmed by karyotyping which revealed 47, XY+21. The patient was treated in ICU for 15 days. The blood picture on 15th day showed normal WBC counts and only few reactive cells, while the immature series disappeared. Hence, the condition spontaneously resolved. But unfortunately he had ineffective sucking which eventually led to aspiration pneumonitis. The neonate died from pneumonia with sepsis at the age of 12 weeks.

DISCUSSION

Generally, children with Down's syndrome have a 10-fold higher risk of developing acute leukemia compared with normal children [5].

TAM is a unique haematological abnormality that is found in fetuses with Down's syndrome or Down's syndrome mosaicism [1, 6]. In our case diagnosis of Down's syndrome was confirmed by karyotyping which revealed 47, XY+21. The same karyotype was reported by Wirada *et al.* [7], Gosavi *et al.* [8] and Bianca *et al.* [9].

A peripheral blood smear report of TAM is characterized by numerous blast cells, and the numbers of neutrophils and lymphocyte are normal or slightly decreased. The peripheral smear studies by Wirada *et al.* [7], Gosavi *et al.* [8] showed 77% (Case 1) 64% (case 2); 44% blasts respectively on examination. We examined 50% Blasts, 39 % Neutrophils and 10 % lymphocytes in our case. The platelet count in TAM

may be normal, decreased or significantly increased. In our case, thrombocytosis was found.

From immunophenotypic and cytological aspects, TAM has similar features to the most common type of acute myeloid leukemia in children with Down's Syndrome, acute Megakaryoblastic leukemia [10]. The immunophenotypes of blast cells in our case were CD 34+ and dimly CD33+, which are markers for early myeloid cells. The CD7 marker expressed by T-cell antigens was also seen. CD41 and CD61, the megakaryocytic markers were also found to be positive.

Along with this markers like CD 117, CD 56, CD 38, CD 45, HLA- DR were also positive. Wirada *et al.* [7] reported CD 34+ and dimly CD33+ blast cells, but CD41 and CD61 were negative in their case report.

Gosavi *et al.* [8] reported: The blasts were positive for CD34, HLA-DR, CD117, CD61 and CD41 by flow cytometry, indicating megakaryoblastic lineage.

Bianca *et al.* [9] reported: PB: 23% cells CD45+/, CD34+, CD117+, HLA-DR+, CD33+, CD7+ and CD56+, precursor cells in PB without antigen-specific expression of lineage suggestive of TAM associated with DS.

The prognosis of TAM is good, in most children. TAM spontaneously resolves within three months [11]. As this is a self-limiting condition which requires only supportive care. TAM spontaneously resolved in our case after 15 days of birth. But unfortunately, neonate died at the age of 12 weeks.

RESULT

A case of TAM associated with Down's syndrome was confirmed in November 2021. A complete blood count done on 2nd day of life showed abnormal leukocytosis with blast cells. TAM spontaneously resolved after 15 days of birth.

CONCLUSION

Fetal TAM is a self-limiting condition which requires supportive care. In the neonatal period, most cases of TAM have a favorable outcome from this preleukemic condition, but some progress to leukemia. Investigation of TAM will continue to strongly influence basic and clinical research into development of hematological malignancies.

REFERENCES

1. Malinge, S., Izraeli, S., & Crispino, J. D. (2009). Insights into the manifestations, outcomes, and mechanisms of leukemogenesis in Down syndrome. *Blood, the Journal of the American Society of Hematology*, 113(12), 2619-2628.
2. Van den Akker, T.A., Geyer, J.T. Transient abnormal myelopoiesis associated with Down's syndrome. PathologyOutlines.com website. <https://www.pathologyoutlines.com/topic/leukemiaTAM.html>.
3. Zipursky, A., Poon, A., & Doyle, J. (1992). Leukemia in Down syndrome: a review. *Pediatric hematology and oncology*, 9(2), 139-149.
4. Bhatnagar, N., Nizery, L., Tunstall, O., Vyas, P., & Roberts, I. (2016). Transient abnormal myelopoiesis and AML in Down syndrome: an update. *Current hematologic malignancy reports*, 11(5), 333-341.
5. Xavier, A. C., & Taub, J. W. (2010). Acute leukemia in children with Down syndrome. *haematologica*, 95(7), 1043.
6. Brodeur, G. M., Dahl, G. V., Williams, D. L., Tipton, R. E., & Kalwinsky, D. K. (1980). Transient leukemoid reaction and trisomy 21 mosaicism in a phenotypically normal newborn.
7. Wirada Hansahiranwadee, M. D., Chayada Tangshewinsirikul, M. D., & Panyu Panburana, M. D. (2018). Case Report of Transient Abnormal Myelopoiesis in Fetuses with Down syndrome. *Journal of the medical association of thailand*, 679.
8. Gosavi, A. V., Murarkar, P. S., Lanjewar, D. N., & Ravikar, R. V. (2011). Transient leukemia in Down syndrome: report of two cases with review of literature. *Indian Journal of Hematology and Blood Transfusion*, 27(3), 172-176.
9. Falasco, B. F., Durante, B., Faria, D. K., Faria, C. S., Rosolen, D. C. B., & Antonangelo, L. (2019). Transient abnormal myelopoiesis with pericardial effusion in Down syndrome: Case report. *Clinical case reports*, 7(7), 1280-1284.
10. Massey, G. V., Zipursky, A., Chang, M. N., Doyle, J. J., Nasim, S., Taub, J. W., & Weinstein, H. J. (2006). A prospective study of the natural history of transient leukemia (TL) in neonates with Down syndrome (DS): Children's Oncology Group (COG) study POG-9481. *Blood*, 107(12), 4606-4613.
11. Carpenter, E., Valverde-Garduno, V., Sternberg, A., Mitchell, C., Roberts, I., Vyas, P., & Vora, A. (2005). GATA1 mutation and trisomy 21 are required only in haematopoietic cells for development of transient myeloproliferative disorder. *British journal of haematology*, 128(4), 548-551.