

Haemolytic Anemia due to Paravalvular Leak Following Mitral and Aortic Valves Replacement

Laila Chemaou El Fihri^{1*}, Aassim Benbahia¹, Mustapha El Hattouai¹¹Department of Cardiology, University Hospital Center Mohammed VI of Marrakech, MoroccoDOI: [10.36347/sjmcr.2022.v10i02.004](https://doi.org/10.36347/sjmcr.2022.v10i02.004)

| Received: 24.12.2021 | Accepted: 31.01.2022 | Published: 04.02.2022

*Corresponding author: Laila Chemaou El Fihri

Department of Cardiology, University Hospital Center Mohammed VI of Marrakech, Morocco

Abstract

Case Report

PVL is the flow of blood through a track between the native cardiac tissue and the implanted valve and it can complicate mitral and aortic valves replacement. Patients with PVL may experience varying clinical repercussion from absence of symptoms to congestive heart failure and /or significant hemolysis with hemolytic anemia. PVLs are more frequently diagnosed by Transesophageal echocardiography than transthoracic echocardiography due to its ability to detect minute jets of regurgitated blood. Reoperation for closure of PVL is associated with high mortality. Transcatheter closure is less invasive and can be used in high-risk patients. We present a case of a 67-year-old woman with a history of Aortic and mitral Valves replacement who developed hemolytic anemia and haemoglobinuria. The patient was managed initially conservatively but later underwent redo valve surgery after exclusion of other causes of hemolytic anemia. Post operatively her level of hemoglobin and her urine routine examination were normal.

Keywords: Paravalvular leak; Hemolytic anemia; Aortic valve replacement; Mitral valve repair.

Copyright © 2022 The Author(s): This is an open-access article distributed under the terms of the Creative Commons Attribution 4.0 International License (CC BY-NC 4.0) which permits unrestricted use, distribution, and reproduction in any medium for non-commercial use provided the original author and source are credited.

INTRODUCTION

Paravalvular regurgitation (PVL)-leakage from around the prosthesis- is the most common cause of non-structural prosthetic heart valve dysfunction [1]. PVL affects up to 17% of all prosthetic heart valves implanted by conventional surgery. Fortunately, approximately 90% are mild and clinically insignificant [2].

Patients with PVL may experience varying clinical repercussion from absence of symptoms to congestive heart failure and /or significant hemolysis with hemolytic anemia requiring iterative transfusions. PVL developing during follow-up may be secondary to suture dehiscence or as a consequence of valvular endocarditis and may be suspected at physical examination in the presence of a new murmur.

Assessment and quantification of these paravalvular leaks are difficult since transthoracic color flow Doppler images may be obscured by annular calcifications and prosthetic material. Transesophageal echocardiography (TEE) greatly improved the detection and assessment of PVL.

CASE PRESENTATION

A 67-year-old woman known hypertensive was operated for double valve replacement (DVR) with an ATS mechanical aortic and mitral valves implantation, on March 2018 by open heart surgery. She was discharged from hospital two weeks later. She presented one month later severe anemia (Hb of 4.4 g/dl), hematuria and rectal bleeding; the case was discussed with cardiac surgeon who suggested to exclude other etiologies that might explain the patient's condition, so she was managed conservatively and transfused with four packed red blood cells (PRBCs). At clinical exam new soft systolic mitral murmur could be heard. Her peripheral blood film showed normocytic normochromic blood picture with red cell fragmentation. Complement reactive protein (CRP) was 43 mg/l with a negative procalcitonin test (0, 18 ng/ml). International normalized ratios (INR) was 1, 37. Her liver function tests showed serum Bilirubin 23 mg/l, Alanine Aminotransferase (ALT) 31 U/l and serum Alkaline Phosphates 49 U/l. His Lactic dehydrogenase was 2826 U/l. She was investigated for hemolytic anemia due to presence of schistocytes in peripheral blood smear. Coomb's tests were negative. Her urine Routine Examination (RE) showed leukocyturia and RBC casts with a negative urine

culture. Cystoscopy was normal. Urologist consultation ruled out any urological pathology. Computed Tomography (CT) abdomen was unremarkable. Colonoscopy revealed an ischemic colitis stage I. She had to be transfused once a week with 1-2 PRBCs/week. Transthoracic Echocardiography revealed normally functioning Mitral and aortic valves prosthesis with moderate paravalvular mitral leak [Figure 1].

Transesophageal Echocardiography showed normally functioning mechanical mitral valve with severe paravalvular regurgitation (two jets) [Figure 2]. She was planned to redo surgery with new bio prosthetic mitral and Aortic valves. Post operatively her level of hemoglobin and her urine routine examination were normal.

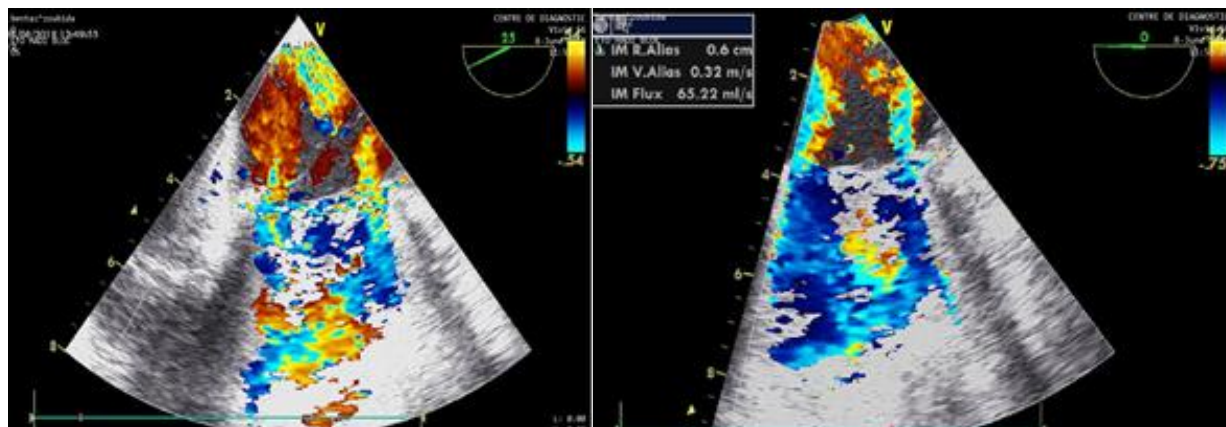


Figure 2: Transesophageal Echocardiography showing severe paravalvular leaks (two jets) from the mitral valve

DISCUSSION

Surgically implanted prosthetic valves are complicated with paravalvular leaks in 17% [3]. Most paravalvular leaks remain clinically silent. However 1–3% of the patients are symptomatic and require re-intervention [3]. Paravalvular leaks clinically manifest themselves with symptoms of congestive heart failure, hemolysis, infectious endocarditis or a combination of these. Hemolysis is one of the potentially serious complications of prosthetic heart valves. In 1975 Kloster reported the incidence of hemolysis in patients with prosthetic valves to be between 5 and 15% [4], Dhasmana *et al.*, reported an incidence of 7% in 1983 [5]. Hemolytic anemia can result from turbulent flow and shear stress on the red blood cells (RBC) following heart valve replacement. In our case we assume that hemolysis was caused by the presence of a metal mesh and a high shear stress in the jet next to this device. This assumption was confirmed by the disappearance of hemolysis after the removal of the device and the closure of the paravalvular leak.

PVL can vary in shape, size and tract. It can be crescentic, oval or round shaped and can have parallel, perpendicular or serpiginous track. It is more commonly seen in mechanical valves than in bio prosthetic valves. Our patient developed PVL after placement of aortic and mitral mechanical valves. PVL has been reported including small non-significant jets to 20% of regurgitated blood. PVL is also more frequently seen after mitral (up to 20%) valve replacement than aortic prosthetic valves. There was a severe Para prosthetic leak from mechanical mitral valve in our patient.

Transesophageal echocardiography (TEE) is the gold standard technique to establish the PVL diagnosis and to assess the degree of paravalvular regurgitation (PVR), [6, 7]. Two-dimensional (2D)-TEE is Very sensitive in accurately identifying the presence of PVL (88%) [8]. However, to assess the number, extent, shape and exact anatomic allocation of the PVL can be very challenging [9]. Several studies have demonstrated the concordance between 3D-TEE images and the real anatomy, and the superiority of 3D-TEE over 2D-TEE in PVL evaluation [10-12].

Surgical closure of paravalvular leaks is the most common therapy for these defects. However, depending on the number of patient comorbidities, redo surgery is limited, due to a high recurrence rate as well as high morbidity and mortality rates and is not always successful because of underlying tissue fragility, inflammation or extensive calcifications.

Since first reported by Hourihan *et al.*, in 1992, percutaneous closure of periprosthetic paravalvular leaks has been proposed as an alternative to repeat surgery for a selected high risk population [3]. Transcatheter paravalvular leak-closure procedures are still evolving.

They are associated with very low procedural mortality rates but are technically challenging variably effective and may require multiple interventions to be clinically successful. Our patient was initially addressed for transcatheter PVL closure which was not performed considering technical problems but she finally had a successful surgical repair with an uneventful recovery

CONCLUSION

Paravalvular leak with hemolytic anemia is one of the complications in patients with prosthetic valves. Transcatheter closure of paravalvular leak with devices is one of the treatment options. Surgery remains the treatment of choice in severe cases of hemolytic anemia with multiple paravalvular leaks or significant residual paravalvular leak after device closure. Successful PVL closure not only corrects valvular regurgitation but also intravascular hemolysis.

Funding statement: The author(s) received no financial support for the research, authorship, and/or publication of this article

Declaration of conflicting interests: The Author(s) declare(s) that there is no conflict of interest.

REFERENCES

- Akins, C. W., Bitondo, J. M., Hilgenberg, A. D., Vlahakes, G. J., Madsen, J. C., & MacGillivray, T. E. (2005). Early and late results of the surgical correction of cardiac prosthetic paravalvular leaks. *The Journal of heart valve disease*, 14(6), 792-799.
- Genoni, M., Franzen, D., Vogt, P., Seifert, B., Jenni, R., Künzli, A., ... & Turina, M. (2000). Paravalvular leakage after mitral valve replacement: improved long-term survival with aggressive surgery?. *European journal of cardio-thoracic surgery*, 17(1), 14-19.
- Taramasso, M., Maisano, F., Latib, A., Denti, P., Guidotti, A., Sticchi, A., ... & Alfieri, O. (2014). Conventional surgery and transcatheter closure via surgical transapical approach for paravalvular leak repair in high-risk patients: results from a single-centre experience. *European Heart Journal—Cardiovascular Imaging*, 15(10), 1161-1167.
- Kloster, F. E. (1975). Diagnosis and management of complications off prosthetic heart valves. *Am J Cardiol*, 35, 872-885.
- Dhasmana, J. P., Blackstone, E. H., Kirklin, J. W., & Kouchoukos, N. T. (1983). Factors associated with periprosthetic leakage following primary mitral valve replacement: with special consideration of the suture technique. *The Annals of thoracic surgery*, 35(2), 170-178.
- Lázaro, C., Hinojar, R., & Zamorano, J. L. (2014). Cardiac imaging in prosthetic paravalvular leaks. *Cardiovascular diagnosis and therapy*, 4(4), 307-313.
- Zamorano, J. L., Badano, L. P., Bruce, C., Chan, K. L., Gonçalves, A., Hahn, R. T., ... & Di Bello, V. (2011). EAE/ASE recommendations for the use of echocardiography in new transcatheter interventions for valvular heart disease. *European heart journal*, 32(17), 2189-2214.
- Matsumoto, M., Inoue, M., Tamura, S., Tanaka, K., & Abe, H. (1981). Three-dimensional echocardiography for spatial visualization and volume calculation of cardiac structures. *Journal of Clinical Ultrasound*, 9(4), 157-165.
- Singh, P., Manda, J., Hsiung, M. C., Mehta, A., Kesanolla, S. K., Nanda, N. C., ... & Yin, W. H. (2009). Live/real time three-dimensional transesophageal echocardiographic evaluation of mitral and aortic valve prosthetic paravalvular regurgitation. *Echocardiography*, 26(8), 980-987.
- Kronzon, I., Sugeng, L., Perk, G., Hirsh, D., Weinert, L., Garcia Fernandez, M. A., & Lang, R. M. (2009). Real-time 3-dimensional transesophageal echocardiography in the evaluation of post-operative mitral annuloplasty ring and prosthetic valve dehiscence. *Journal of the American College of Cardiology*, 53(17), 1543-1547.
- García-Fernández, M. A., Cortés, M., García-Robles, J. A., de Diego, J. J. G., Perez-David, E., & García, E. (2010). Utility of real-time three-dimensional transesophageal echocardiography in evaluating the success of percutaneous transcatheter closure of mitral paravalvular leaks. *Journal of the American Society of Echocardiography*, 23(1), 26-32.
- Arribas-Jimenez, A., Rama-Merchan, J. C., Barreiro-Pérez, M., Merchan-Gómez, S., Iscar-Galán, A., Martín-García, A., ... & Sanchez, P. L. (2016). Utility of real-time 3-dimensional transesophageal echocardiography in the assessment of mitral paravalvular leak. *Circulation Journal*, 80(3), 738-744.