

An Unusual Cause of Keratitis: A Sino-Orbital Mucormycosis (About One Case)

Soukaina Tenouri^{1*}, Meryem Mouajab¹, Ahmed Bennis¹, Fouad Chraibi¹, Meriem Abdellaoui¹, Idriss Benatiya Andaloussi¹

¹Ophthalmology Department at the Hassan II University Center of Fez, Morocco

DOI: [10.36347/sjmcr.2022.v10i02.005](https://doi.org/10.36347/sjmcr.2022.v10i02.005)

| Received: 16.12.2021 | Accepted: 30.01.2022 | Published: 05.02.2022

*Corresponding author: Soukaina Tenouri

Ophthalmology Department at the Hassan II University Center of Fez, Morocco

Abstract

Case Report

Mucormycosis is a relatively rare and fatal fungal infection by rhizorius-type germ. Its incidence is commonly observed among immunocompromised patients, and especially the diabetic in acid-ketosis decompensation. We report the case of a 71-year-old patient, poorly balanced diabetic, presenting a unilateral keratitis, whose etiological research led to the diagnosis of sino-orbital mucormycosis by realizing a craniofacial Computed Tomography and a biopsy of the necrotic ulceration. Adequate therapeutic management in the intensive care unit has been provided, with the administration of injectable antifungal therapy. However, the patient died within two days of severe sepsis. Although rare, it is a serious pathology that can be life-threatening. Early diagnosis and the implementation of a well-codified therapeutic strategy are the only guarantees of a favorable outcome, both functional and vital.

Keywords: Mucormycosis, keratitis, fungal infection, lethal.

Copyright © 2022 The Author(s): This is an open-access article distributed under the terms of the Creative Commons Attribution 4.0 International License (CC BY-NC 4.0) which permits unrestricted use, distribution, and reproduction in any medium for non-commercial use provided the original author and source are credited.

INTRODUCTION

Mucormycoses are invasive, rare, and severe fungal infections by rhizorius-type germ [1]. They mainly occur in immunocompromised patients, and especially the diabetic in acid-ketosis decompensation [1]. Difficult to diagnose as much as to treat, these fungal infections quickly engage patient prognosis. Given the aggressiveness and the rapidity of the evolution of lesions, they threaten the vital prognosis in the very short term.

CASE REPORT

This is a 71-year-old patient, diabetic for 15 years on insulin therapy, very poorly balanced on the glycemic level. Hospitalized for five days in the endocrinology department for the management of a diabetic ketoacidosis. She has been referred to ophthalmological emergencies for examination.

Examination of the patient found a cachexic, asthenic patient. On inspection, we note the presence of a large necrotic ulceration encompassing the internal canthus and the wing of the right nose (Figure 1).

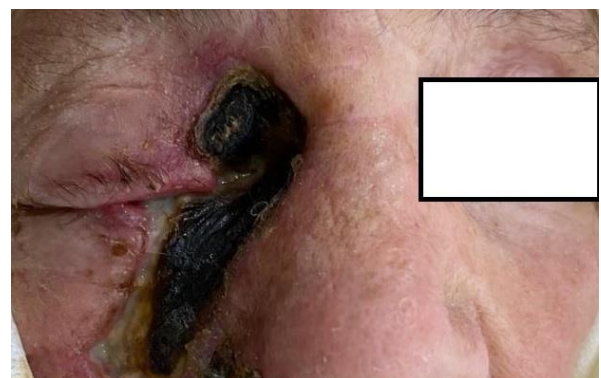

Figure 1: Large necrotic ulceration within the internal canthus and the wing of the right nose

On the ophthalmological level, the examination finds on the right eye a negative light perception. On the anterior segment: there is diffuse conjunctival hyperemia with chemosis and purulent secretions, ophthalmoplegia, a pearly white keratitis taking up almost the entire cornea (Figure 2). The examination of the other eye is unremarkable except a senile cataract. The rest of the somatic examination reveals necrosis of the right hemi palate, with a coated tongue (Figure 3).

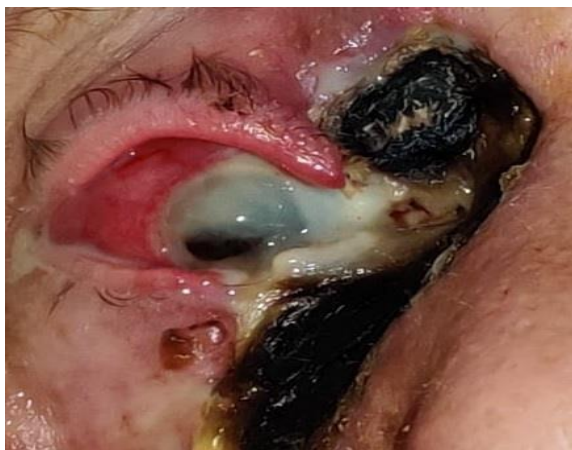

Figure 2: Purulent keratitis on the right side on a painful non-functional red eye

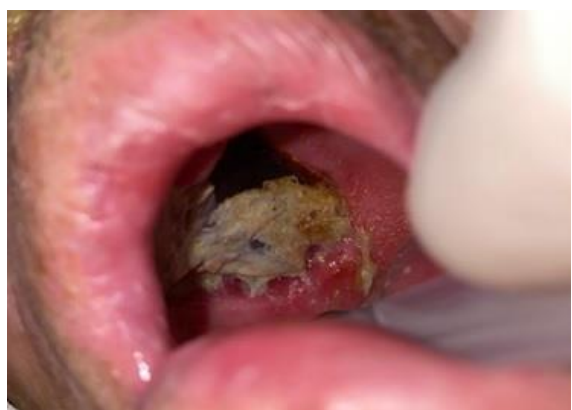

Figure 3: Necrosis of the right hemipalate

A craniofacial Computed Tomography (CT) showed invasive fungal sinusitis with right endocranio-orbital extension complicated by cavernous sinus thrombosis on the same side and fasciitis of the ipsilateral hemiface (Figure 4). A biopsy of the necrotic cutaneous ulceration was made in favor of ulcerated and suppurative dermatitis with the presence of non-septate filaments of irregular calibers, suggesting mucormycosis.

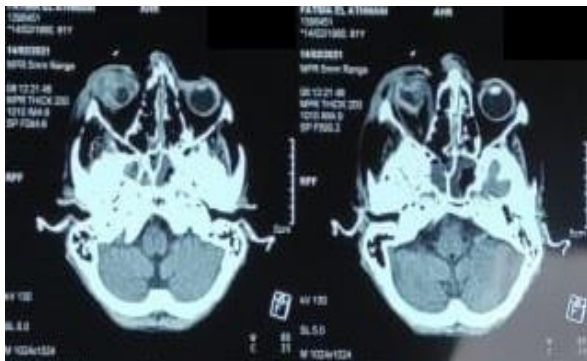


Figure 4: Craniofacial CT showing bone lysis and thickening of the different walls of the right orbit

The patient was then hospitalized in the intensive care unit, injectable antifungal treatment was instituted, with curative anticoagulation, rehydration,

and insulin therapy. The ophthalmological evolution was marked by the occurrence of a perforation of the right eyeball. The patient died within two days of severe sepsis.

DISCUSSION

Mucormycosis is an acute, and rapidly progressive fungal infection by an opportunistic germ of a mucoral order [1]. It mainly affects immunocompromised patients [1]. Its first description dates to 1885 by Paultauf [2]. Its incidence doubled during the last decade in Europe [3]. Its impact is estimated at about 500 cases/year in the United States [1, 4]. The most common type is *Rhizopus Arridans* in about two-thirds of cases [2]. The contamination is mainly aerial [5]. A contamination by digestive or cutaneous way is possible, however, no case of human-to-human contamination is reported in the literature [6].

The combination of diabetic ketoacidosis and sino mucormycosis is widely described in the literature without being able to explain this association [3]. Spelleberg predicts that diabetic ketoacidosis promotes the occurrence of mucormycosis by decreasing phagocytic power of polynuclear [4].

The diagnosis is essentially clinical, evoked in the presence in an immunocompromised patient of pansinusitis with bedsores in the orbito-nasal region [7]. Infection begins in the nasal or oral mucosa to extend to the ethmoid and maxillary sinuses. Orbital extension is done either by contiguity or perivascular or perineural way. It can cause optic neuritis source of blindness (80% for Bhansali [8] and 65% for Yohai [9]). It results clinically in an ophthalmoplegia, exophthalmos and ptosis [8].

Nasal sinus CT with injection is of systematic realization. It reveals radiological abnormalities, such as bone lysis, sinus filling, extent of lesions [6]. Magnetic resonance imaging is indicated in case of cranial or orbital damage to study the extent of the lesions or in case of extension to the cavernous sinus [10]. Performing a deep biopsy with mycological study allow to make the diagnosis of fungal infection with germ type mucoral by identifying mycelial hyphae, their type [11].

The treatment of mucormycosis is based on 3 components: the balance of risk factors such as glycemic balance, injectable antifungal therapy, and surgical debridement of necrosis foci [8]. Antifungal treatment relies on intravenous amphotericin B at the dose of 1 mg/kg/day maintained for 3 months. The liposomal form (10 mg/kg/day) allows a better response with fewer adverse effects [12]. Posaconazole is offered in case of intolerance to amphotericin B [13]. Surgical debridement of foci of necrosis should be conducted early and guided by extemporaneous examination [14].

Functional and vital prognosis of this disease is serious with a mortality rate 20-50% of cases [15]. Survival depends on fast management (76% for treatment before 7 days and 40% after two weeks) and the association of surgical debridement to antibiotic therapy [9]. The survival of non-diabetics is better than diabetics (60-77% versus 20-34%) [9].

CONCLUSION

Sino-orbital mucormycosis is an invasive fungal infection occurring mainly in immunocompromised subjects. Although rare, it is a serious pathology that can be life-threatening. Early diagnosis and the implementation of a well-codified therapeutic strategy are the only guarantees of a favorable outcome, both functional and vital.

REFERENCES

- Lahmar, I., Jerbi, S., Chahed, H., Fdhila, R., ... & Driss, N. (2008). La mucormycose nasosinusienne: Diagnostic et modalités thérapeutiques. *Journal Tunisien d'ORL et de Chirurgie Cervico-Faciale*, 21.
- Athanasiadou, K. I., Athanasiadis, D. I., Constantinidis, J., ... & Papakonstantinou, E. (2019). Successful treatment of rhinoorbital mucormycosis due to *Rhizopus arrhizus* with liposomal amphotericin B, posaconazole and surgical debridement in a child with neuroblastoma. *Medical mycology case reports*, 25, 10-14.
- Spellberg, B., & Ibrahim, A. S. (2010). Recent advances in the treatment of mucormycosis. *Current infectious disease reports*, 12(6), 423-429.
- [4]: Spellberg, B., Edwards Jr, J., & Ibrahim, A. (2005). Novel perspectives on mucormycosis: pathophysiology, presentation, and management. *Clinical microbiology reviews*, 18(3), 556-569.
- Gass, J. D. M. (1961). Ocular manifestations of acute mucormycosis. *Archives of Ophthalmology*, 65(2), 226-237.
- Mimouni, O., Curto, C. L., Danvin, J. B., Thomassin, J. M., & Dessi, P. (2010). Sinonasal mucormycosis: Case report. *European annals of otorhinolaryngology, head and neck diseases*, 127(1), 27-29.
- Mbarek, C., Zribi, S., Khamassi, K., Hariga, I., Ouni, H., Ben Amor, M., ... & El Khedim, A. (2011). Rhinocerebral mucormycosis: five cases and a literature review. *B-ent*, 7(3), 189.
- Bhansali, A., Bhadada, S., Sharma, A., Suresh, V., Gupta, A., Singh, P., ... & Dash, R. J. (2004). Presentation and outcome of rhino-orbital-cerebral mucormycosis in patients with diabetes. *Postgraduate medical journal*, 80(949), 670-674.
- Yohai, R. A., Bullock, J. D., Aziz, A. A., & Markert, R. J. (1994). Survival factors in rhino-orbital-cerebral mucormycosis. *Survey of ophthalmology*, 39(1), 3-22.
- Cornely, O. A., Alastruey-Izquierdo, A., Arenz, D., Chen, S. C., Dannaoui, E., Hochhegger, B., ... & Mucormycosis, E. C. M. M. (2019). Global guideline for the diagnosis and management of mucormycosis. *The Lancet infectious diseases*, 19(12), e405-e421.
- DiBartolo, M. A., & Kelley, P. S. (2011). Rhino-orbital-cerebral mucormycosis (ROCM): a comprehensive case review. *Aviation, space, and environmental medicine*, 82(9), 913-916.
- Ogawa, T., Takezawa, K., Tojima, I., Shibayama, M., Kouzaki, H., Ishida, M., ... & Shimizu, T. (2012). Successful treatment of rhino-orbital mucormycosis by a new combination therapy with liposomal amphotericin B and micafungin. *Auris Nasus Larynx*, 39(2), 224-228.
- Kulendra, K., Habibi, M., Butler, C., Clarke, P., & Howard, D. (2010). Use of posaconazole in the treatment of infective rhinocerebral mucormycosis. *The Journal of Laryngology & Otology*, 124(12), 1314-1317.
- Saedi, B., Sadeghi, M., & Seilani, P. (2011). Endoscopic management of rhinocerebral mucormycosis with topical and intravenous amphotericin B. *The Journal of Laryngology & Otology*, 125(8), 807-810.
- Chander, J., Kaur, J., Gulati, N., Arora, V., Nagarkar, N., Sood, S., & Mohan, H. (2011). Sudden vision loss caused by rhino-orbital zygomycosis in diabetic patients: case series. *Mycoses*, 54(4), e228-e232.