

## Dislocation of the Lens Revealing a Complicated Aortic Dissection in a Stable Patient with a Marfan Syndrome

Benlafkih Otmame<sup>1\*</sup>, Maatof Bouchra<sup>1</sup>, Hazzazi Ikrame<sup>1</sup>, El Karimi Saloua<sup>1</sup>, El Hattouhi Mustapha<sup>1</sup>

<sup>1</sup>Cardiology Department, University Hospital, Marrakech, Morocco

DOI: [10.36347/sjmcr.2022.v10i02.007](https://doi.org/10.36347/sjmcr.2022.v10i02.007)

| Received: 29.12.2021 | Accepted: 04.02.2022 | Published: 08.02.2022

\*Corresponding author: Benlafkih Otmame

Cardiology Department, University Hospital, Marrakech, Morocco

### Abstract

### Case Report

We present the case of a patient admitted for an asymptomatic aortic dissection, complicated and extended to carotid arteries and iliac arteries in a young patient with clinical signs and a family history of Marfan syndrome who came to the emergency room for a sudden vision loss related to lens dislocation without any other associated signs, including no abdominal or thoracic pain or neurological or lower extremity symptoms and with a stable hemodynamic status, with specific morphological abnormalities specific to this syndrome and severe aortic insufficiency. The morality of our work is to show the importance of a the clinical examination of all patients who present clinical signs suggestive of Marfan syndrome during any consultation and the need for a very close follow-up in this population given to the morbidity and high mortality in case of complications.

**Keywords:** Marfan syndrome, Aortic dissection, Dislocated lens.

Copyright © 2022 The Author(s): This is an open-access article distributed under the terms of the Creative Commons Attribution 4.0 International License (CC BY-NC 4.0) which permits unrestricted use, distribution, and reproduction in any medium for non-commercial use provided the original author and source are credited.

## INTRODUCTION

Marfan syndrome is one of the genetic syndromes caused by a mutation of the genes encoding fibrillin-1 and type III procollagen (FBN-1), which is an autosomal-dominant mutation with variable expression [1]. Aortic dissection is very frequent in patients with Marfan syndrome. The criteria for this syndrome include the presence of clinical findings in cardiovascular, ocular, and skeletal systems and/or a positive family history of FBN-1 mutations.

## CASE REPORT

We report a case of a 31 years old male, without any cardiovascular risk factors, having an history of a sister followed for Marfan syndrome, presented to emergencies with a sudden visual loss in the left eye revealing a dislocated intraocular lens (Figure 1).

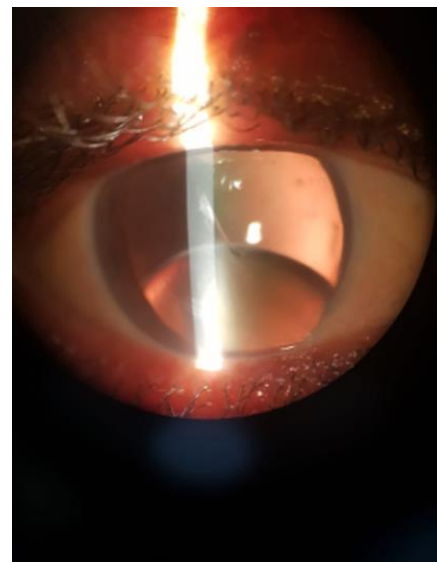
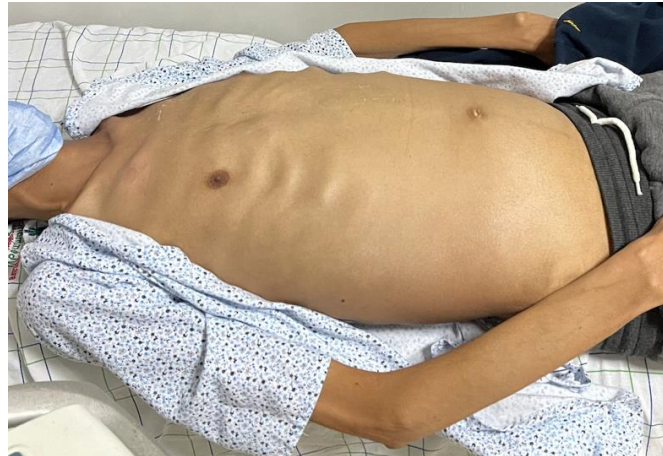

Figure 1: Dislocated intraocular lens

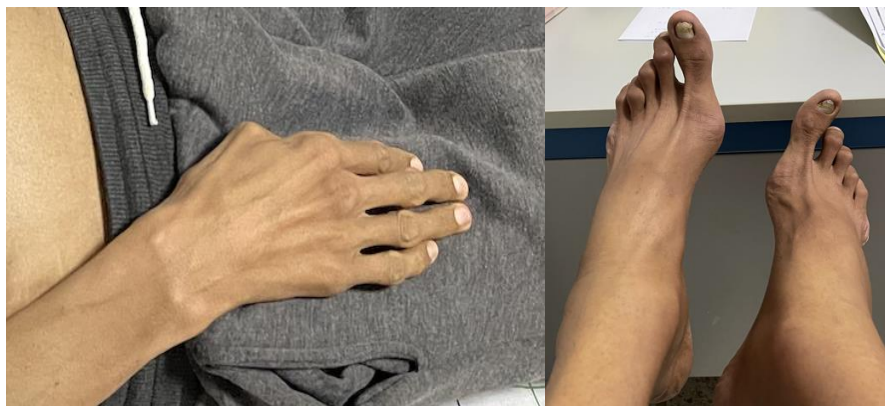Our opinion as cardiologist was sought as part of the preoperative assessment. At admission, our patient had a symmetric systolic and diastolic blood pressure of 135/51 mmhg, a heart rate of 80/min. On examination, he was 207,5 cm tall, weighted 80 kg. He presented physical abnormalities; a prolonged face, a

mild pectus carinatum deformity (Figure 2), scoliosis, high arched palate and arachnodactyly (Figure 3). He

had also a regurgitation murmur at the aortic and tricuspid focus (5/6).



**Figure 2: Mild pectus carinatum deformity**

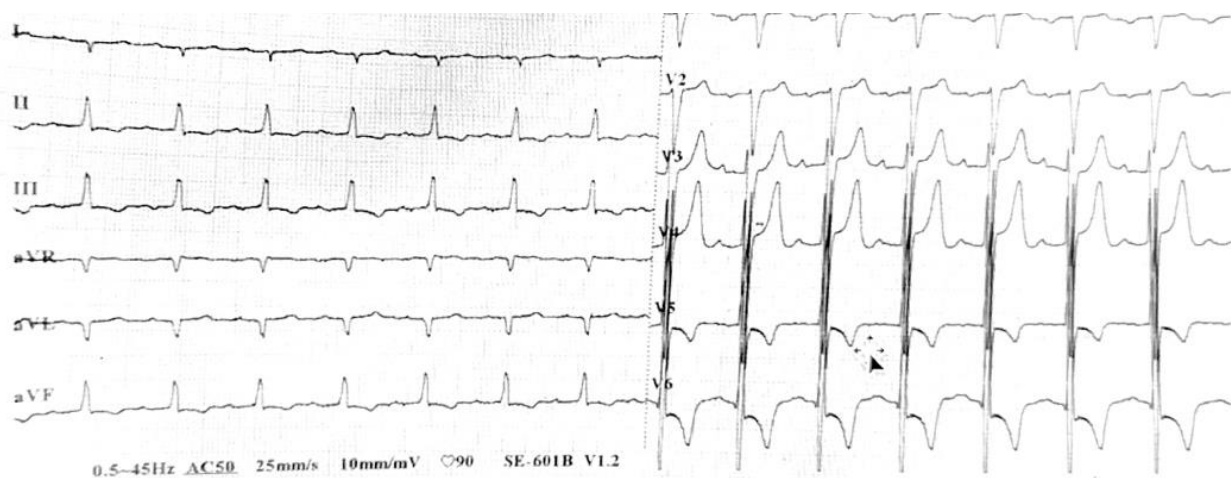


**Figure 3: Arachnodactyly**

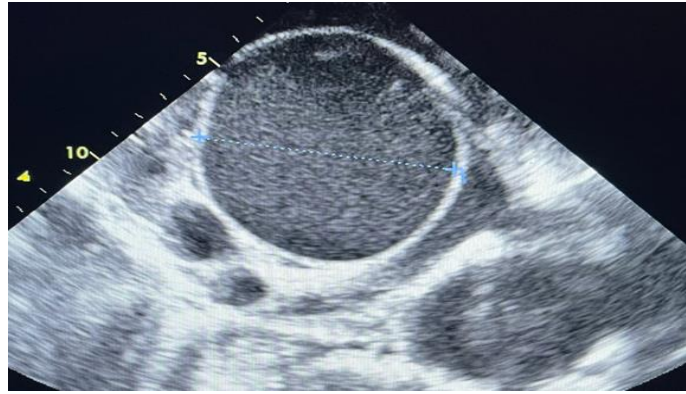
An electrocardiogram was performed and showed a left ventricular hypertrophy with a first degree auriculoventricular block (Figure 4).

A transthoracic echocardiography was performed due to the aortic and tricuspid murmur

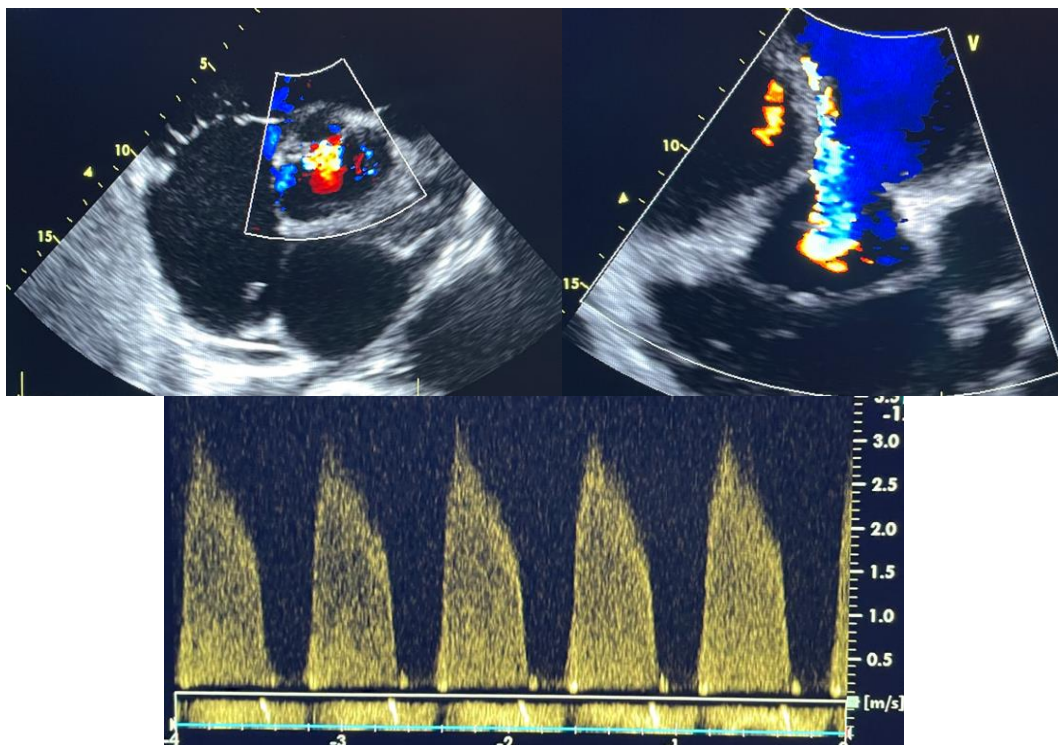
showed a global hypokinesia with a moderate left ventricular dysfunction, a pathological aortic root dilatation estimated at 8 cm (Figure 5), a severe central aortic regurgitation, a severe tricuspid regurgitation (Figure 7) and an intimal flap in the Valsalva sinus (Figure 8).



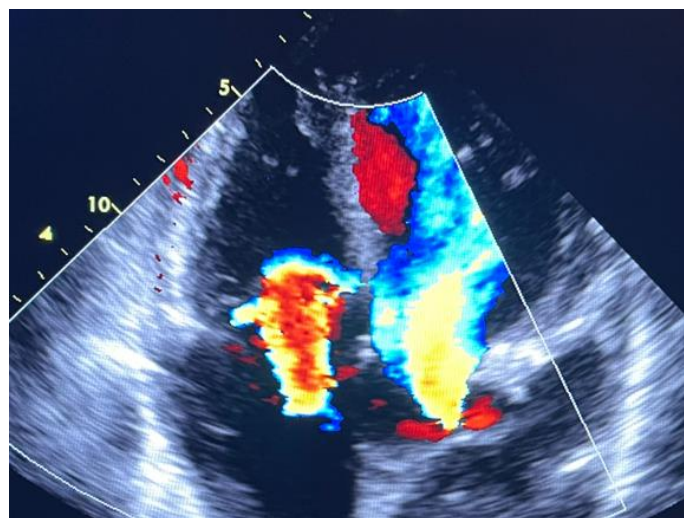
**Figure 4: Electrocardiogram showing a left ventricular hypertrophy**



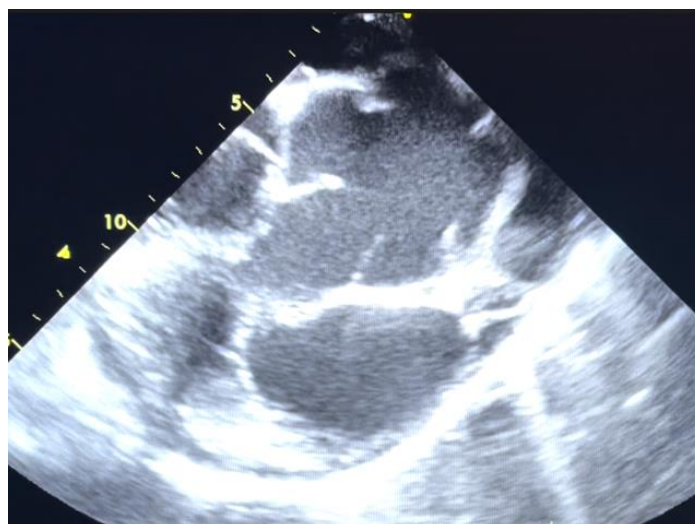
**Figure 5: Transthoracic echocardiography showing a dilated aorta**



**Figure 6: Transthoracic echocardiography showing a severe aortic regurgitation**



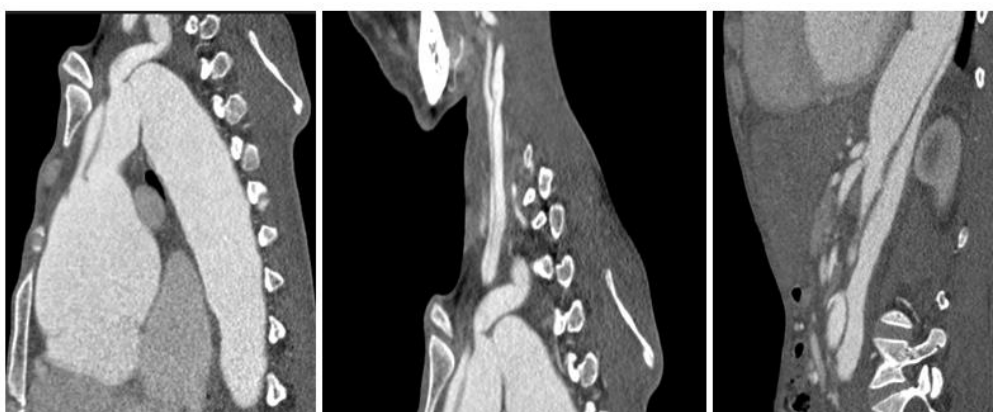
**Figure 7: Transthoracic echocardiography showing a severe tricuspid regurgitation**



**Figure 8: Transthoracic echocardiography showing an intimal flap**

According to stable hemodynamic status and discreet clinical presentation, we complete with a thoraco-abdominal CT angiography which showed a

significant dilatation of the thoraco-abdominal aorta and a dissection (Stanford A) extended to the carotids and to the iliac bifurcation (Figure 9).



**Figure 9: CT angiography showing an aortic dissection**

The diagnosis of a complicated aortic dissection was finally retained and the patient was initially treated in the cardiovascular surgery department given to the degree of emergency based on the CT scan findings and will be referred in a second time to the ophthalmology department.

The patient underwent a Bentall surgery with replacement of the ascending aorta, the aortic valve and a tricuspid valvuloplasty.

The patient fully recovered and was discharged in good general medical condition thirteen days after the operation. After two months of follow-up, the patient's condition was satisfying.

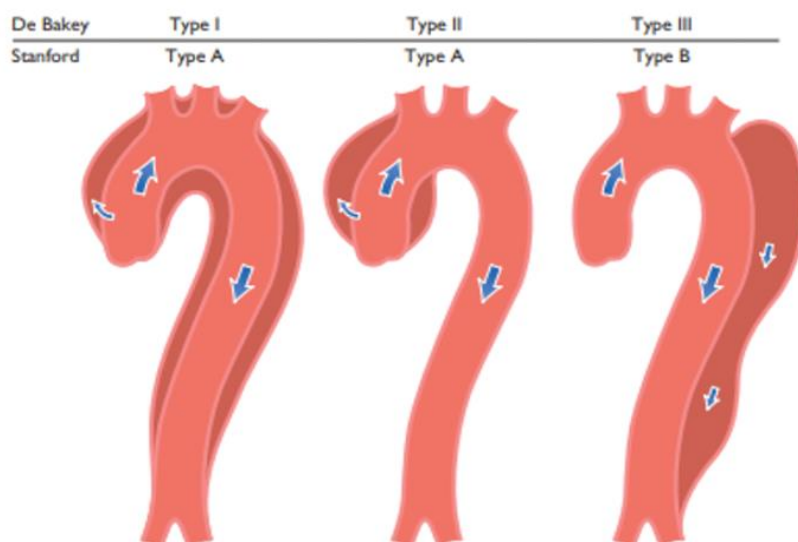
## DISCUSSION

Marfan syndrome is a variable, autosomal dominant disorder of connective tissue whose cardinal features affect the cardiovascular system, eyes and skeleton [1].

The diagnosis of is based on the mutation screening of FBN-1 and Ghent criteria. The Ghent criteria contains family/genetic history, involvement of organ systems (primarily skeletal, cardiovascular, and ocular) and whether the clinical sign is major or minor. Major criteria are specific for Marfan syndrome and are rarely present in the general population [2].

Aortic dilatation, usually maximal at the sinus of Valsalva, usually associated with aortic valve incompetence leads to aortic dissection. The aortic dissection is a very serious complication of this disease. It is one of the leading cardiovascular causes of death [3].

Patients with Marfan syndrome are predisposed to have thoracic aortic aneurysms involving the aortic root, ascending aorta, arch, and descending thoracic aorta. Prophylactic medical treatment with regular follow-up helps delay serious complications [2].



**Figure 10: Classification of aortic dissection localization according to Reul *et al.*, [8]**

Class I screening guidelines by the American College of Cardiology include an echocardiography at the time of diagnosis of Marfan syndrome to determine the diameter of the aortic root and ascending aorta. Repeat imaging is recommended at six months and then annually to follow the rate of enlargement. If the aorta is greater than 4.5 cm or has significantly changed from baseline, more frequent screening is recommended [4].

Beta-blockade and elective aortic root replacement at 5 cm are proposed to prevent dissection. Also, blood pressure management with a beta blocker with a goal heart rate less than 100 beats per minute [5]. Low-dose aspirin therapy helps to reduce major coronary events [6].

According to the guidelines, Stanford Type A dissections are a surgical emergency [7]. Surgical repair is recommended for an external diameter of 5.5cm in males, 5 cm in females, or a rapid growth (more than 5 mm in 6 months or 1 cm over one year) [6] or in the presence of significant aortic regurgitation, or a family history of aortic dissection, or expansion of more risk factors for rupture include advanced age, male sex, Caucasians, smoking, other large vessel aneurysms, and atherosclerosis [4, 6, 8].

## CONCLUSION

Our observation showed the importance of screening for the cardiovascular complication of a Marfan syndrome with regular follow-up even though the patient may not have chest or abdominal pain and be hemodynamically stable.

**Conflicts of Interest:** The authors declare no financial interest nor any other conflict of interest.

**Informed Consent:** The patient consented

## BIBLIOGRAPHY

1. DeMartino, R. R., Sen, I., Huang, Y., Bower, T. C., Oderich, G. S., Pochettino, A., ... & Roger, V. (2018). Population-based assessment of the incidence of aortic dissection, intramural hematoma, and penetrating ulcer, and its associated mortality from 1995 to 2015. *Circulation: Cardiovascular Quality and Outcomes*, 11(8), e004689.
2. Loeys, B. L., Dietz, H. C., Braverman, A. C., Callewaert, B. L., De Backer, J., Devereux, R. B., ... & De Paepe, A. M. (2010). The revised Ghent nosology for the Marfan syndrome. *Journal of medical genetics*, 47(7), 476-485.
3. Zipes, D. P., Libby, P., Bonow, B. O., Mann, D. L., Tomaselli, G. F., & Braunwald, E. (2019). *Braunwald's Heart Disease: A Textbook of Cardiovascular Medicine*, Elsevier, Philadelphia, PA, USA, Eleventh edition.
4. Hiratzka, L. F., Bakris, G. L., & Beckman, J. A. (2010). ACC/AHA pocket guideline: guidelines for the diagnosis and Management of Patients with thoracic aortic disease, The American College of Cardiology Foundation and the American Heart Association.
5. Wolfgarten, B., Krüger, I., & Gawenda, M. (2001). Rare manifestation of abdominal aortic aneurysm and popliteal aneurysm in a patient with Marfan's syndrome: a case report. *Vascular surgery*, 35(1), 81-84.
6. Moll, F. L., Powell, J. T., Fraedrich, G., Verzini, F., Haulon, S., Waltham, M., ... & Ricco, J. B. (2011). Management of abdominal aortic aneurysms clinical practice guidelines of the European society for vascular surgery. *European journal of vascular and endovascular surgery*, 41, S1-S58.
7. Chaikof, E. L., Dalman, R. L., Eskandari, M. K., Jackson, B. M., Lee, W. A., Mansour, M. A., ... & Starnes, B. W. (2018). The Society for Vascular

Surgery practice guidelines on the care of patients with an abdominal aortic aneurysm. *Journal of vascular surgery*, 67(1), 2-77.

8. Erbel, R., Aboyans, V., Boileau, C., Bossone, E., Bartolomeo, R. D., ... & Kravchenko, I. (2014). 2014 ESC Guidelines on the diagnosis and

treatment of aortic diseases: document covering acute and chronic aortic diseases of the thoracic and abdominal aorta of the adult The Task Force for the Diagnosis and Treatment of Aortic Diseases of the European Society of Cardiology (ESC). *European heart journal*, 35(41), 2873-2926.