

Swenson like Full Thickness Transanal Pull through for Short Segment Hirschsprung Disease: My Experience in A Tertiary Care Hospital Bangladesh

Dr. S.M. Khalid Mahmud^{1*}, Dr. Jahanara Laizu², Dr. Rakibul Islam³

¹Assistant Professor, Department of Pediatrics Surgery, Bangladesh Shishu Hospital and Institute, Dhaka, Bangladesh

²Associate Professor, Department of Pharmacology, Uttara Adhunik Medical College, Dhaka, Bangladesh

³Registrar, Department of Pediatric Surgery, Bangladesh Shishu Hospital and Institute, Dhaka, Bangladesh

DOI: [10.36347/sasjs.2022.v08i02.001](https://doi.org/10.36347/sasjs.2022.v08i02.001)

| Received: 09.12.2021 | Accepted: 25.01.2022 | Published: 09.02.2022

*Corresponding author: Dr. S.M. Khalid Mahmud

Assistant Professor, Department of Pediatrics Surgery, Bangladesh Shishu Hospital and Institute, Dhaka, Bangladesh

E-Mail ID: drkhalidmahmud71@gmail.com

Abstract

Original Research Article

Introduction: The Swenson procedure was the original pull-through procedure used to treat Hirschsprung disease. The aganglionic segment is resected down to the sigmoid colon and rectum, and an oblique anastomosis is performed between the normal colon and the low rectum. Given our Center's experience with a full-thickness transanal pull rectal dissection for anorectal malformations we chose to apply the ideas to the primary treatment of HD, and describe technical aspects and impact on fecal, urinary, and sexual function. **Aim of the study:** The aim of the study was to analyze the short term outcome of patients who have undergone the swenson abdominoperineal pull through operation in the treatment of Hirschsprung's disease. **Methods:** This prospective study had been carried out in the Department of Pediatric Surgery, Dhaka Shishu Hospital during the period of June 2015 to December 2020. Total 60 patients with Hirschsprung's disease with or without colostomy except total colonic aganglionosis were included in this study. We also excluded those patients with major co-morbidities and patients who did not agree to close stoma within 12 weeks of pull through. Consideration was given to postoperative complications (Cuff /anastomotic/pelvic abscess, wound infection, anastomotic leakage, fecal incontinence, urinary incontinence, mortality), operation time and post-operative hospital stay and as well as the short term outcome. We reviewed our series of HD patients who underwent a transanal, Swenson-like rectosigmoid dissection, assessing for postoperative stricture, anastomotic leak, enterocolitis, and long-term results for bowel, urinary, and sexual function. **Results:** A total of 60 patients were included and analyzed in this study. All of sixty patients had Hirschsprung disease in this study. The age range started from 1-3 years and end to 8-12 years, respectively, in Table-1 whereas 33(55.0%) were from 8-12 years, 25(42.67%) patients were from 4-7 years and lastly 2(3.33%) patients were from 1-3 years. The outcome of the study showing through Figure-1; 46 patients had no complication, 5 patients had wound infection, 3 patients had fecal incontinence, 2 patients had all of anastomotic abscess, pelvic abscess & urinary/incontinence and only one patient was died during the treatments.

Conclusion: For the treatment of Hirschsprung disease (HD) Classic Swenson's procedure is an effective procedure.

Keywords: Swenson, Transanal, Segment and Hirschsprung diseases.

Copyright © 2022 The Author(s): This is an open-access article distributed under the terms of the Creative Commons Attribution 4.0 International License (CC BY-NC 4.0) which permits unrestricted use, distribution, and reproduction in any medium for non-commercial use provided the original author and source are credited.

INTRODUCTION

Hirschsprung disease (HSCR), which is characterized by the absence of ganglion cells (Meissner and Auerbach) along variable lengths of the distal gastrointestinal tract, is a common cause of neonatal intestinal obstruction, which is of great interest to pediatric surgeons throughout the world [1]. This disorder can be classified as follows: (1) short-segment (aganglionosis is confined to the recto-sigmoid colon), (2) long-segment (aganglionic segment extends

proximal to the sigmoid), and (3) total colonic aganglionosis [1]. Several definitive surgeries have been established for HSCR such as transabdominal endorectal pull-through (Soave), Duhamel, transanal endorectal pull-through (TEPT), transanal Swenson-like, and posterior neurectomy procedures [2–6], with varying outcomes [7]. Swenson pull through was the historic breakthrough in the understanding of pathogenesis and treatment of HD. The procedure, soon became popular as Swenson's procedure, brought a realistic hope that children with HD can be cured [8].

Barium enema may help in diagnosis but transition zone may not be obvious within 3 months of age [9]. Rectal biopsy remains the gold standard in confirming the HD. The first successful treatment HD was undertaken over sixty years ago by Over Swenson [10]. Since then the operative management of HD has evolved dramatically, from, an endorectal dissection(soave) [11], a retrorectal pouch procedure(duhamel) [12] and a low anterior resection(Rehbein) [13], to more recently a primary repair [14, 15] that can be done transanally [16, 17] and using laparoscopic technique [18] to full thickness rectosigmoid dissection (swenson) [19]. On this background different procedures are being practiced in Bangladesh. In our institution we demonstrated our experience with Swenson pull through dissection for the treatment of HD in a tertiary hospital. The aim of the study was to analyze the short-term outcome of patients who have undergone the swenson abdominoperineal pull through operation in the treatment of Hirschsprung's disease.

METHODOLOGY & MATERIALS

Swenson's procedure for the patients with Hirschsprung's disease was introduced after strictly controlled laboratory works by Orvar Swenson in 1948. The procedure needed meticulous rectal dissection to reduce complications to the surrounding structures. The Swenson procedure was the original pull-through procedure used to treat Hirschsprung disease. The aganglionic segment is resected down to the sigmoid colon and rectum, and an oblique anastomosis is performed between the normal colon and the low rectum. The prospective study was conducted in the Department of Paediatric Surgery, Dhaka Shishu Hospital Dhaka during the period of June 2015 to December 2020 after getting ethical permission from ethical committee of Bangladesh Institute of Child health (BICH). A total of 60 patients were included in the study. All 60 patients of diagnosed HD were operated by Classic Swenson abdominoperineal pull

through technique. After getting written consent from parents, all data were collected from preformed questionnaire. Data included relevant history, clinical features of the patients, results of contrast enema demonstrating transition zone, histopathology report of rectal biopsy, operative findings, post-operative management etc. The post-operative follow-up need to see the wound infection, fecal incontinence, urinary incontinence, anastomotic abscess/cuff abscess/ pelvic absces. Data of operation time and post-operative hospital stay were also collected. All Collected data were compiled and arranged in a systematic manner.

• Inclusion criteria

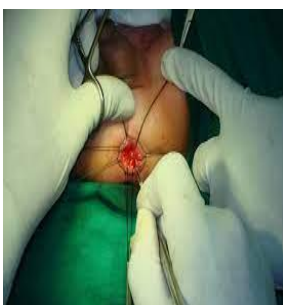- Hirschsprung disease patients
- Patients with or without colostomy
- Except total colonic aganglionosis patients
- Patients who agree to close colostomy of pull through operation

• Exclusion criteria

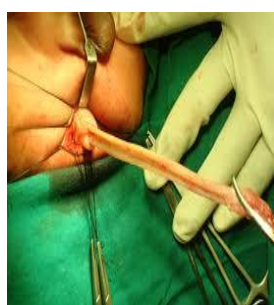- Major Congenital Heart Disease
- Multiple congenital anomalies
- Patients who were not interested

Operative Technique

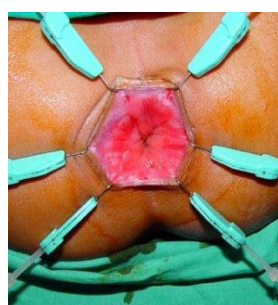
Mechanical bowel preparations along with rectal irrigations are recommended. Prior to Operation. A total body preparation from the nipples to the toes and urinary catheterization is performed. The operation was originally done through a laparotomy, with the anastomosis being performed from a perineal approach after eversion of the aganglionic rectum. Coloanal anastomosis was done 1cm proximal to dentate line (Picture-B). Dissection continued up to the tip of the coccyx (Picture-A). Then the dissected aganglionic gut was pulled through the anus in everted fashion. Last of all the healthy ganglionic gut was pulled through the aganglionic gut keeping a seromuscular cuff measuring 1 cm anteriorly and 0.5 cm posteriorly (Picture-C)



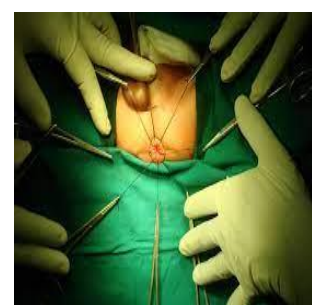Picture-A



Picture-B



Picture-C



Picture-D

RESULTS

A total of 60 patients were included and analyzed in this study. All of sixty patients had hirschsprung disease in this study. The age range started from 1-3 years and end to 8-12 years, respectively, in Table-1 whereas 33(55.00%) were from 8-12 years,

25(42.67%) patients were from 4-7 years and lastly 2(3.33%) patients were from 1-3 years. In this study the male & female ratio was 43:17 in Table-2, whereas male was 43(71.67%) and female was 17(28.33%). According to Table-3 history and clinical presentation in patients with HD; 41(68.33%) patients were from

delayed passes of meconium, 37(61.67%) patients were from chronic constipation, 34 (56.67%) patients were from abdominal distention, 9(15.0%) patients were from vomiting, 6(10.0%) patients were from enterocolitis, 3(5.0%) patients were from failure of thrive and 2(3.33%) patients were from fecoloma (Table-3). The level of transition zone determined by contrast enema height was 49(81.67%) patients and lowest was 1(1.67%) patients in table-4. Classic Swenson abdomino perineal pull through operation time

(min) was 115.16±16.17 (Mean ±SD) & range was (90-135) and patients was stayed in hospital (day) 7.15±2.86 (Mean ±SD) & range was (7-12) in Table-5. The outcome of the study showing through Figure-1; 46 patients had no complication, 5 patients had wound infection, 3 patients had fecal in continence, 2 patients had all of anastomotic abscess, pelvic abscess & urinary/incontinence and only one patient was died during the treatments.

Table-1: Age distribution of study patients (N=60)

Age range (year)	n	%
1-3	2	3.33
4-7	25	41.67
8-12	33	55.0

Table-2: Sex distribution of study patients (N=60)

Sex	n	%	M:F Ratio
Male	43	71.67	43:17
Female	17	28.33	

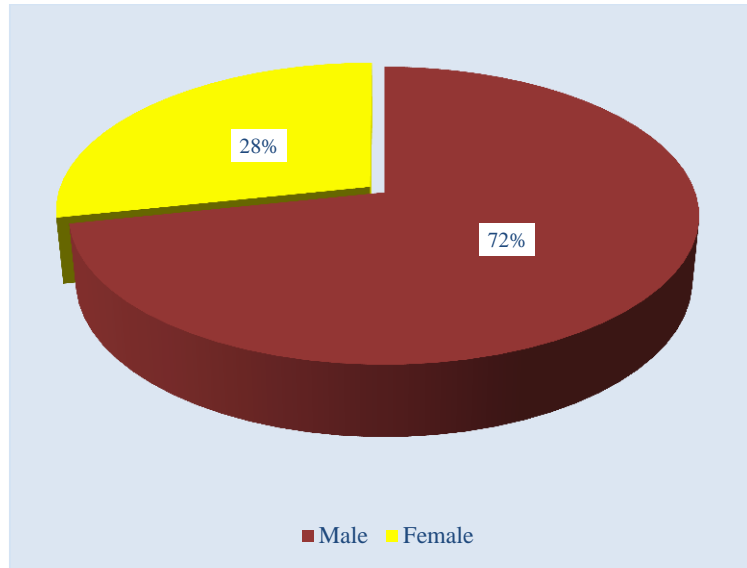


Figure I: Gender wise patients

Table-3: History and clinical presentation in patients with HD (N=60)


Clinical features	n	%
Delayed passes of meconium	41	68.33
Chronic constipation	37	61.67
Abdominal distention	34	56.67
Vomiting	9	15.0
Enterocolitis	6	10.0
Failure of thrive	3	5.0
Fecoloma	2	3.33

Table-4: Level of transition zone determined by contrast enema (N=60)

Site of transition zone	n	%
Rectosigmoid	49	81.67
Descendin colon	8	13.33
Transverse colon	2	3.33
Splenic flexure	1	1.67

Table-5: Total time of operation and hospital stay of the study population (N=60)

Features	Classic Swenson abdomino perineal pull through
Operation Time (min) Mean \pm SD	115.16 \pm 16.17
Range	90-135
Hospital Stay (day) Mean \pm SD	7.15 \pm 2.86
Range	7-21

**Figure II: Outcomes of patients**

DISCUSSION

The etiology of Hirschsprung disease was originally described by Dr. Swenson and Bill in 1948 as relating to a defective segment of distal colon producing a partial bowel obstruction [19]. In the 1950's, after thorough examination of surgical specimens, it was noted that the diseased segments of colon contained minimal, if any, evidence for an Auerbach's plexus, leading to the use of rectal biopsies for the purpose of diagnosis. Even as Dr. Ovar Swenson was only beginning to uncover the basis of the disease process, he sought to create a definitive surgical cure. Currently transanal procedure is preferred to Swenson as transanal procedure is associated with less morbidity. Swenson procedure is still preferred technique in our hospital. In this study male was predominant than female. The male female ratio was 43:17 which was very close to another study [20]. Regarding operation time, the mean operation time in this study was 68.46 \pm 29.03 minutes which was more or less similar to the study done by Leily M *et al.* where the mean operation time was 134.3 \pm 51.4 minutes [21]. In this study at follow up on 12th week we found 46(76.66%) patients had good postoperative outcome i, e these patients were without complications. In the study of Sowande OA *et al* 2011, postoperative good outcome was in 76% which was also similar to our study [22]. Normal urinary and faecal continence is the primary goal which led to

different modification of this procedure. Urinary continence is satisfactory in most patients in this series. The incidence may vary from 1% to as high as 37.7% [23, 24]. In this study only 3 patients complained of soiling after surgery and 2 patient developed urinary incontinence. Though incontinence cannot be judged beyond 3 years of age. In this study patients having urinary dribbling even after last follow up were noted as incontinence. Probably the pelvic dissection leads to injury to the nerve plexus around the bladder and causes incontinence [25, 26]. In our study, we noticed 4 patients had urinary dribbling after catheter removal, but in subsequent follow up on 8th week urinary dribbling of 3 patients resolved and 1 persisted up to 12th week. In the study of Zhang SC *et al.* showed 3.1% patients developed urinary incontinence, but he judged it after a long follow up more than 5 years [27]. So we have to follow up more to conclude finally about urinary incontinence. In our study 2 patients developed anastomotic abscess and 2 patients developed pelvic abscess. We performed 2 stage operations by exteriorizing the labelling colostomy for that 4 patients who developed anastomotic abscess and pelvic abscess. Moreover, mean age of the patients who developed abscess was 24.75 months. In these patients per operatively we found sign of inadequate decompression of ganglionic segment. Probably these things played role in more abscess formation [27]. In the study of

Fonkalsrud E. W *et al.* these complications occur in 10.52% which was higher than our study [26]. The operative mortality associated with Swenson pull through is low in many series and ranges from 0-2.5%. In this study mortality rate is 1.66% which is within range of other studies [28]. This, we believe, has led to a safer and more reproducible pelvic and rectal dissection. It appears there are little, if any, data to suggest that a fullthickness rectal dissection is less safe than other techniques and we believe there are key advantages, including excellent continence, and a purer operation without residual cuff or pouch left which can lead to obstruction. We feel that the full-thickness, Swenson-like dissection technique that we have described is safe, reproducible, and avoids many of the long-term complications associated with the other techniques.

Limitations of the study: A possible limitation of the study involves having only extracted information retrospectively from available medical records.

CONCLUSION AND RECOMMENDATIONS

In conclusion, our short term results are quite promising. Swenson procedure is a feasible for short segment as well as long segment HD though it has some complications still it has some role in the management of HD in children especially in our setup. Swenson's original transabdominal dissection concept using the recently described transanal approach is an excellent technique for Hirschsprung, and produces excellent long-term outcomes for fecal and urinary continence, and seems to preserve erectile function.

Funding: No funding sources

Conflict of interest: None declared

Ethical approval: The study was approved by the Institutional Ethics Committee.

REFERENCES

- Chakravarti A, Lyonnet S. Hirschsprung disease. In: Scriver CR, Beaudet AL, Valle D, Sly WS, Childs B, Kinzler K, *et al.*, editors. The metabolic and molecular bases of inherited disease. 8th ed. New York: McGraw-Hill; 2001. p. 6231–55.
- Lefèvre JH, Parc Y. Soave procedure. *J Visc Surg.* 2011; 148: e262-6.
- Nah SA, de Coppi P, Kiely EM, *et al.* Duhamel pull-through for Hirschsprung disease: a comparison of open and laparoscopic techniques. *J Pediatr Surg.* 2012; 47:308–12.
- De La Torre L, Langer JC. Transanal endorectal pull-through for Hirschsprung disease: technique, controversies, pearls, pitfalls, and an organized approach to the management of postoperative obstructive symptoms. *Semin Pediatr Surg.* 2010; 19:96–106.
- Mahajan JK, Rathod KK, Bawa M, Narasimhan KL. Transanal Swenson's operation for recto-sigmoid Hirschsprung's disease. *Afr J Paediatr Surg.* 2011; 8:301-5.
- Rochadi, Haryana SM, Sadewa AH. Gunadi. Effect of RET c.2307T > G polymorphism on the outcomes of posterior sagittal neurectomy for Hirschsprung disease procedure in Indonesian population. *Int Surg.* 2014; 99:802–6.
- Aworanti OM, Mcdowell DT, Martin IM, Hung J, Quinn F. Comparative review of functional outcomes post-surgery for Hirschsprung's disease utilizing the paediatric incontinence and constipation scoring system. *Pediatr Surg Int.* 2012; 28:1071–8.
- Skaba R. Historic milestones of Hirschsprung's disease (commemorating the 90th anniversary of Professor Harald Hirschsprung's death). *J Pediatr Surg;* 2007;42: 249-51.
- Swenson O. Partial internal sphincterotomy in the treatment. *Ann surg* 1964; 160:540-50.
- Swenson O., Bill AH. Resection of rectum and rectosigmoid with preservation of the sphincter for benign spastic lesions producing megacolon: An experimental study. *J Surg;* 1948; 24: 212-20.
- Soave F. A new operation for the treatment of Hirschsprung's disease. *J Pediatr Surgery.* 1964; 56:1007-14.
- Duhamel. B. A new operation for the treatment of Hirschsprung's disease. *Arch Dis Child;* 1960; 35:38-39.
- RehbeinF., Von Zimmermann H. Results with abdominal resection in Hirschsprung's disease. *Arch Dis Child.* 1960; 35:29-37.
- So HB, Schwartz DL, Becker JM, *et al.* Endo rectal pull through without preliminary colostomy in neonates with Hirschsprung's disease. *J pediatr surg* 1980; 15:470-71
- Teitelbaum DH, Coran AG, Primary pull through for hirschsprung's disease. *SeminNeonatology* 2003; 8:233-41.
- Latorre-Mondrago NL, Ortega-Saldrago JA. Transanal endorectal pullthrough for Hirschsprung's disease. *J padiatr surg* 1998; 33:1283-86
- Langer JC, Minkes RK, Mazziotti MV. Transanal one-stage Soave procedure for infants with Hirschsprung disease. *J Pediatr Surg.* 1999; 34:148-52.
- Georgeson KE, Fuenfer MM, Hardin WD. Primary laparoscopic pull through for Hirschsprung's disease in infant and children. *J padiatrsurg* 1995; 30:1017-22.
- Levitt M A, Miller C, Hamrick B E, Andrea B, Jennifer H, Peña A. Transanal full-thickness, Swenson-like approach for Hirschsprung disease. *Journal of Pediatric Surgery* 2013;48: 2289–95.
- Jacob CL. Hirschsprung disease. in: JA O'Neil, MI Rowe, JA Grossfield, EW Fankalsrud, AG Coran, editors. *Pediatric Surgery, 7th edn, Missouri: Mosby year book, 2004;2: 1870-95.*

21. Leily M., Ahmed KT, Mohsen R, Ali RM, Naser S, Javed G, Fathollah R, Alireza M, & Zahra G. Comparison between Swenson and Soave pull through in Hirschsprung disease. *Ann colorectal Res.* 2015; 3(4): e 32700
22. Sowande OA, Adejuyigbe O. Ten years' experience with the Swenson procedure in Nigerian children with Hirschsprung's disease. *African journal of paediatric surgery.* 2011;8(1):44-48
23. Coran AG, Teitelbaum DH. Recent advances in the management of Hirschsprung disease. *Am J Surg* 2000; 180:382-87
24. Gad EL-Hak NA, El-Hemaly MM, Negm EH, El-Hanafy EA, Abdel Messeh MH, Abdel Bary HH. Functional outcome of Swenson's operation for Hirschsprung disease. *Saudi J Gastroenterol* 2010; 16:30-34.
25. Holschneider AM, Kraeft H, Scholtissek C. Urodynamic investigation of bladder disturbances in imperforate anus and Hirschsprung's disease. *Z Kinderchir* 2000; 35:64-68
26. Fonkalsrud E.W. Complication of Hirschsprung's disease and allied disorders. In: Holschneider, AM., Puri, P.(eds). *Hirschsprung's disease and allied disorders.* Harwood, Singapore 2000; 2:425-31
27. Zhang SC., Bai Y.Z., Wang W. Long-term outcome, colonic motility, and sphincter after Swenson's procedure for Hirschsprung's disease: a single-center 2-decade experience with 346 cases. *Amer J Surg.* 2007; 194: 40-47. Sherman JO, Snyder ME, Weitzman JJ, Jona JZ, Gillis DA, O'Donnell B, et al. A 40 years' multinational retrospective study of 880 Swenson procedures. *J pediatr Surg* 1989; 24:833-38.
28. Madonna MB, Luck SR, Reynolds M, Schwarz DK, Arensman RM. Swenson procedure for the treatment of Hirschsprung's disease. *Semin Pediatr Surg* 1998; 7:85-88.