

## Acute Myocarditis Revealing a Multisystem Inflammatory Syndrome Following SARS-CoV-2 Infection

Yasmina Malky<sup>1\*</sup>, Halima Eljazouli<sup>1</sup>, Hind Nabawi<sup>1</sup>, Mohamed El Jamili<sup>1</sup>, Saloua El karimi<sup>1</sup>, Mustapha Hattaoui<sup>1</sup>

<sup>1</sup>Cardiology Department, Mohammed VI University Hospital, Marrakesh, Morocco

DOI: [10.36347/sjmcr.2022.v10i02.014](https://doi.org/10.36347/sjmcr.2022.v10i02.014)

| Received: 05.01.2022 | Accepted: 08.02.2022 | Published: 13.02.2022

\*Corresponding author: Yasmina Malky

Cardiology Department, Mohammed VI University Hospital, Marrakesh, Morocco

### Abstract

### Case Report

Multisystem inflammatory syndrome in children (MIS-C) secondary to COVID-19 infection is associated with Multiorgan dysfunction, and prominent cardiovascular complications, particularly myocardial and coronary artery involvement, as well as thrombotic complications that make the prognosis more severe. The treatment of this entity is essentially based on the stabilization of the patient (management of shock...) and the intravenous immunoglobulin associated or not with corticosteroids as first line treatment. We report the case of a 14-year-old girl who suffered from influenza syndrome and cardiogenic shock revealing a Multisystem inflammatory syndrome including a cardiovascular manifestations and Disseminated Intravascular Coagulation (DIC) associated to COVID-19 infection. It was managed with medical treatment including inotropic drugs and immunomodulatory treatment with intravenous immunoglobulin (IVIG) associated to anti-inflammatory treatments including corticosteroids.

**Keywords:** Myocarditis -Multisystem inflammatory syndrome in children- SARS-CoV-2 infection - cardiogenic shock- Disseminated Intravascular Coagulation- intravenous immunoglobulin- corticosteroids.

**Copyright © 2022 The Author(s):** This is an open-access article distributed under the terms of the Creative Commons Attribution 4.0 International License (CC BY-NC 4.0) which permits unrestricted use, distribution, and reproduction in any medium for non-commercial use provided the original author and source are credited.

## INTRODUCTION

The United States Centers for Disease Control and Prevention (CDC) and the World Health Organization (WHO) have proposed the following case definition of multisystem inflammatory syndrome in children (MIS-C) [1, 2]:

- Children and adolescents 0–19 years of age with fever > 3 days
- AND two of the following:
  - Rash or bilateral non-purulent conjunctivitis or muco-cutaneous inflammation signs (oral, hands or feet).
  - Hypotension or shock.
  - Features of myocardial dysfunction, pericarditis, valvulitis, or coronary abnormalities (including ECHO findings or elevated Troponin/NT-proBNP),
  - Evidence of coagulopathy (by PT, PTT, elevated d-Dimers).
  - Acute gastrointestinal problems (diarrhoea, vomiting, or abdominal pain).
- AND Elevated markers of inflammation such as ESR, C-reactive protein, or procalcitonin.
- AND No other obvious microbial cause of inflammation, including bacterial sepsis, staphylococcal or streptococcal shock syndromes.

- AND Evidence of COVID-19 (RT-PCR, antigen test or serology positive), or exposure to a suspected or confirmed COVID-19 case within the 4 weeks before the onset of symptoms.

Many children with MIS-C have received empirical treatment based on Kawasaki disease guidelines, with intravenous immunoglobulin (IVIG) alone or combined with corticosteroids [3].

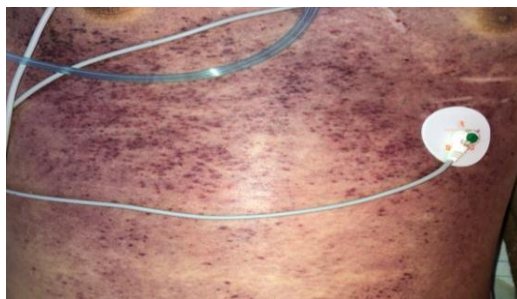
## CASE PRESENTATION

A 14-year-old girl was admitted to emergency department due to influenza syndrome as she presented: asthenia, myalgia, a dry cough and an epigastric pain associated to vomiting that has been evolving for 15 days. Without any cardiovascular risk factors, she has a family history of secondary parental consanguinity. During her hospitalization, she presented an aggravation of her symptomatology that evolved to cardiogenic shock defined by hypotension, tachycardia and the signs of tissue hypoperfusion, such as oliguria, cyanosis..., requiring initiation of inotropic drugs in addition to diuretics.

After stabilization of the patient, the physical examination revealed blood pressure of 110/68mmHg,

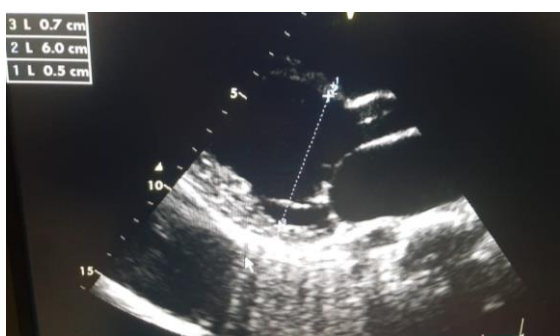**Citation:** Yasmina Malky, Halima Eljazouli, Hind Nabawi, Mohamed El Jamili, Saloua El karimi, Mustapha Hattaoui. Acute Myocarditis Revealing a Multisystem Inflammatory Syndrome Following SARS-CoV-2 Infection. Sch J Med Case Rep, 2022 Feb 10(2): 103-105.

heart rate of 112 b.p.m, oxygen saturation of 75% while breathing ambient air and 94% with oxygen, and body temperature of 38°C. She had mild crackles at lung bases, a regular heart rhythm, mild epigastric abdominal pain and purpuric stains at the thoraco-abdominal level (Figure 1).



**Figure 1: Purpuric spots do not fade with vitropressure at the thoraco-abdominal level**

A 12-lead electrocardiogram revealed sinus tachycardia. Transthoracic echocardiogram according to Z-score showed dilated left and right ventricles with global hypokinesia and severe biventricular systolic dysfunction (LVEF=26%) with moderate to medium mitral and tricuspid regurgitation (Figure 2).



**Figure 2: Transthoracic echocardiogram showed dilated left and right ventricles**

SARS -CoV-2 IgG (chemiluminescent microparticle immunoassay; Abbott) was positive.

His laboratory evaluation showed a platelet count of 63 G/l, prothrombin time (PT) of 36.3%, International Normalized Ratio (INR) of 2, activated Partial Thromboplastin Time of 32.7 seconds, Fibrinogen of 0.7 g/l, D-Dimer of 24 890 µg/l, procalcitonin of 1.76ng/ml, hypochromic and microcytic anemia with hemoglobin of 8.4 g/dl, ferritine of 1000 ng/ml, albumin of 25g/l. C-reactive protein was positive. Disseminated Intravascular Coagulation (DIC) was considered.

During her hospitalization, she developed a painful, swelling left upper extremity. Bilateral venous Doppler ultrasound showed acute Deep vein thrombosis within the basilic and humeral veins. For which the patient was treated with anticoagulant treatment (Fondaparinux sodium).

The treatment was based on the administration immunomodulatory treatment with intravenous immunoglobulin (IVIG) associated to anti-inflammatory treatments including Hydrocortisone hemisuccinate.

## DISCUSSION

Children account for only 1% to 2% of hospitalized patients with coronavirus disease 2019 [4]. However, in April 2020, severe systemic hyperinflammatory disease was reported in children in Europe and the United State, This novel entity, named multisystem inflammatory syndrome in children (MIS-C) [5] or pediatric multisystem inflammatory syndrome temporally associated with COVID-19 [6].

**\* MIS-C CDC Case Definition-** Fever (>24 hours reported or documented  $\geq 38.0^{\circ}\text{C}$ ) **AND** Laboratory evidence<sup>#</sup> of inflammation **AND** Illness requiring hospitalization **AND** Multisystem ( $\geq 2$ ) organ involvement (*i.e.* cardiac, renal, resp, gi, heme, derm or neuro) **AND** No alternative plausible diagnoses **AND** COVID 19 positivity/exposure  
SARS-CoV-2 RT-PCR positive currently **or** recently positive on Antibody testing **or** COVID-19 exposure within the 4 weeks prior to the onset of symptoms

<sup>#</sup> May include one or more of the following laboratory value abnormalities: reduced lymphocytes, low albumin, or elevations in any of the following (Neutrophil count, C-reactive protein (CRP), erythrocyte sedimentation rate (ESR), fibrinogen, procalcitonin, d-dimer, ferritin, lactic acid dehydrogenase (LDH), or interleukin 6 (IL-6)).

**Figure 3: The Case definition of multisystem inflammatory syndrome in children (MIS-C) proposed by CDC and WHO [1]**

Cardiac involvement is very common and present in 67-80% of children with MIS-C [7]. Cardiac involvement includes ventricular dysfunction, coronary artery aneurysms in a minority, conduction abnormalities, and arrhythmias [7]. Myocardial injury is attributed to an acute, dysregulated immune response related to a cytokine storm, endothelial injury, microvascular dysfunction, and ischemic injury [8].

COVID-19 infection causes widespread endothelial injury and activation of coagulation resulting in high fibrinogen, D-dimer, and Factor VIII, and low antithrombin III. It has been associated with high rates of venous thromboembolic events (VTE) including deep vein thromboses, pulmonary emboli, digital ischemia, arterial thrombosis, microvascular thrombosis and strokes [9]. Prophylactic anticoagulation with enoxaparin is reasonable to

consider in critically ill patients, and hospitalized patients with significant derangements of coagulation [9].

Initial treatment of MIS-C cardiac complications is focused on patient stabilization. In the patient with poor cardiac output, mechanical ventilation and inotropic support may be needed [7], A stepwise approach to immunomodulatory treatment is recommended, with intravenous immunoglobulin (IVIG) and/or corticosteroids considered as first tier therapy [10] In the study of Ouldal *et al.*, [3], treatment with IVIG and methylprednisolone vs IVIG alone was associated with a more favorable fever course.

Teresa R. Hennon *et al.*, [9] recommend giving IVIG 2 g/kg and aspirin 20–25 mg/kg/dose every 6 h (80–100 mg/kg/day) for all patients with KD-like illness, evidence of excessive inflammation (ferritin > 700 ng/mL, CRP > 30 g/dL, or multisystem organ failure), or cardiac involvement.

Cardiac involvement in MIS-c syndrome makes the prognosis of this disease. Therefore, it is prudent for cardiac screening to be completed early in hospital course; including measures of cardiac injury and ventricular dysfunction [9].

## CONCLUSION

MIS-C following SARS-CoV-2 infection is a serious disease, potentially fatal especially in the presence of cardiac and thrombotic complications. Treatment of patients with MIS-C often includes management of shock, use of immunomodulatory therapies, and use of thromboprophylaxis agents

## REFERENCES

- Holstein, B. Multisystem Inflammatory Syndrome in Children. *The Journal for Nurse Practitioners* 2021; 17, 941-945.
- Son, M. B. F., Friedman, K., Kaplan, S. L., Sundel, R., & Randolph, A. G. (2021). COVID-19: Multisystem inflammatory syndrome in children (MIS-C) clinical features, evaluation, and diagnosis. *Up to Date*.
- Ouldali, N., Toubiana, J., Antona, D., Javouhey, E., Madhi, F., Lorrot, M., ... & Bernardor, J. (2021). Association of intravenous immunoglobulins plus methylprednisolone vs immunoglobulins alone with course of fever in multisystem inflammatory syndrome in children. *Jama*, 325(9), 855-864.
- Wu, Z., & McGoogan, J. M. (2020). Characteristics of and important lessons from the coronavirus disease 2019 (COVID-19) outbreak in China: summary of a report of 72 314 cases from the Chinese Center for Disease Control and Prevention. *Jama*, 323(13), 1239-1242.
- Centers for Disease Control and Prevention. Multisystem inflammatory syndrome in children (MIS-C) associated with coronavirus disease 2019 (COVID-19). Published May 14, 2020. Accessed January 19, 2021.
- European Centre for Disease Prevention and Control. Rapid risk assessment: paediatric inflammatory multisystem syndrome and SARS-CoV-2 infection in children. Published May 15, 2020. Accessed January 19, 2021.
- Wu, E. Y., & Campbell, M. J. (2021). Cardiac Manifestations of Multisystem Inflammatory Syndrome in Children (MIS-C) Following COVID-19. *Current cardiology reports*, 23(11), 1-9.
- Schlapbach, L. J., Andre, M. C., Grazioli, S., Schöbi, N., Ritz, N., Aebi, C., ... & Rimensberger, P. C. (2021). Best practice recommendations for the diagnosis and management of children with pediatric inflammatory multisystem syndrome temporally associated with SARS-CoV-2 (PIMS-TS; multisystem inflammatory syndrome in children, MIS-C) in Switzerland. *Frontiers in pediatrics*, 9, 396.
- Hennon, T. R., Penque, M. D., Abdul-Aziz, R., Alibrahim, O. S., McGreevy, M. B., Prout, A. J., ... & Hicar, M. D. (2020). COVID-19 associated multisystem inflammatory syndrome in children (MIS-C) guidelines; a Western New York approach. *Progress in pediatric cardiology*.
- Henderson, L. A., Canna, S. W., Friedman, K. G., Gorelik, M., Lapidus, S. K., Bassiri, H., ... & Mehta, J. J. (2020). American College of Rheumatology clinical guidance for pediatric patients with multisystem inflammatory syndrome in children (MIS-C) associated with SARS-CoV-2 and hyperinflammation in COVID-19. Version 1. *Arthritis & Rheumatology (Hoboken, Nj)*.