

Orbital Hemangiopericytoma Revealed by Exophthalmia: A Case Report

Essaber Hatim^{1*}, Jerguigue Hounayda¹, Latib Rachida¹, Omor Youssef¹

¹Department of Radiology, National Oncologic Institute, CHU ibn Sina Rabat, Morocco

DOI: [10.36347/sjmcr.2022.v10i02.023](https://doi.org/10.36347/sjmcr.2022.v10i02.023)

| Received: 02.01.2022 | Accepted: 11.02.2022 | Published: 19.02.2022

*Corresponding author: Essaber Hatim

Department of Radiology, National Oncologic Institute, CHU ibn Sina Rabat, Morocco

Abstract

Case Report

The orbital location of hemangiopericytoma is rare, marked by its slow and unpredictable evolution with malignant potential and a high rate of recurrence and distant metastasis, hence the need for regular and prolonged monitoring, we report a case of hemangiopericytoma at man of 38 years old.

Keywords: orbital, hemangiopericytoma, exophthalmia, case, report, MRI.

Copyright © 2022 The Author(s): This is an open-access article distributed under the terms of the Creative Commons Attribution 4.0 International License (CC BY-NC 4.0) which permits unrestricted use, distribution, and reproduction in any medium for non-commercial use provided the original author and source are credited.

INTRODUCTION

Hemangiopericytoma is a mesenchymal tumour derived from the pericyte, its orbital location is rare, it represents 0.8 to 3% of primary orbital tumours. It has an expansive character, slowly evolving, which can lead to serious ophthalmological complications.

CASE REPORT

A 38-year-old man with no notable history; who presents to the ophthalmology department for painful swelling of the left eye with ptosis evolving for a year associated with a depressive syndrome. The ophthalmological examination had objectified a limitation of ocular movements with a decrease in visual acuity of the left eye without sign of diplopia.

A cerebral CT scan was first requested and showed a spontaneously hyperdense left frontal extra-axial process with orbital extension by encompassing the optic nerve and the eyeball with grade 1 exophthalmia (Figure 1). The complement MRI, highlighted the hypervascular character by its vivid and heterogeneous enhancement after injection of Gadolinium (Figure 2).

The patient benefited from a total excision of the tumour with enucleation of the affected eye with good control after 1 year postoperatively. The anatomopathological study had confirmed the diagnosis of hemangiopericytoma.

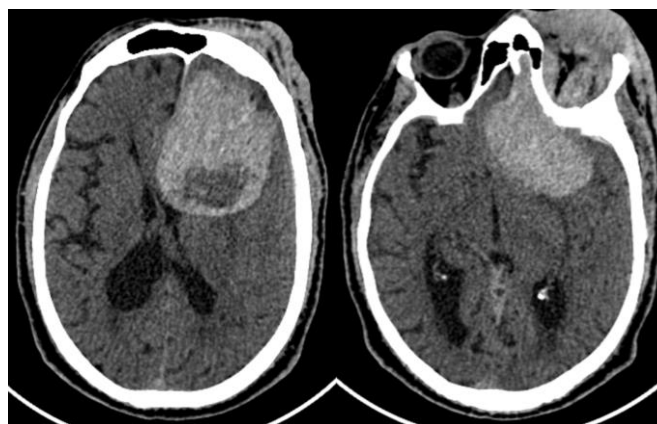


Figure 1: Computed tomography (CT): show spontaneously hyperdense extra axial process with central zone hypodense. Extending to the left orbit

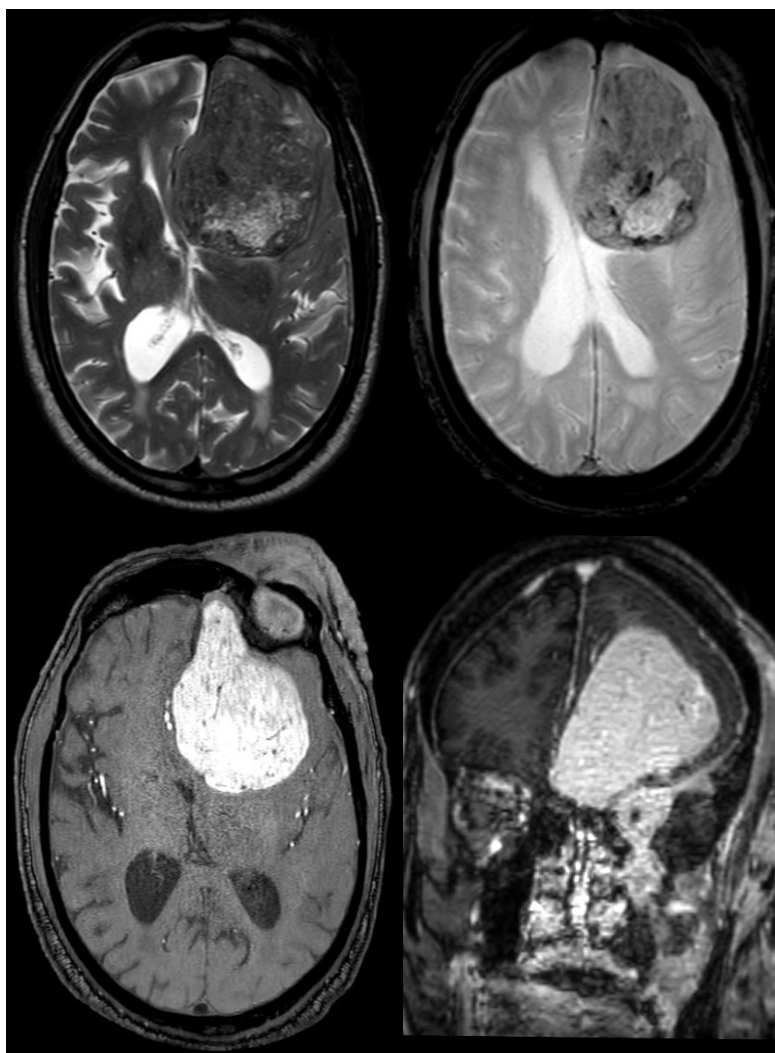


Figure 2: MRI complement was performed, on axial T2, and T2*, axial and coronal T1 with gadolinium demonstrating that this tumor is isointense to grey matter , containing multiple flow voids seen on T2* with vivid and heterogenous enhancement and extension to the left orbit

DISCUSSION

Hemangiopericytoma was first described in 1942 by Stout and Murra [1] as rare vascular tumor, which originate from the proliferation of pericytes that surround the capillaries, supporting them and regulating their lumen. It generally affects the retroperitoneum and the lower limbs, its incidence in the head and neck region is less common accounts 16% and less than 5% affect the orbit [2] according to Shields's series, only 1% of all orbital biopsies are hemangiopericytoma [3].

Most of the orbital tumors arise in one side without apparent predisposition for race or sex [2], Orbital hemangiopericytoma almost always manifests with slowly increasing proptosis with or without associated pain and blurring or loss of vision.

The ultrasonography examine usually illustrate this tumor as an a well-defined mass with low to intermediate echogenicity [4]. On computed tomography (CT) imaging, it is seen as a well-circumscribed mass occupying either the extraconal or

the intraconal space, which intensely enhances with contrast [5]. On magnetic resonance images, it is isointense in T1, hyper signal in T2 with intense enhancement.

As the clinical and radiological features are non specific, the final diagnosis of hemangiopericytoma must depend on histopathological examination of the surgical specimen.

The histopathological appearance shows tumor cells arranged in a fascicular pattern, interrupted by slit-like staghorn vessels and Immunohistochemical preparation reveals a diffuse immunoreactivity to CD34.

Its treatment is above all surgical by total excision of the tumor, the other methods are complementary such as embolization, radiotherapy, and chemotherapy to improve the local and general prognosis especially when the excision is incomplete.

CONCLUSION

The orbital location of hemangiopericytoma is rare, marked by its slow and unpredictable evolution with malignant potential and a high rate of recurrence and distant metastasis, hence the need for regular and prolonged monitoring.

REFERENCES

1. Stout, A. P., & Murray, M. R. (1942). Hemangiopericytoma: a vascular tumor featuring Zimmermann's pericytes. *Annals of surgery*, 116(1), 26-33.
2. Henderson, J. W., & Farrow, G. M. (1978). Primary orbital hemangiopericytoma: An aggressive and potentially malignant neoplasm. *Archives of Ophthalmology*, 96(4), 666-673.
3. Shields, J. A., Shields, C. L., & Scartozzi, R. (2004). Survey of 1264 patients with orbital tumors and simulating lesions: The 2002 Montgomery Lecture, part 1. *Ophthalmology*, 111(5), 997-1008.
4. Byrne, S. F., & Green, R. L. (1992). *Ultrasound of the eye and orbit*. St Louis: Mosby; p. 339-342.
5. Karcioğlu, Z. A., Nasr, A. M., & Haik, B. G. (1997). Orbital hemangiopericytoma: clinical and morphologic features. *American journal of ophthalmology*, 124(5), 661-672.