

## Laparoscopic Transabdominal Cerclage: Steps and Benefits: Case Series with Review of Literature

Dr. C.P Dadhich<sup>1</sup>, Dr. Nidhi Mehta<sup>\*2</sup>, Dr. Tripti Dadhich<sup>3</sup>, Dr. Anita<sup>4</sup>

<sup>1</sup>Hod and Director, Department of Obstetrics and Gynaecology Department, EHCC Hospital, Jaipur, Rajasthan, India

<sup>2</sup>Clinical associate, Department of Obstetrics and Gynaecology Department, EHCC Hospital, Jaipur, Rajasthan, India

<sup>3</sup>Senior consultant, Department of Obstetrics and Gynaecology Department, EHCC Hospital, Jaipur, Rajasthan, India

<sup>4</sup>Associate consultant, Department of Obstetrics and Gynaecology Department, EHCC Hospital, Jaipur, Rajasthan, India

\*Corresponding author: Dr. Nidhi Mehta | Received: 01.03.2019 | Accepted: 05.03.2019 | Published: 30.03.2019

DOI: [10.21276/sasjs.2019.5.3.9](https://doi.org/10.21276/sasjs.2019.5.3.9)

### Abstract

### Original Research Article

**Introduction:** Cervical insufficiency complicates about 0.1-1% of all pregnancies. Cervical incompetence; as it is called may lead to repetitive pregnancy losses and cause physical and emotional turmoil. **Aim and objectives:** To emphasize the steps and benefits of laparoscopic Trans abdominal cerclage in cases of recurrent pregnancy loss and to evaluate intra operative and long-term pregnancy outcomes after laparoscopic cervical cerclage performed either as an interval procedure or during early pregnancy. **Material and methods:** We studied 10 cases of recurrent pregnancy loss with history of failure of vaginal cerclage in previous pregnancies and offered laparoscopic transabdominal cerclage -6 interval and 4 during pregnancy. **Results:** 9 Patients out of 10 who were offered laparoscopic transabdominal cerclage had successful pregnancy outcomes. **Conclusion:** The transabdominal cerclage procedure aims to strengthen the cervix by placing a suture at the level of the internal os. Laparoscopic cerclage has the general advantages of minimal access surgery, such as avoiding a large abdominal incision, short hospital stay and quick recovery.

**Keywords:** Cervical insufficiency; recurrent pregnancy loss; transabdominal cerclage.

**Copyright @ 2019:** This is an open-access article distributed under the terms of the Creative Commons Attribution license which permits unrestricted use, distribution, and reproduction in any medium for non-commercial use (NonCommercial, or CC-BY-NC) provided the original author and source are credited.

### INTRODUCTION

Cervical insufficiency complicates about 0.1-1% of all pregnancies. Cervical incompetence; as it is called may lead to repetitive pregnancy losses and cause physical and emotional turmoil [1]. Cervical

cerclage helps prevent miscarriage or premature labor caused by cervical incompetence. The procedure is successful in 85% to 90% of cases. Different types of cervical cerclage procedures are being used (figure 1).

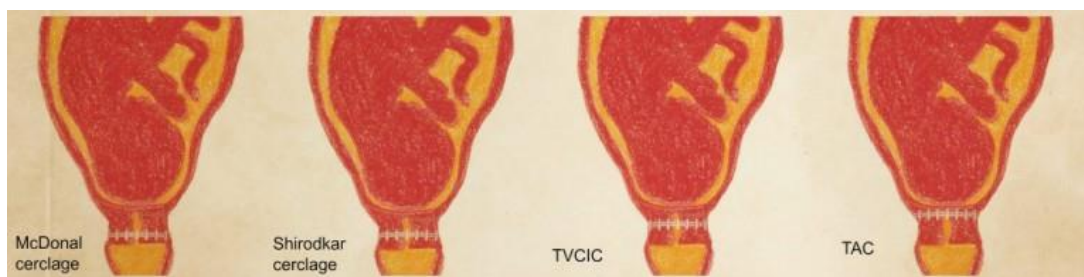
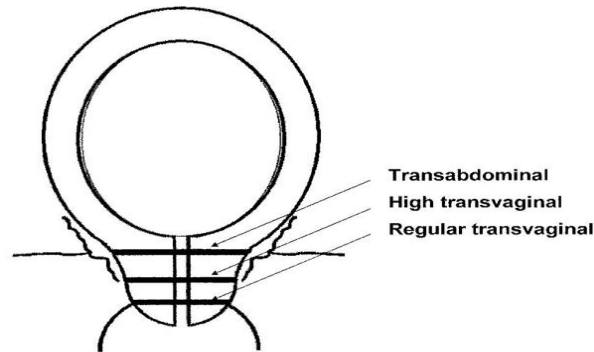


Fig-1: Different types of cerclage

It appears that the integrity of the cervix is partly assured by its length. In normal pregnancy the cervix is more than 40 mm long at 18 weeks of gestation. This is manifested by approximately 2 cm of

vaginal cervix and 2 cm of supravaginal cervix. Logically, a cervical strengthening suture would be most effective at the internal os. (figure 2)[2].



**Fig-2: level of suture placement in different types of cerclage**

Although a cerclage placed transvaginally has been effective for many patients, a transabdominal approach allows for the cerclage to be placed more proximal to the internal os, allows for a more secure stitch, eliminates risk of foreign body material from entering the vagina, and can be used in subsequent pregnancies [3].

#### **Aim and objectives**

The aim of the present study was to evaluate intraoperative and long-term pregnancy outcomes after laparoscopic cervical cerclage, performed either as an interval procedure or during early pregnancy. 2. To emphasize the steps and benefits of laparoscopic transabdominal cerclage in cases of recurrent pregnancy loss.

#### **MATERIALS AND METHODS**

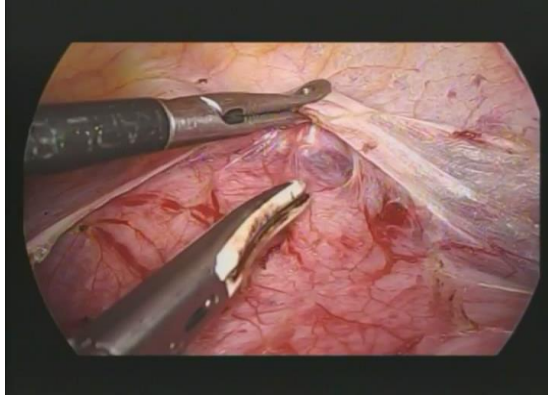
Between January 2017 and March 2019 a retrospective single cohort study was done of all women with a previous poor obstetric history who underwent laparoscopic abdominal cerclage (LAC) placement either prior to conception or during pregnancy.

#### **Inclusion criteria for selected patients undergoing LAC [4]**

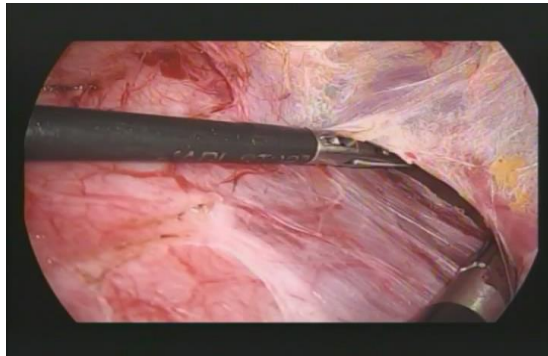
- H/O one or more second trimester abortions, specifically painless cervical dilatation.
- H/O previous cerclage for painless cervical dilatation.
- Painless cervical dilatation diagnosed in second trimester pregnancy
- H/O premature delivery before 34 wks, USG indicating cervical length < 25 mm.

- Sometimes twin pregnancy.

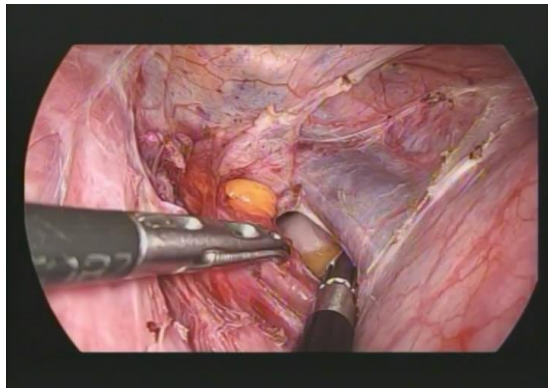
Written informed consent after extensive counselling was obtained from all patients before performing LAC. All women were informed about the need for elective cesarean section. LAC was performed under general anesthesia by a single operator according to the standard surgical and perioperative protocol of our hospital. In pregnant patients an abdominal sonography was performed preoperatively to confirm fetal vitality and gestational age. Prophylactic antibiotic treatment was administered. Tocolysis was performed for 48 h in pregnant women, starting the evening before surgery, and no uterine manipulator was used. In non-pregnant women a uterine manipulator or a Hegar size 8 was inserted to mobilize the uterus. All patients underwent laparoscopy using the Veress technique to create a pneumoperitoneum with an intraabdominal pressure of 10 mmHg. A 10-mm optical trocar was placed supraumbilically and a 30° scope was used during all procedures. 2 accessory ports made. After checking the abdominal cavity, the vesico-cervical space was identified after mobilization of the bladder. The peritoneal opening was extended laterally and a window created in posterior broad ligament and the course of uterine vessels identified on both sides. An ethibond No. 2 suture was passed medial to the uterine vessels on both sides and it was tied anteriorly at the cervicoisthmic junction. The procedure ended with reperitonization. All pregnant women underwent abdominal ultrasound to check fetal viability with Doppler imaging of the uterine artery an elective cesarean section was planned at 37 weeks of gestation.



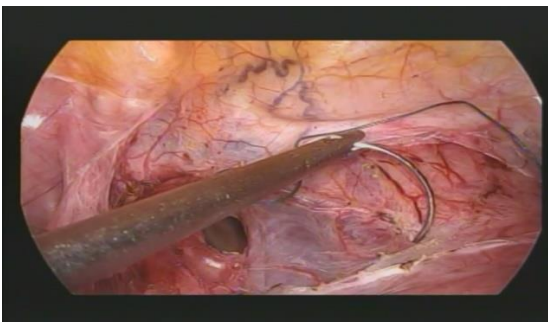**Fig-3: Separation of bladder by dissection of vesicouterine space**



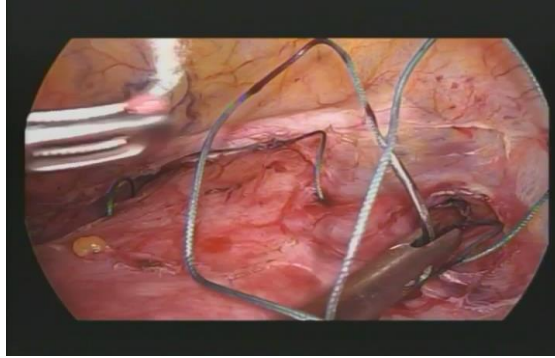
**Fig-4: Opening or window in right broad ligament**



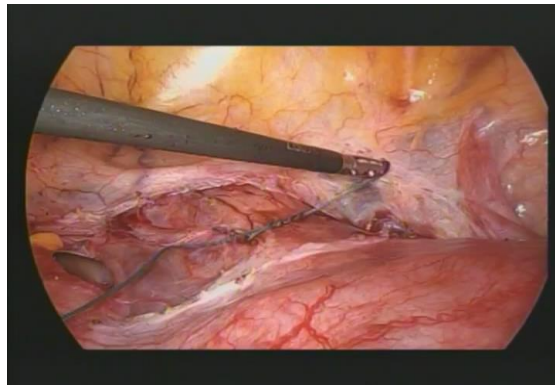
**Fig-5: Identification of uterine vessels**



**Fig-6: Passing of suture at the level of internal os medial to uterine vessels**



**Fig-7: Passing of suture at the level of internal os on the contralateral side**



**Fig-8: Tying of the knot anteriorly at the level of internal os/cervicoisthmic junction**

Absolute contraindications to the above procedure include Vaginal bleeding, Preterm labour. Intra uterine infection, Fetal anomaly incompatible with life. Relative contra indication- protruding membranes [5].

pregnancy outcomes. Only one developed leaking per vaginum at earlier gestation (20 weeks) and the pregnancy had to be terminated by opening of the stitch by laparoscopy and followed by hysterotomy. Baby shifted to NICU but did not survive.

**RESULTS:** 9 Patients out of 10 who were offered laparoscopic transabdominal cerclage had successful

**Table-1**

Clinical characteristics of the study population.	Results
<b>Characteristics</b>	
TVC = transvaginal cerclage; LEEP = loop electrosurgical excision procedure; n = number	
Maternal age, years (mean $\pm$ SD)	33 $\pm$ 4
Gravidity (mean $\pm$ SD)	4 $\pm$ 0.8
Nullipara (n)	1
Patients with previous term pregnancy (n)	2
Adverse obstetric history (n)	
• early miscarriage	3
• late miscarriage	4
• prior failed TVC	5
• prior cervical surgery (cone, LEEP)	2
• ectopic pregnancy (n)	2
• preterm delivery	2
Gestational age at intervention, weeks (mean $\pm$ SD)	12.4 $\pm$ 1.6
TVC = transvaginal cerclage; LEEP = loop electrosurgical excision procedure; n = number	

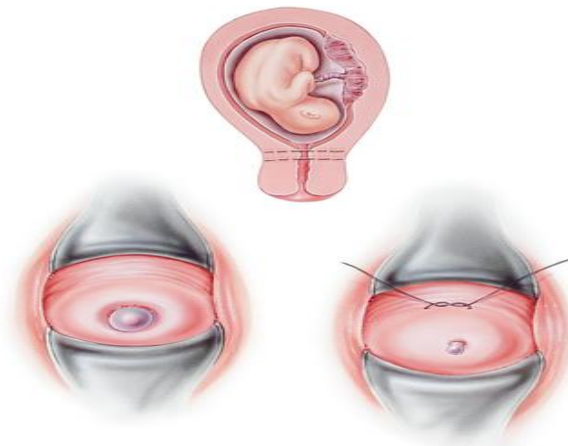
**Table-2: Outcomes of the study population**

Characteristics	Results
NICU = neonatal intensive care unit; GA = gestational age; n = number.* bleeding, conversion to laparotomy, injury to adjacent structures. ** Overall pregnancy success is defined as the number of live births per number of pregnancies.	
Intraoperative complications (n)*	0
Estimated blood loss (ml)	< 20
Operating time, minutes (mean $\pm$ SD)	55 $\pm$ 10
Mean hospital stay, days (mean $\pm$ SD)	2.6 $\pm$ 0.9
Pregnancy outcome (n)	
• first trimester spontaneous abortion	0
• preterm delivery (< 34 weeks)	1
• GA at delivery, weeks (mean $\pm$ SD)	37.3 $\pm$ 1.9
Overall pregnancy success** (> 14 GA, %)	90%
• neonatal death (n)	0
• transfer to NICU (n)	0

## DISCUSSION

Cervical incompetence is a premature dilatation of the cervix leading to recurrent mid-trimester pregnancy loss or early premature labour. It is thought that the condition is caused by a defect in the strength of the cervical tissue either congenitally or acquired, resulting in the inability to maintain a pregnancy [6]. The treatment consists of placing a purse string suture around the cervix. The conventional method is placing the sutures vaginally, but it might not be possible in extremely short, deformed and scarred cervixes or in the absence of a

cervix. Abdominal cerclage has been advocated by several authors to overcome this problem. Benson and Durfee first described the transabdominal approach to cerclage placement in 1965. Placement of cerclage at the cervicoisthmic junction may be effective in decreasing the incidence of pregnancy loss in certain patients with cervical insufficiency in patients with 1. Congenitally short or amputated cervix; 2. Cervical scarring that would prevent a transvaginal approach 3. Failure of prior vaginal cerclage. 4. Cervical fibroid [7].

**Fig-9**

### Benefits of abdominal cerclage [8]

- Higher placement relative to the level of the internal os
- Decreased incidence of slippage
- Ability to leave the stitch in place between pregnancies.

### Benefits of laparoscopic cerclage [9]

- reduced blood loss
- reduced postoperative pain
- fewer adhesions
- decreased length of hospital stay
- overall faster recovery time

## CONCLUSION

Laparoscopic transabdominal cerclage is a safe and effective procedure resulting in favourable obstetric outcomes in women with a poor obstetric history. For

optimal success the procedure requires the correct surgical expertise, equipment and appropriate patient selection [10].

## REVIEW OF LITERATURE

**Table-4**

Study	Data collection	Patients (n)	Pregnant at surgery (n)	GA at surgery *	Surgical complications, % (pregnancy group)	Surgical complications, % (interval group)	Number of pregnancies	GA at delivery	Fetal survival rate, %
CS = cohort study, n = number, * = mean, NA = not available, ** = unclear whether retrospective or prospective, GA = gestational age. Surgical complications include small bowel injury, bladder injury, blood loss > 400 ml, uterine perforation, pelvic infection, fever, conversion to laparotomy.									
Luo <i>et al.</i> , 2014 [20]	prospective CS	19	0	NA	NA	0	15	36.4	90
Riiskjaer <i>et al.</i> , 2012 [12]	prospective CS	52	0	NA	NA	0	45	37.4	88.8
Whittle, 2009 [22]	prospective CS	65	31	14	19.3	2.9	67	35.8	89
Carter <i>et al.</i> 2009 [16]	prospective CS	12	6	11	0	0	9	35.5	80
Adeset <i>et al.</i> 2014 [21]	retrospective CS	64	3	NA	0	1.6	35	35.8	95.8
Burger <i>et al.</i> 2012 [13]	retrospective CS	66	0	NA	NA	4.5	35	37.2	90
Mingione, 2003 [19]	retrospective CS	11	0	NA	NA	9	12	37.9	83
Cho, 2003 [24]	retrospective CS	20	20	12	0	0	19	> 34	95
Nicolet <i>et al.</i> 2009 [18]	retrospective CS	14	0	NA	NA	0	6	38	83
Liddell and Lo, 2008 [17]	CS**	11	0	NA	NA	0	10	37	9

## REFERENCES

1. D. Bolla, L. Raio, S. Imboden, and M. D. Mueller PMCID: PMC4554519 PMID: 26366003.
2. Gibb D, Saridogan E. The role of transabdominal cervical cerclage techniques in maternity care. *The Obstetrician & Gynaecologist*. 2016 Apr 1;18(2):117-25.
3. Tusheva OA, Cohen SL, McElrath TF, Einarsson JI. Laparoscopic placement of cervical cerclage. *Reviews in Obstetrics and Gynecology*. 2012;5(3-4):e158.
4. *Geburtshilfe Frauenheilkd*. 2015 Aug; 75(8):
5. RCOG MAY2011 Green Top Guidelines.
6. *Gynecological Surgery* March 2007, Volume 4, Issue 1, pp 45–48.
7. *BioMed Research International*. 2004;2004(5)
8. *Rev Obstet Gynecol*. 2012; 5(3-4): e158–e165.
9. *JLS*. 2005 Oct-Dec; 9(4): 491–493.
10. *Aust N Z J Obstet Gynaecol*. 2018 Dec;58(6):606-611.