

The Loss of the Guidewire of a Central Venous Catheter: A Case Report

Meskine Amine^{1*}, A. Koundi¹, N. Kartite¹, M. Sammali¹, M. Bensghir¹, A. Baite¹

¹Department of Anesthesia- Intensive Care, Mohammed-V Military Training, Hospital, Faculty of Medicine and Pharmacy of Rabat, University Mohammed V, Rabat, Morocco

DOI: [10.36347/sjmc.2022.v10i02.026](https://doi.org/10.36347/sjmc.2022.v10i02.026)

| Received: 12.01.2022 | Accepted: 17.02.2022 | Published: 21.02.2022

*Corresponding author: Meskine Amine

Department of Anesthesia- Intensive Care, Mohammed-V Military Training, Hospital, Faculty of Medicine and Pharmacy of Rabat, University Mohammed V, Rabat, Morocco

Abstract

Case Report

Central venous catheterization is a common procedure in emergency and intensive care unit, but it has a high risk of certain complications especially infectious and thromboembolic, which remains frequent. We report a case of a rare complication of catheter insertion which was the migration of guidewire through the circulating system from the femoral vein to the jugular vein. The management of guidewire migration can be either interventional or surgical depending on the experience of the surgical and interventional radiology team.

Keywords: Guidewire -loss-central venous catheterization-interventional radiology.

Copyright © 2022 The Author(s): This is an open-access article distributed under the terms of the Creative Commons Attribution 4.0 International License (CC BY-NC 4.0) which permits unrestricted use, distribution, and reproduction in any medium for non-commercial use provided the original author and source are credited.

INTRODUCTION

Central venous catheterization is a routine procedure largely performed in emergency and intensive care unit, and like any procedure, complications can occur; such as infection thrombosis, pneumothorax or hematoma.

However, the migration of the guide wire remains a rare, dangerous but also avoidable complication, preventable by doing the procedure by a skilled doctor and considering the standards described for central vein catheter insertion.

We report a case of intravascular femoral-cava migration of the guidewire after attempted catheterization of the femoral vein using the Seldinger technique in a patient with difficult venous access.

OBSERVATION

This is a 54-year-old patient, followed for a breast tumor under chemotherapy, complicated by cardiac toxicity and lymphedema affecting the neck, thorax and upper limbs performing shielding. The patient presented to the emergency department for respiratory distress with orthopnea and signs of struggle.

The clinical examination shows a confused patient with a GCS 14/15, SpO₂ of 91% under O₂ and a BP of 140/85mmHg, on auscultation: presence of bilateral crackles at the bases, the rest of the examination is without particularities, apart the shielding. The Electrocardiogram shows no repolarization or ST segment disorders, chest X-ray: Bilateral Para hilar fluffy opacities and the transthoracic echocardiography indicates a segmental kinetics disorder.

After stabilization and conditioning, and given the absence of peripheral venous access available, central venous access was required. The left femoral route was chosen, and during the ascent of the catheter on a metal guide, the latter slipped and migrated along the femoral vein, then the right common iliac vein as far as intracardiac and secondarily in the superior vena cava; the chest x-ray, performed after the loss shows the intracardiac position of the guide wire (Figure 1).

After advice from the vascular surgeon, the patient was admitted to the operating room for removal of the guidewire, the venous access was a femoral approach on the contralateral side, taken by a senior, under ultrasound guidance. The guide wire was removed under intravenous sedation, the patient was admitted to intensive care postoperatively and no

cardiac or vascular complications were noted. The

patient was discharged 5 days later.

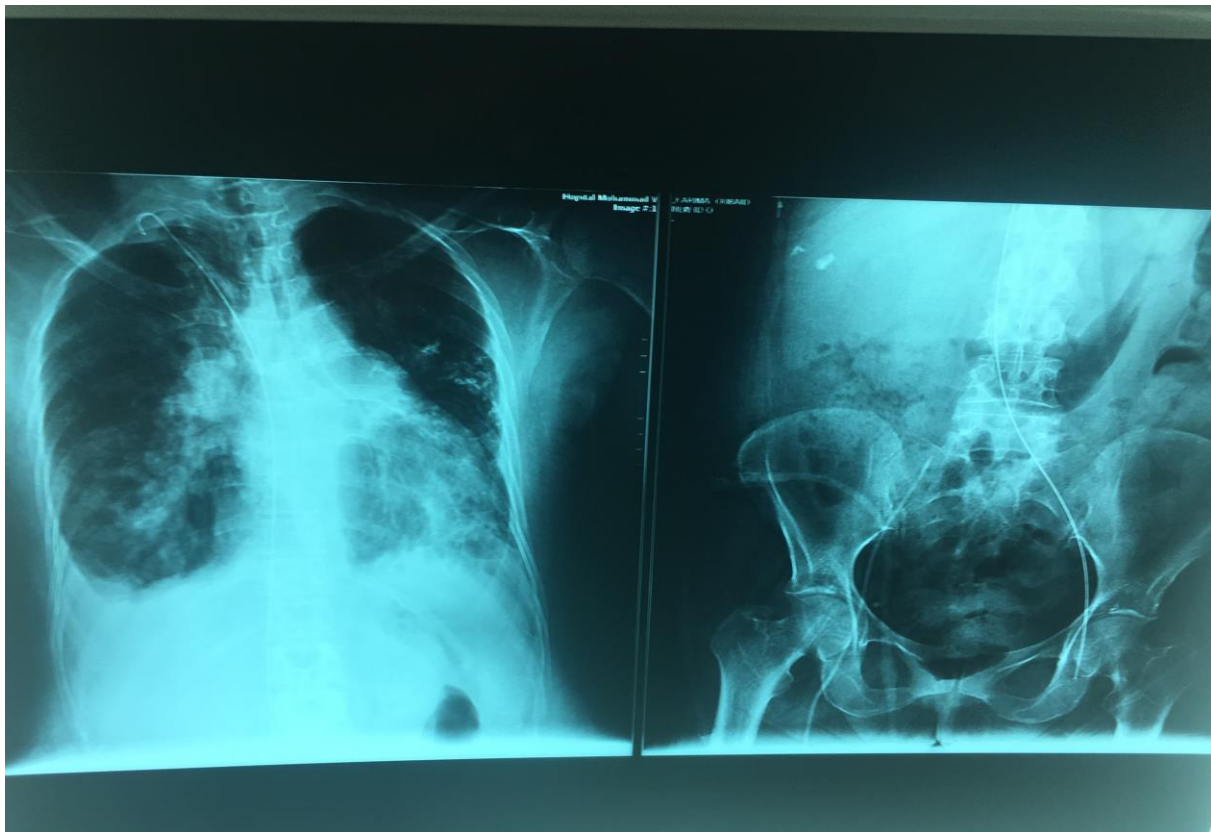


Figure 1: Chest radiography shows guide wire in the inferior vena cava extending into the superior vena cava

DISCUSSION

Central venous catheterization (CVC) is a routine technique used in the emergency department and intensive care unit, different veins, such as the jugular, sub-clavian or femoral might be chosen depending on the clinical case, the indication and the catheter type.

Several complications may occur such as infection, failure to place the catheter, arterial puncture, improper catheter position, misplacement, kinking, breakage, thrombosis, embolism, arrhythmias, pneumothorax, and hematoma, which may arise in as many as 15% of these procedures [1-4].

Another less common complication is the loss of the guidewire when catheterizing, it is a rare one but remains very dangerous and also avoidable, we report a case of the loss of the guidewire after catheterization of femoral vein and migration into superior vena cava and intracardiac, the catheterization in our case was performed by a first-year resident in the emergency room without supervision. Schummer W reported 4 cases that showed predisposing factors for incorrect intravascular placement of a guide wire; this included inattention, inexperienced—operators, either in terms of their methods or in the central venous cannulation, inadequate supervision of trainees and overtired staff [5].

During central venous catheterization, guide wire-related complications are uncommon and essentially preventable. The following precautions should be taken [5]:

- Inspect the wire for defects before insertion
- Consider a guide wire to be a delicate and fragile instrument
- When resistance to insertion is met, remove and inspect the wire for damage, reposition the introducer so that no resistance to its passage is felt
- Particular caution should be used when attempting central catheter placement in patients who are predisposed to thrombosis or have had repeated catheterizations of a particular vessel
- If multiple manipulations are required, reinspect the wire and replace it if necessary
- Pass the catheter over the wire into the vein
- Ensure that the wire is visible at the proximal end before the catheter is advanced
- The catheter should be “railroaded” over the guide wire into the vein, holding the wire, and not pushing catheter and wire together into the vein
- Always inspect the wire for complete removal at the end of the procedure
- Hold onto the wire at all times until it is removed from the vessel.

The management of the guidewire is critical because of vital complications in the acute setting or the long term. It can be removed by interventional radiology or surgery.

The interventional approach includes several methods, The loop snare technique is the method of choice in most of the cases because of its safety, feasibility, relative ease of use, high success rate with low complication rates, and its cost-effectiveness [1, 6, 7].

Carroll and al use this technique in their study to remove a guidewire after CVC. When there is adherence or no obvious free edge, basket snares are the best option and if adherence is too strong, we could use grasping forceps. The choice of device for retrieval is surgeon dependent and many tools have been found to be useful to retrieve intravascular objects [8].

However, when extraction is not possible, surgery remains the ultimate solution, but when the risks of endovascular or surgical removal outweigh the benefits and the guidewire is stable or strongly adherent, leaving the guidewire remains an option. In our case, given the location of the guidewire and the risk of tearing of the cardiac tissue as well as the inexperience of the surgical team with regard to interventional methods, surgery was preferred

CONCLUSION

The loss of the guidewire of central venous catheter is a rare, dangerous but avoidable complication, it can be avoided by following procedures and guidelines, the management has to be quick but thoughtful, in consultation with radiologist, vascular surgeon and the intensivist.

Funding: None

Conflict of interest: None

REFERENCES

1. Zhao, S., Wang, Z., & Zhao, Y. (2019). Loss of guidewire and its sequelae after central venous catheterization: A case report. *Medicine*, 98(29).
2. Abuhasna, S., Abdallah, D., & ur Rahman, M. (2011). The forgotten guide wire: A rare complication of hemodialysis catheter insertion. *Journal of Clinical Imaging Science*, 1.
3. Wolf, F., Scherthner, R. E., Dirisamer, A., Schoder, M., Funovics, M., Kettenbach, J., ... & Cejna, M. (2008). Endovascular management of lost or misplaced intravascular objects: experiences of 12 years. *Cardiovascular and interventional radiology*, 31(3), 563-568.
4. Pérez-Díez, D., Salgado-Fernández, J., Vázquez-González, N., Calviño-Santos, R., Vázquez-Rodríguez, J. M., Aldama-López, G., ... & Castro-Beiras, A. (2007). Percutaneous retrieval of a lost guidewire that caused cardiac tamponade. *Circulation*, 115(24), e629-e631.
5. Srivastav, R., Yadav, V., & Sharma, D. (2013). Loss of guide wire: a lesson learnt review of literature. *Journal of Surgical Technique and Case Report*, 5(2), 78-81.
6. Cekirge, S., Weiss, J. P., Foster, R. G., Neiman, H. L., & McLean, G. K. (1993). Percutaneous retrieval of foreign bodies: experience with the nitinol Goose Neck snare. *Journal of Vascular and Interventional Radiology*, 4(6), 805-810.
7. Dotter, C. T., Rösch, J. O. S. E. F., & Bilbao, M. K. (1971). Transluminal extraction of catheter and guide fragments from the heart and great vessels; 29 collected cases. *The American journal of roentgenology, radium therapy, and nuclear medicine*, 111(3), 467-472.
8. Carroll, M. I., Ahanchi, S. S., Kim, J. H., & Panneton, J. M. (2013). Endovascular foreign body retrieval. *Journal of Vascular Surgery*, 57(2), 459-463.