

Kartagener's Syndrome a Case Report and Literature Review

Diarra Daouda^{1*}, Boussa Tressia Carole¹, Salihou Abdoufatih¹, Tabakh Houria¹, Siwane Abdellatif¹, Touil Najwa¹, Kacimi Omar¹, Chikhaoui Nabil¹

¹Emergency Radiology Service, Radiology Department, Hospital, Ibn Rochd University Hospital Center of Casablanca, Hassan II University of Casablanca, Morocco

DOI: [10.36347/sasjm.2022.v08i02.011](https://doi.org/10.36347/sasjm.2022.v08i02.011)

| Received: 05.01.2022 | Accepted: 09.02.2022 | Published: 28.02.2022

*Corresponding author: Diarra Daouda

Emergency Radiology Service, Radiology Department, Hospital, Ibn Rochd University Hospital Center of Casablanca, Hassan II University of Casablanca, Morocco

Abstract

Case Report

Kartagener syndrome is a very rare genetic disorder with autosomal recessive inheritance, characterized by a triad of chronic bronchorrhea with bronchiectasis, chronic sinusitis and situs inversus. It is part of a syndrome of primary ciliary immobility called primary ciliary dyskinesia. Imaging is the key examination in the workup of Kartagener's syndrome and is usually discovered during a CT scan. The treatment is essentially symptomatic and preventive based on the treatment of episodes of respiratory superinfections, physiotherapy for bronchial drainage and anti-influenza and anti-pneumococcal vaccinations.

We report a case of Kartagener's syndrome collected in the radiology department of the emergency room.

Keywords: Kartagener syndrome – Imaging.

Copyright © 2022 The Author(s): This is an open-access article distributed under the terms of the Creative Commons Attribution 4.0 International License (CC BY-NC 4.0) which permits unrestricted use, distribution, and reproduction in any medium for non-commercial use provided the original author and source are credited.

INTRODUCTION

Kartagener syndrome is a rare autosomal recessive congenital disorder that occurs in approximately one in 15,000 individuals [1]. This syndrome is part of a primary ciliary immobility syndrome called primary ciliary dyskinesia (PCD) characterized by a clinical triad: chronic bronchorrhea with bronchiectasis, chronic sinusitis and complete or incomplete situs inversus [2]. The symptoms of Kartagener's syndrome are a consequence of defective cilia motility found in the airways resulting in recurrent lung infections caused by mucus stasis in the bronchi. Airway infections during the course of the disease classically occur in childhood [1].

We report a case of Kartagener's syndrome discovered during a workup for dyspnea. We will focus on the contribution of imaging in the diagnosis of this rare pathology and review the literature. Early, adapted and multidisciplinary management improves the evolutionary profile by delaying and reducing the frequency of complications.

CASE PRESENTATION

This is a 45-year-old male smoker who presented with a history of episodes of nasal

obstruction, productive cough, asthmatic dyspnea, headache, and transient fever since childhood. No family history of chronic respiratory disease and consanguinity in the parents. The patient's clinical examination noted a right-sided peak shock with discrete crackling rales on pulmonary auscultation. There were no external genitalia abnormalities.

Blondeau's radiograph noted an absence of pneumatization of the frontal sinus (Fig 1). The frontal chest radiograph showed a dextrocardia, a right aortic button, a bronchial syndrome with a left basal pulmonary condensation focus, associated with a left juxta hilar rounded opacity surmounted by a thin linear opacity starting from the top of the left lung parallel to and outside the left edge of the mediastinum; inversion with a mirrored position of the hepatic opacity on the left and the gastric air sac on the right (Fig 2).

In view of these findings, Kartagener's syndrome is suspected. The thoraco abdominopelvic CT scan with injection of non-iodinated ionic contrast (Fig 3 a, b and c) was performed and confirmed the complete situs inversus (dextrocardia, liver, gallbladder on the left; stomach and polysplenia on the right), associated with bronchiectasis and rotational anomaly involved the

lungs; abdominal vessels with inferior vena cava on the left of the aorta, retro aortic renal vein, as well as the colonic frame on the right and the small bowel on the left.

The prostate and testicular ultrasound were without abnormalities. The histology of the ENT biopsy showed a structural abnormality of the vibratory cilia. The family investigation did not reveal any consanguinity or similar cases in the siblings.

ICONOGRAPHY

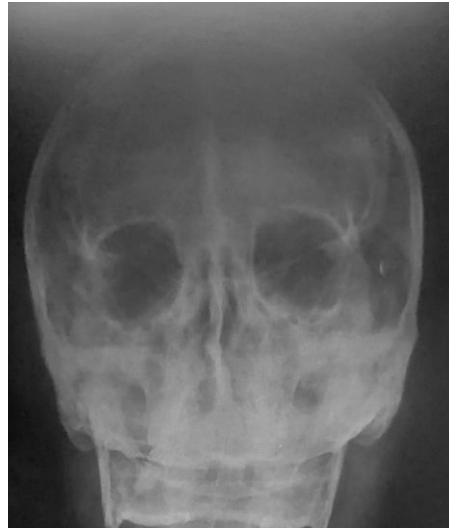

Fig-1: Blondeau's radiograph: absence of pneumatization of the frontal sinus

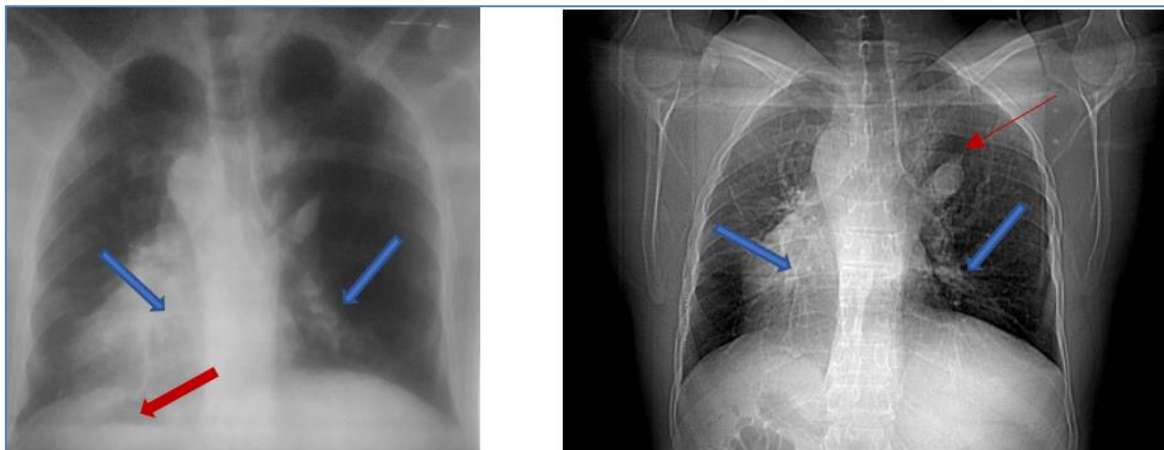


Fig-2: Frontal chest radiograph and scout View: dextrocardia, right aortic knob, bronchial syndrome with left basal lung condensation focus, associated with left juxta hilar rounded opacity surmounted by a thin linear opacity starting from the apex of the left lung parallel and outside the left edge of the mediastinum; inversion with a mirror position of the hepatic opacity on the left and the gastric air sac on the right.

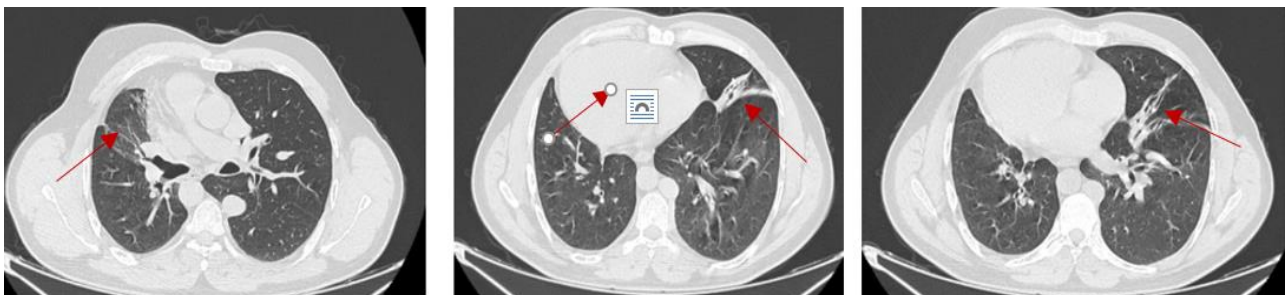


Fig-3. a: Chest CT axial section in parenchymal window: presence of bilateral cylindrical and moniliform pulmonary bronchiectasis in the middle lobar and lingular areas, with a focus of condensation in the left lung with an air bronchogram

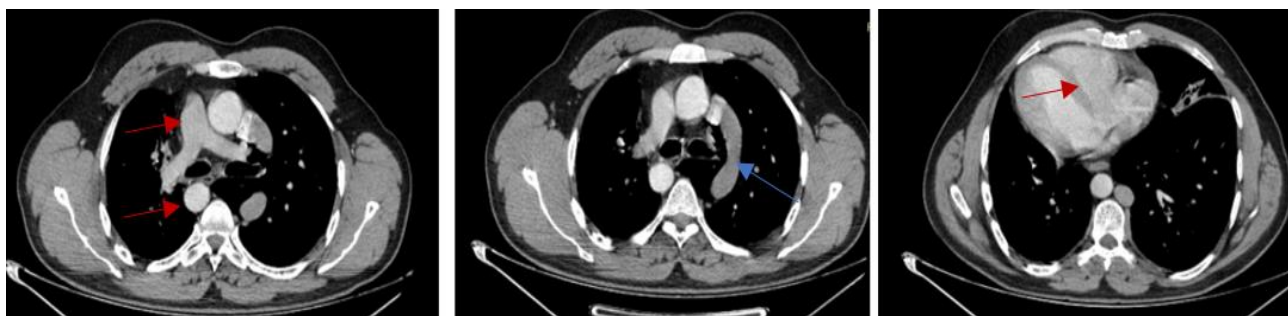

Fig-3.b: Thoracic CT axial section in mediastinal window with injection of non-ionic iodinated contrast: dextrocardia with thoracic aorta on the right of the vertebra, the trunk of the pulmonary artery on the right associated with a left hemi azygos vein following the path of a left upper lobar supernumerary scissure

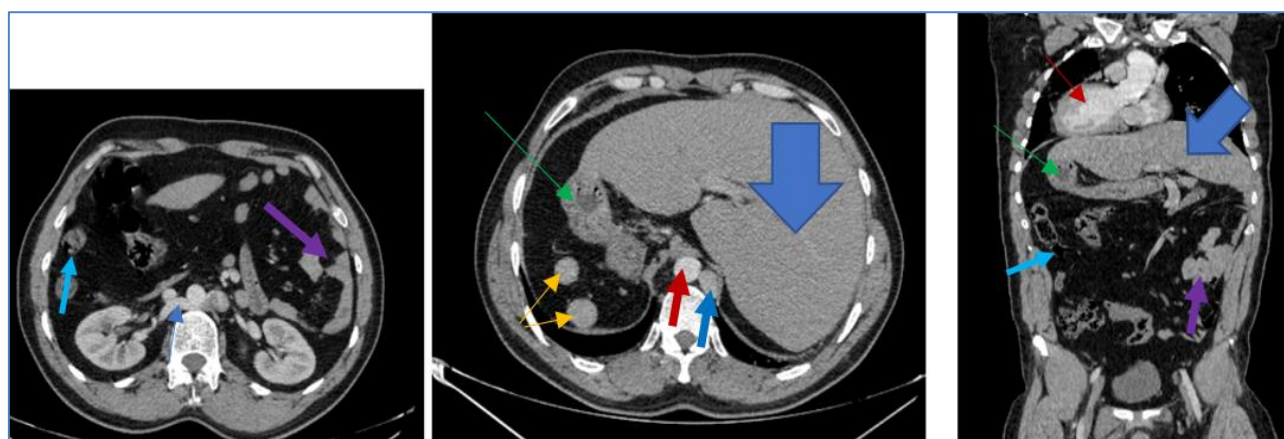


Fig-3.c: Abdominopelvic CT scan axial and coronal section with injection of non-ionic iodinated contrast medium: total situs inversus, liver on the left, stomach and polysplenia on the right; inferior vena cava on the left of the aorta, retro aortic renal vein, as well as the colonic frame on the right and small intestine on the left

DISCUSSION

Kartagener's syndrome is a rare autosomal recessive genetic disorder first described by Manes Kartagener in 1935. It represents 50% of primary ciliary dyskinesias (PCD). It is a genetic mutation for dynein at chromosomes 5, 9 and 7, responsible for a morphological and/or functional abnormality of the cilia [3]. This disease is rare, with a higher incidence in certain populations with a high rate of consanguinity. It combines chronic sinusitis, complete or incomplete situs inversus and bronchiectasis [3]. The circumstances of discovery are diverse, but the main sign of appeal is recurrent bronchopneumonia. The symptomatology of Kartagener syndrome is dominated by respiratory signs beginning in childhood that are present in all patients and are specific only by their chronicity and annual recurrence [2]. The symptoms are chronic bronchial congestion, a daily cough with mucopurulent secretions and phases of exacerbations and superinfections. ENT involvement, particularly of the upper airways, is marked by sinusitis and otitis related to the abnormal mucociliary clearance.

The age of diagnosis of the disease varies according to the authors, with a revelation of the disease in childhood, especially in the neonatal period, with a male predominance [4-7].

Imaging plays a central role in the assessment of the disease. Bronchiectasis is constant in Kartagener's syndrome, of which it is part of the definition, it is declining and most often involves the middle lobe, lingula and lower lobes. These bronchiectasis appear early, and are found in 60% to 70% of cases, at an average age of eight years [8]. These lesions increase with age and bronchial dilatations are present in 100% of cases in adults [9]. Thus in our case the thoracoabdominal CT scan showed dextrocardia with complete situs inversus and right polysplenia, as well as the absence of pneumatization of the frontal sinus on the Blondeau radiograph.

Nasosinus polyposis is present in approximately 30% of patients. Several factors are involved in their occurrence (genetic, immunological factors, intolerance to acetylsalicylic acid). They are seen in several nasosinus inflammatory diseases and are a non-specific expression of the underlying mucosal disease [4-6].

The specificity in adulthood concerns fertility. Kartagener's syndrome may also be associated with sperm flagellar dysfunction, which is responsible for male infertility [6]. The role of fertility abnormalities in females, possibly related to a tubal cilia defect, is still

poorly understood and often requires the use of in vitro fertilization techniques [10].

The differential diagnosis is made with other conditions that sometimes have a similar clinical picture (cystic fibrosis, immune deficiency, and respiratory allergic reactions...), with acquired ciliary anomalies or secondary ciliary dyskinesias (SCD), and other ciliopathies [11].

The overall management of Kartagener's syndrome is based essentially on respiratory physiotherapy for bronchial drainage, antibiotic therapy in case of superinfection, and adequate vaccination coverage against influenza and pneumococcal disease [4-6]. The evolution of the respiratory pathology is variable and depends in particular on how early the diagnosis is made and on the rigor of the management [1].

CONCLUSION

Kartagener's syndrome remains a rare and disabling disease but can be compatible with a normal life if managed early. Early positive diagnosis of Kartagener's syndrome is the key to improving its prognosis and preventing complications. However, in forms with significant pulmonary lesions, the patient's prognosis is at risk in the short term, due to severe multi-visceral damage. Currently, the proposed treatments are symptomatic.

Competing Interests

The authors declare no conflict of interest.

Contributions from authors

All the authors contributed to the conduct of this work. They also state that they have read and approved the final version of the manuscript.

REFERENCES

- Escudier, E., Tamalet, A., Prulière-Escabasse, V., Roger, G., Coste, A. (2006). Primary ciliary dyskinesia. *French review of allergology and clinical immunology*, 46(6); 530-537. [Google Scholar]
- Gabrielle, A. P., Honjaniana, R., Christian, T., Hasina, R. N. L., & Ahmad, A. (2017). Chronic cough revealing a Kartagener syndrome: about one case.
- Moreau, L. (2000). Clinical forms of primary bronchial ciliary dyskinesia in children: about 13 observations. Thesis of medicine Nancy (France), 137:217. [Google Scholar]
- El Alaoui Abdelilah. (2014). Kartagener's syndrome: prototype of primary ciliary dyskinesia. Thesis of medicine Morocco, 182:127.
- Melki, B., Hamdi, B., Berraies, A., El Bey, R., Ammar, J., Hamzaoui, A. (2015). Kartagener syndrome: about 6 cases. *Journal of respiratory diseases*, Jan;32(Supplément):A142–A2143. [Google Scholar]
- Moreau, L. (2000). Clinical forms of primary bronchial ciliary dyskinesia in children: about 13 observations. Thesis of medicine Nancy (France), 137; 217. [Google Scholar]
- Bemba, E., Lee, P., Odzili, I., Franck, A., Mongo, N., Solange, F. (2015). Kartagener's syndrome in an adolescent girl. *J Fran Viet Pneu*. 2015;18(6):1-60. [Google Scholar]
- Noone, P. G., Leigh, M. W., Sannuti, A., Minnix, S. L., Carson, J. L., Hazucha, M., ... & Knowles, M. R. (2004). Primary ciliary dyskinesia: diagnostic and phenotypic features. *American journal of respiratory and critical care medicine*, 169(4), 459-467.
- Santamaria, F., Montella, S., Tiddens, H.A. (2008). Structural and functional lung disease in primary ciliary dyskinesia. *Chest*, 134:351-7.
- Tamalet, A. (2012). Congenital ciliary dyskinesia: who and how to explore? Primary ciliary dyskinesia: Who and how to confirm the diagnosis? *18(2011):921-925*.
- Carceller, M. A., Roig, M. M., Payá, X. M., & Gimeno, J. C. (2010). Discinesia ciliar primaria. Ciliopatías. *Acta Otorrinolaringológica Española*, 61(2), 149-159.