

## Dermatofibrosarcoma Protuberans: Two Cases Report and Review of the Literature

Malak Bennani<sup>1\*</sup>, Basma Mahrouch<sup>1</sup>, Ahmed Anis Agouzal<sup>1</sup>, Ikram Zaytoun<sup>1</sup>, Nassima Kadri<sup>1</sup>, Amina Sabiq<sup>1</sup>, Fatim Ezzahra Ballouk<sup>1</sup>, Soulaïmane Kandry Rody<sup>1</sup>, Hind Riahi Idrissi<sup>1</sup>, Mouna Darfaoui<sup>1</sup>, Abdelhamid El Omrani<sup>1</sup>, Mouna Khouchani<sup>1</sup>

<sup>1</sup>Radiation Oncology Department, Mohammed VI Teaching Hospital, Marrakesh, Morocco

DOI: [10.36347/sjmcr.2022.v10i03.006](https://doi.org/10.36347/sjmcr.2022.v10i03.006)

| Received: 23.01.2022 | Accepted: 28.02.2022 | Published: 06.03.2022

\*Corresponding author: Malak Bennani

Radiation Oncology Department, Mohammed VI Teaching Hospital, Marrakesh, Morocco

### Abstract

### Case Report

Dermatofibrosarcoma protuberans (DFSP) is a rare soft tissue tumor that is locally aggressive and has a high rate of recurrence after surgical intervention. We report a case of a 73-year-old man presented an abdominal mass evolving over 30 years. Physical examination revealed a multinodular lesion of 12x10 cm, slightly fixed to the deep tissues. A skin biopsy was performed. Histopathological examination confirmed the diagnosis of dermatofibrosarcoma protuberans. CT imaging was suggestive of a subcutaneous supra-fascial mass of 67x89x98 mm, infiltrating the left rectus abdominis muscle. The patient underwent surgical resection of the tumor and the muscle's fascia. The lateral margins were between 5 to 13 cm. The deep resection margin was at 0,1 cm. The mainstay of treatment for DFSP is complete surgical excision with histologically negative margins. Radiation should be considered as an adjuvant to resection if margins are positive.

**Keywords:** Dermatofibrosarcoma Protuberans, surgery, radiation therapy.

**Copyright © 2022 The Author(s):** This is an open-access article distributed under the terms of the Creative Commons Attribution 4.0 International License (CC BY-NC 4.0) which permits unrestricted use, distribution, and reproduction in any medium for non-commercial use provided the original author and source are credited.

## INTRODUCTION

Dermatofibrosarcoma protuberans (DFSP) is an uncommon, cutaneous fibro histiocytic neoplasm that was first described by Darier and Ferrand in 1924. It accounts for 1% of all soft tissue sarcomas, with an incidence of 0,8 to 5 cases per million population each year [1]. Most commonly, it involves trunk (62%) followed by extremities (25%) and head and neck (13%) [2]. It is a slow growing tumor with locally aggressive behaviour [3]. Even though they rarely metastasize, these tumors tend to recur locally. We herein present a case of Dermatofibrosarcoma Protuberans located in the abdomen.

## CASE REPORT 1

A 73-year-old man presented to the hospital for an abdominal mass located on the left iliac fossa. The history started 30 years ago, with a painless cutaneous lesion that began as a small pink plaque. The lesion had grown gradually and slowly over the years. Physical examination revealed a multinodular lesion of 12x10 cm, slightly fixed to the deep tissues. There were no palpable cervical or axillary lymph nodes.

A skin biopsy was performed. Histopathological examination revealed spindle cell mesenchymal proliferation, in a storiform pattern. Immunostaining for CD34 showed diffuse and moderate cytoplasmic expression in neoplastic cells, confirming the diagnosis of dermatofibrosarcoma protuberans.

Computed Tomography imaging was suggestive of a subcutaneous supra-fascial mass of 67x89x98 mm, infiltrating the left rectus abdominis muscle (Figure 1).

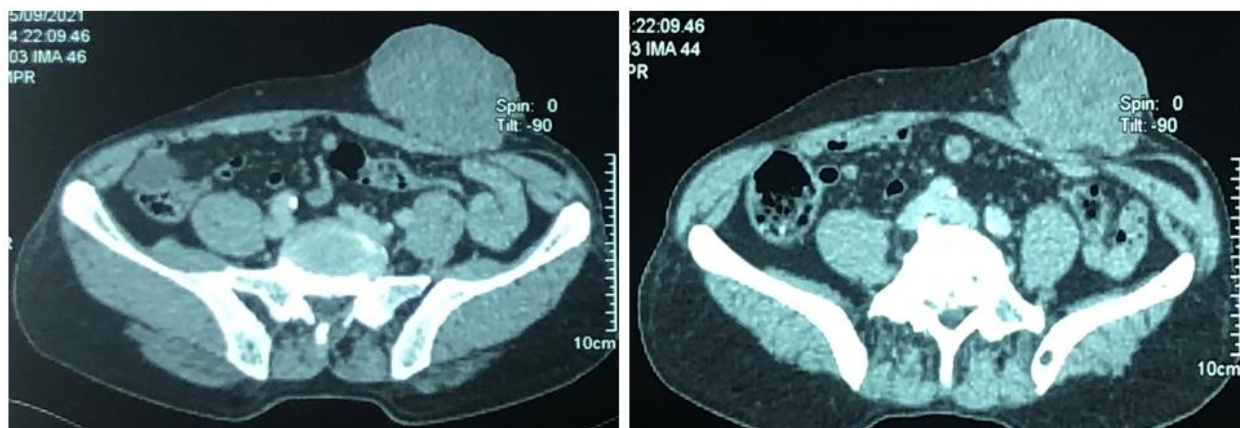
The patient underwent surgical resection of the tumor and the muscle's fascia. The lateral margins were between 5 to 13 cm.

Gross pathological examination revealed a white and firm neoplasm measuring 11x9x7 mm at the greatest dimension, with haemorrhagic and fibrous remodelling. Histopathological examination revealed that the tumor was composed of elongated, monomorphic spindle cells arranged in a storiform pattern in dermo hypodermic layers. The nuclei are

**Citation:** Malak Bennani, Basma Mahrouch, Ahmed Anis Agouzal, Ikram Zaytoun, Nassima Kadri, Amina Sabiq, Fatim Ezzahra Ballouk, Soulaïmane Kandry Rody, Hind Riahi Idrissi, Mouna Darfaoui, Abdelhamid El Omrani, Mouna Khouchani. Dermatofibrosarcoma Protuberans: Two Cases Report and Review of the Literature. Sch J Med Case Rep, 2022 Mar 10(3): 194-197.

elongated, and the cytoplasm is eosinophilic. The deep resection margin was at 0,1 cm. No adjuvant therapy

was indicated for this patient.



**Figure 1: Axial abdominal CT scan demonstrating a subcutaneous supra-fascial mass infiltrating the left rectus abdominis muscle**

## CASE REPORT 2

A 42-year-old woman presented a large mass located at the left side of the lower back. The history started 20 years ago; she underwent surgery 4 times with a recurrence each time. On physical examination, a large, firm, painless, multinodular mass was found with no sign of localized heat or redness.

The recent CT scan showed an ulcero-budding process of the soft cutaneous and subcutaneous tissues of the left lumbar region without local or regional infiltration. The patient underwent a wide excision, with 5 cm lateral and deep resection margins, combined with subsequent cutaneous flap reconstruction. The histological examination confirmed the known diagnosis of Dermatofibrosarcoma protuberans. Nine months after surgery, no local recurrence is evident.

## DISCUSSION

DFSPs constitute <0.1% of all malignant tumor cases and <1% of all soft tissue sarcomas. It is a rare, low to intermediate grade soft tissue sarcoma deriving from the dermal layer of the skin [4]. DFSP typically follows an indolent clinical course with a high rate of local recurrence because of its infiltrative behaviour, but low metastatic potential [8]. Indeed, less than 5% of patients with DFSP develop metastatic disease. When distant recurrences do occur, they are found in regional lymph nodes and the lung [5].

Men tend to be affected slightly more often than women, with a male to female sex ratio of 1,1 [6]. The median age of diagnosis is typically between 22 to 59 years [7]. There are no specific risk factors associated with DFSP, it can arise on healthy skin or on chronically damaged areas.

Clinically, DFSP classically presents as a slowly progressive, painless cutaneous lesion that may

begin as a violet or pink plaque. With time, the tumor evolves into multiple “protuberant” nodules that may infiltrate the subcutaneous tissue, fascia, muscles and even bone [9]. Most often, there is a delay in diagnosis secondary to patient and physician neglect, and a history of the lesion being present for multiple years is more the rule than the exception.

In the early stages, DFSP should be differentiated from lipomas, epidermal cysts, keloids, dermatofibroma, and nodular fasciitis. In the later stages, the differential diagnosis should consider pyogenic granuloma, Kaposi sarcoma, and other soft tissue sarcomas [10].

Histologically, Dermatofibrosarcoma protuberans is a deep dermal subcutaneous neoplasm.

Microscopic examination will reveal a monomorphous spindle cell proliferation in a storiform pattern, often surrounding and trapping subcutaneous fat to form a honeycomb appearance [5]. The fibroblast-like tumor cells tend to be uniform with hyperchromatic and elongated nuclei. Accurate diagnosis requires immunohistochemical staining to verify the diagnosis and exclude cellular dermatofibroma, the benign lesion with which DFSP is most commonly confused. The cells of a DFSP are CD34-positive and factor XIIIa-negative [11].

The mainstay of treatment for DFSP is complete surgical excision with histologically negative margins. Because of its storiform growth pattern and pseudopod-like extensions, incomplete excisions are common. Recurrence rates are high as 50% have been described in literature [12]. Recurrence is most common for tumors of the head and neck, likely because it is difficult to achieve wide margins in these areas. Adequate primary resection is important, as the recurring tumor is usually more locally destructive at

the time of re-excision, with a higher likelihood of sarcomatous transformation and invasion into the underlying fascia. Wide local excision is the most common method of excision, with studies suggesting 2 to 3 cm margins [13]. The rate of recurrence depends on the resection margins. In series where resection margins of five cm were used, recurrence rates were less than 5% [14].

Mohs micrographic surgery is an alternative to wide local excision, as it allows the clinician to analyze 100% of the tumor margins, identify microscopic extensions, and remove them while conserving healthy tissue [15].

Postoperative radiotherapy is highly recommended for patients with large or recurrent tumours, especially when wide excision with a negative margin would result in a significant functional or cosmetic deficit, in order to achieve a lower recurrence rate [16]. Historically, it had been thought that DFSP was resistant to radiotherapy [17, 18]. However, there have been multiple reports of the utility of radiation as the sole form therapy in isolated cases with adequate local control [19]. Subsequently, radiation was proposed as an adjunct to surgery when close or positive margins were left behind.

Ballo *et al.*, reviewed 19 consecutive patients treated with radiation as an adjuvant to surgical therapy, six of whom had positive margins [20]. They observed only one recurrence in the 19 patients. Sun *et al.*, evaluated the treatment results of 34 evaluable patients undergoing either surgery alone or in conjunction with radiation [21]. Ten patients received postoperative radiation. Of the 24 patients who underwent surgery alone, nine had local recurrence (37.5%). Only one of the ten patients (10%) that received both radiation and surgery recurred. The recommended dose is 50 Gray if R0 surgery and 60 Gray if R1 surgery, 2 Gray per fraction, 5 days a week. As for exclusive radiotherapy, it can be attempted in unresectable tumours, inoperable patients or patients refusing any surgical treatment and the dose can go up to 66 Gray [22].

With current surgical techniques, local recurrence rates should be low after complete excision to histological negative margins, and adjuvant radiotherapy is not indicated. If, however, a maximal effort at resecting a DFSP results in persistently positive margins, radiotherapy should be considered and is associated with good long-term control rates [8].

Most local recurrences appear within the first three postoperative years, with 50 % presenting within the first year of surgery. However, recurrences after five years are also reported. Thus, it is important to follow-up these patients for long-term [23].

## CONCLUSION

DFS Protuberans is a rare cutaneous tumor, with slow local evolution occurring over several years. It is distinguished by its diagnostic difficulty, its tendency to recurrence and the rarity of its metastases which are essentially pulmonary. The diagnosis is often evoked clinically and confirmed histologically. In the treatment of DFSP, the focus should be on complete surgical resection of the tumor with histologically confirmed negative margins. The prognosis is good when the treatment is well carried out but nevertheless requires lifelong clinical monitoring, knowing that certain cases of recurrence have been described very late.

## REFERENCES

- Allen, A., Ahn, C., & Sangüeza, O. P. (2019). Dermatofibrosarcoma protuberans. *Dermatologic Clinics*, 37(4), 483-488.
- Madden, C., Spector, A., Siddiqui, S., Mirkin, G., Yim, J., & Hao, X. (2019). Dermatofibrosarcoma protuberans on adult toes: a case report and review of the literature. *Anticancer Research*, 39(4), 2105-2111.
- Sharma, D., Singh, G., Kakkar, N., & Jha, V. (2017). Orbital dermatofibrosarcoma protuberans with frontal and ethmoid sinus involvement: A case report and brief review of literature. *Indian Journal of Ophthalmology*, 65(9), 892-894.
- Eguzo, K., Camazine, B., & Milner, D. (2014). Giant dermatofibrosarcoma protuberans of the face and scalp: a case report. *International journal of dermatology*, 53(6), 767-772.
- Harati, K., Lange, K., Goertz, O., Lahmer, A., Kapalschinski, N., Stricker, I., ... & Daigeler, A. (2017). A single-institutional review of 68 patients with dermatofibrosarcoma protuberans: wide re-excision after inadequate previous surgery results in a high rate of local control. *World Journal of Surgical Oncology*, 15(1), 1-9.
- Bogucki, B., Neuhaus, I., & Hurst, E. A. (2012). Dermatofibrosarcoma protuberans: a review of the literature. *Dermatologic surgery*, 38(4), 537-551.
- Saiag, P., Grob, J. J., Lebbe, C., Malvehy, J., Del Marmol, V., Pehamberger, H., ... & Garbe, C. (2015). Diagnosis and treatment of dermatofibrosarcoma protuberans. European consensus-based interdisciplinary guideline. *European journal of cancer*, 51(17), 2604-2608.
- Luu, C., Messina, J. L., Brohl, A. S., & Sondak, V. K. (2017). Dermatofibrosarcoma protuberans. *Textbook of uncommon cancer*, 994-1001.
- Stivala, A., Lombardo, G. A., Pompili, G., Tarico, M. S., Frassetta, F., & Perrotta, R. E. (2012). Dermatofibrosarcoma protuberans: Our experience of 59 cases. *Oncology Letters*, 4(5), 1047-1055.
- Angouridakis, N., Kafas, P., Jerjes, W., Triaridis,

- S., Upile, T., Karkavelas, G., & Nikolaou, A. (2011). Dermatofibrosarcoma protuberans with fibrosarcomatous transformation of the head and neck. *Head & Neck Oncology*, 3(1), 1-7.
11. Billings, S. D., & Folpe, A. L. (2004). Cutaneous and subcutaneous fibrohistiocytic tumors of intermediate malignancy: an update. *The American journal of dermatopathology*, 26(2), 141-155.
  12. Farma, J. M., Ammori, J. B., Zager, J. S., Marzban, S. S., Bui, M. M., Bichakjian, C. K., ... & Sondak, V. K. (2010). Dermatofibrosarcoma protuberans: how wide should we resect?. *Annals of surgical oncology*, 17(8), 2112-2118.
  13. Acosta, A. E., & Vélez, C. S. (2017). Dermatofibrosarcoma protuberans. *Current treatment options in oncology*, 18(9), 1-14.
  14. Chang, C. K., Jacobs, I. A., & Salti, G. I. (2004). Outcomes of surgery for dermatofibrosarcoma protuberans. *European Journal of Surgical Oncology (EJSO)*, 30(3), 341-345.
  15. Veronese, F., Boggio, P., Tiberio, R., Gattoni, M., Fava, P., Caliendo, V., ... & Savoia, P. (2017). Wide local excision vs. Mohs Tübingen technique in the treatment of dermatofibrosarcoma protuberans: a two-centre retrospective study and literature review. *Journal of the European Academy of Dermatology and Venereology*, 31(12), 2069-2076.
  16. Chen, Y. T., Tu, W. T., Lee, W. R., & Huang, Y. C. (2016). The efficacy of adjuvant radiotherapy in dermatofibrosarcoma protuberans: a systemic review and meta-analysis. *Journal of the European Academy of Dermatology and Venereology*, 30(7), 1107-1114.
  17. Mark, R. J., Bailet, J. W., Tran, L. M., Poen, J., Fu, Y. S., & Calcaterra, T. C. (1993). Dermatofibrosarcoma protuberans of the head and neck: a report of 16 cases. *Archives of Otolaryngology-Head & Neck Surgery*, 119(8), 891-896.
  18. EB, H. (1962). Dermatofibrosarcoma protuberans. A study of 115 cases. *Cancer*, 15, 717-725.
  19. Marks, L. B., Suit, H. D., Rosenberg, A. E., & Wood, W. C. (1989). Dermatofibrosarcoma protuberans treated with radiation therapy. *International Journal of Radiation Oncology\* Biology\* Physics*, 17(2), 379-384.
  20. Ballo, M. T., Zagars, G. K., Pisters, P., & Alan Pollack, M. D. (1998). The role of radiation therapy in the management of dermatofibrosarcoma protuberans. *International Journal of Radiation Oncology\* Biology\* Physics*, 40(4), 823-827.
  21. Sun, L. M., Wang, C. J., Huang, C. C., Leung, S. W., Chen, H. C., Fang, F. M., ... & Lee, S. P. (2000). Dermatofibrosarcoma protuberans: treatment results of 35 cases. *Radiotherapy and oncology*, 57(2), 175-181.
  22. El Kacemi, H., Aissa, A., Bazine, A., Kebdani, T., Bougtab, A., & Benjaafar, N. (2014). Dermatofibrosarcome de Darier et Ferrand: à propos de 38 cas. *The Pan African Medical Journal*, 19.
  23. Paramythiotis, D., Stavrou, G., Panagiotou, D., Petrakis, G., & Michalopoulos, A. (2016). Dermatofibrosarcoma protuberans: a case report and review of the literature. *Hippokratia*, 20(1), 80-83.