

## Inflammatory Strom after COVID-19 Vaccine

M. A. Bouraghda<sup>1\*</sup>, N. Megherbi<sup>1</sup>, S. Belmahdi<sup>1</sup>, I. Ais<sup>1</sup>, K. Mouchen<sup>1</sup>

<sup>1</sup>Blida University Hospital, Ouled Yaïch, Algeria

DOI: [10.36347/sjmcr.2022.v10i03.010](https://doi.org/10.36347/sjmcr.2022.v10i03.010)

| Received: 03.02.2022 | Accepted: 08.02.2022 | Published: 13.03.2022

\*Corresponding author: M. A. Bouraghda  
Blida University Hospital, Ouled Yaïch, Algeria

### Abstract

### Case Report

The current global pandemic of COVID19 is likely going to last even longer, the particular reason for this circumstance is the absence of an efficient antiviral treatment, Acute myocarditis and coronary thrombosis was described as majors sides effects of vaccination.

We report the case of a 65 years women who presented a acute coronary syndrome associated with myocarditis few days after Covid-19 vaccine.

**Keywords:** Covid 19 Vaccine, myocarditis, acute coronary syndrome, inflammation, coronary thrombosis.

**Copyright © 2022 The Author(s):** This is an open-access article distributed under the terms of the Creative Commons Attribution **4.0 International License (CC BY-NC 4.0)** which permits unrestricted use, distribution, and reproduction in any medium for non-commercial use provided the original author and source are credited.

## INTRODUCTION

The current global pandemic of COVID19 is likely going to last even longer, the particular reason for this circumstance is the absence of an efficient antiviral treatment, yet, on the other hand, the development of vaccines seems to be one of available option.

Acute myocarditis is one of many unwanted side effects detected after vaccination; clinical presentation can vary from a simple chest pain to a deadly cardiogenic choc.

## OBSERVATION

We are going to report the case of a 65 years old female patient, on Telmisartant for hypertension, with no other medical or surgical history, who consulted cardiac emergency department 7 days after getting her second dose of SINOPHARM vaccine, with retrosternal chest pain evolving for 12 hours.

The first examination found an afebrile patient, hemodynamically stable and eupneic at rest, no signs of flu-like syndrome, left heart failure or deep vein thrombosis.

The resting EKG recorded a normal sinus rhythm at 80 bpm with no repolarization or conduction abnormalities.

## Investigations Found

First rate of cardiac markers at 1071 ng 3 hours later at 1272 ng, Positive inflammatory response (VS =100. CRP at 8) no significant findings among the rest (blood count: WBC: 8100, HB: 14, PLT: 336, Urea: 0.69, creat: 11, TP: 70%); negative Covid19 PCR test.

Echocardiogram exam: severe hypokinesia of basal segments of the inferior, infero septal, infero lateral walls, systolic function estimated at 48%, small pericardial effusion was also detected.

Coronary angiography done within 24h, found a thrombotic heterogeneous lesion on the middle Left anterior descending artery (LAD), TIMI flow 3 (Figure 2).

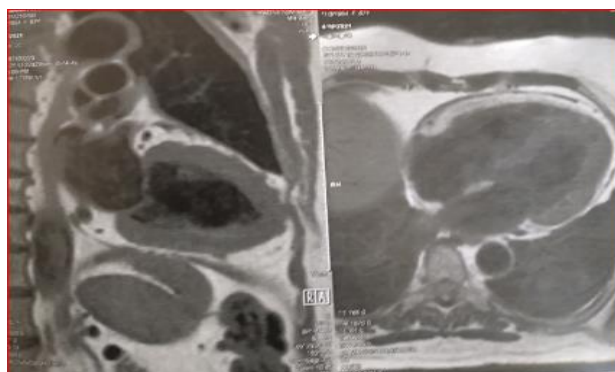
Cardiac MRI after 72h found: hypokinesia of the lateral and inferior walls basal segments, with sub epicardial late gadolinium enhancement (Non ischemic pattern), pericardial effusion regarding the lateral wall, compatible with perimyocarditis (Figure 1).

The association of non-elevated ST segment myocardial infarction and acute myocarditis has been retained as the main diagnosis.

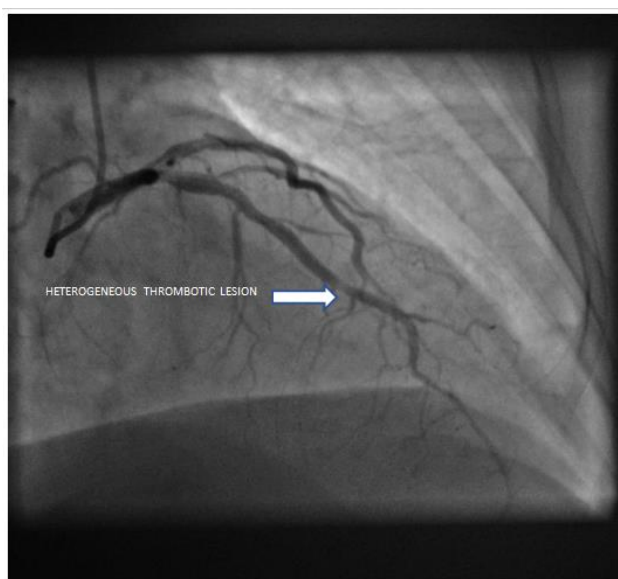
The patient was put under medical treatment that includes: Beta blockers, double anti platelets aggregation therapy, ARB and colchicine.

Evolution was favorable; echocardiogram control was done 3 months later found an ejection

fraction at 62%.



**Figure 1 : Cardiac MRI**



**Figure 2: Coronary Angiographic**

## DISCUSSION

According to statistics, before the emergence of COVID19 acute myocarditis represented only 0.1% of side effects post vaccination between 1998 and 2019 [1].

Since the global marketing of anti Covid-19 vaccines, more cases have been reported, to be precise 23 cases of acute myocarditis have been identified among US military members with an estimated incidence of 8.2 cases per 100000, 04 days after receiving mRNA based anti COVID 19 vaccine (7 Pfizer and 16 Moderna).

All patients were males, 22 currently serving in the military and 01 retiree, median age was 25 (20-51 years).

20 of 23 cases have been observed after the second dose, for the other 3 cases, they have tested positive for covid19 one to two months prior to the injection 17% of cases demonstrated reduced left

ventricular ejection fractions, no death was recorded in this case series [3].

In addition to this, in Israel, 54 cases of acute myocarditis have been reported among patients who have received at least one dose of mRNA vaccine.

The estimated incidence per 100,000 persons was 2.13 cases; the highest incidence of myocarditis was reported in male patients between the ages of 16 and 29 years.

Myocarditis risk in the 42 days following vaccination was multiplied by 3.24 compared to non-vaccinated.

In this case series 02 deaths have been recorded, the first after a resistant cardiogenic choc, no cause was determined for the second one [5]. Immunological mechanism is highly incriminated [4].

Until this very hour, the management is still similar to a non covid related myocarditis, corticoids and immunoglobulin have been proposed for fulminate myocarditis with a significant systemic inflammatory response [2].

## CONCLUSION

Anti covid vaccination is currently playing a huge role in reducing both mortality and morbidity among covid cases, nevertheless the role of doctors is even bigger in preventing and detecting undesirable effects to provide the best possible treatment.

## REFERENCES

1. Verma, A. K., Lavine, K. J., & Lin, C. Y. (2021). Myocarditis after Covid-19 mRNA vaccination. *New England Journal of Medicine*, 385(14), 1332-1334.
2. Das, B. B., Kohli, U., Ramachandran, P., Nguyen, H. H., Greil, G., Hussain, T., ... & Khan, D. (2021). Myopericarditis after messenger RNA coronavirus disease 2019 vaccination in adolescents 12 to 18 years of age. *The Journal of Pediatrics*, 238, 26-32.
3. Biykem Bozkurt, M. P., Ishan Kamat, M., Peter J., & Hotez, M. P. (August 10, 2021). *Circulation*, 471-482.
4. Guy Witberg, M. N. (October 6, 2021). Myocarditis after Covid-19 Vaccination. *The new england journal of medicine*, 1-8.
5. Kim, H. W., Jenista, E. R., Wendell, D. C., Azevedo, C. F., Campbell, M. J., Darty, S. N., ... & Kim, R. J. (2021). Patients with acute myocarditis following mRNA COVID-19 vaccination. *JAMA cardiology*, 6(10), 1196-1201.