

Inhabituel Localisation of Ewing Sarcoma: Case Report

Essaber Hatim^{1*}, Allali Nazik¹, Chat Latifa¹, El Haddad Siham¹

¹Radiology Department of Mother and Child, CHU Ibn Sina, University Mohammed V Souissi, Rabat, Morocco

DOI: [10.36347/sjmcr.2022.v10i03.014](https://doi.org/10.36347/sjmcr.2022.v10i03.014)

| Received: 06.02.2022 | Accepted: 11.03.2022 | Published: 14.03.2022

*Corresponding author: Essaber Hatim

Radiology Department of Mother and Child, CHU Ibn Sina, University Mohammed V Souissi, Rabat, Morocco

Abstract

Case Report

The mandible is an unusual localisation of the Ewing sarcoma, Only 1% of cases are reported with mandibular involvement. This case report aims to make clinicians, especially dentists aware of the neoplastic origin of rapidly enlarging intraoral or extraoral swellings that can simulate an odontogenic infection, for adequate and early management.

Keywords: Ewing sarcoma, mandibular involvement, neoplastic origin.

Copyright © 2022 The Author(s): This is an open-access article distributed under the terms of the Creative Commons Attribution **4.0 International License (CC BY-NC 4.0)** which permits unrestricted use, distribution, and reproduction in any medium for non-commercial use provided the original author and source are credited.

OBSERVATION

An 11-year-old male child presented to the department of oral medicine and with a rapidly enlarging swelling on right lower jaw since one month with pain and without fever. There was no history of trauma. Also, his past dental/medical history was unremarkable.

The extraoral examination revealed facial asymmetry due to a diffuse swelling on the right side of

the face, there was no clinical extension to infraorbital margin superiorly, neither ear lobule lifting laterally, this swelling has soft consistency and measure approximately 6×5 cm in its greatest dimensions, the skin over the swelling appeared to be normal without local rise in temperature. No discontinuity was noted in the lower border of the mandible. Lymph node examination revealed solitary, enlarged, unilateral, right submandibular lymph node (Figure 1 and 2).

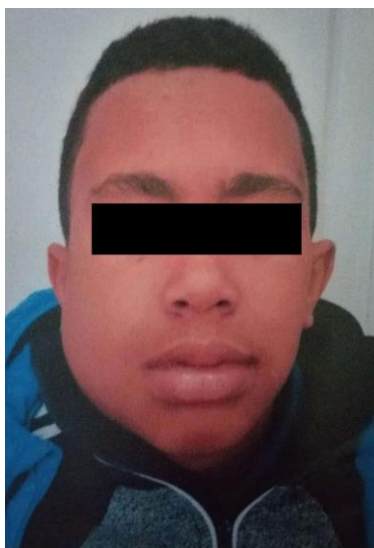

Figure 1: Pictures of the child

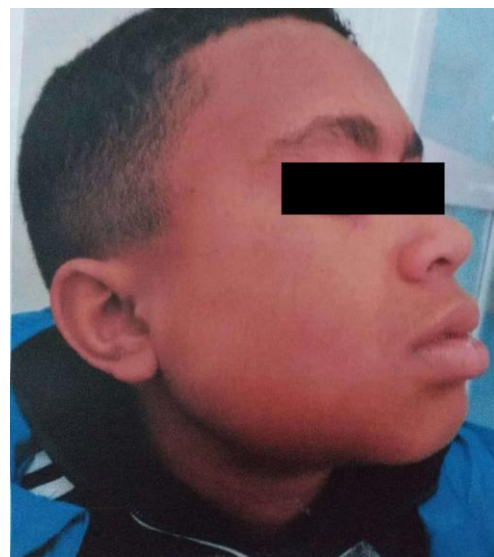

Figure 2: Pictures of the child

Computer tomography was performed showing moth-eaten, destructive, and permeative lucent lesion with soft tissue invasion and typical skin periostitis (Figure 3 and 4).

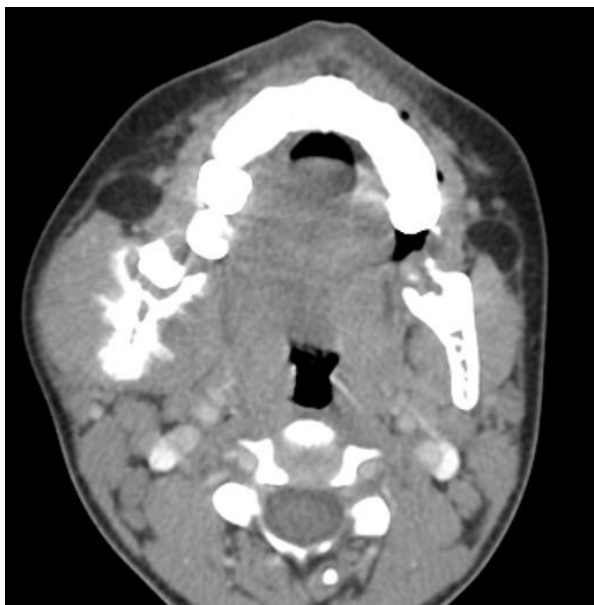

Figure 3: CT scan images on soft tissue and bone windows showing a moth-eaten, destructive, and permeative lucent lesion with soft tissue invasion and typical skin periostitis

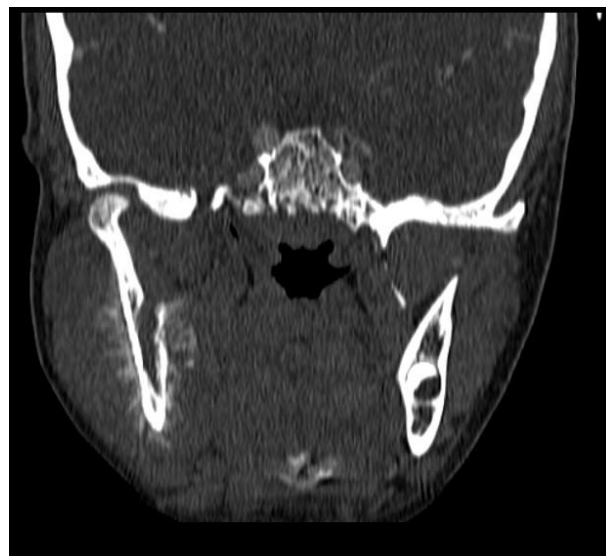

Figure 4: CT scan images on soft tissue and bone windows showing a moth-eaten, destructive, and permeative lucent lesion with soft tissue invasion and typical skin periostitis

To look for another infraclinical localisations, a bone scintigraphy was released and it demonstrate a solitary hyper fixation on the right side of the mandible (Figure 5).

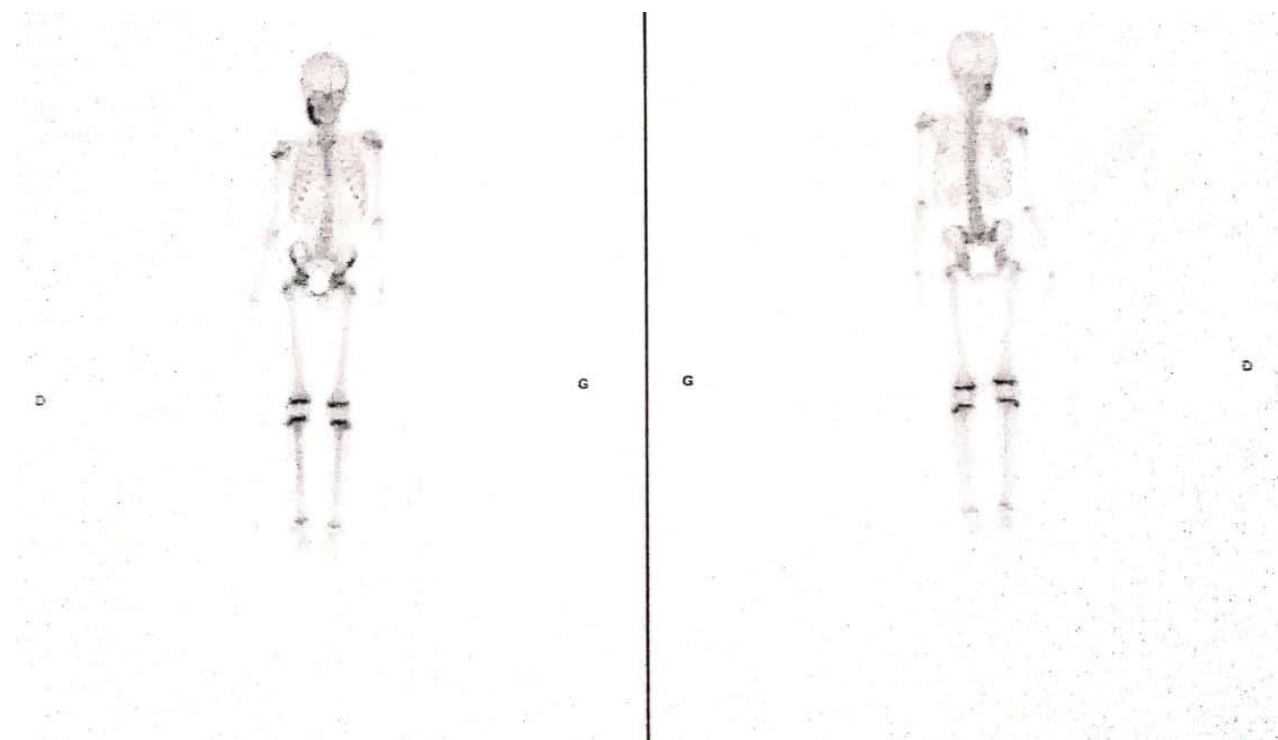


Figure 5: Bone scintigraphy demonstrating a solitary hyper fixation on the right side of the mandible

Confirmatory diagnosis of Ewing's sarcoma was made after histopathological evaluation of biopsy specimens. "The features observed during microscopic examination were sheets of uniform small round cells arranged in diffuse pattern with indistinct outline,

scanty cytoplasm, well-defined nuclear outline with round-to-oval nucleus, and inconspicuous nucleoli. Mitotic figures were not prominent" (Figure 6 and 7).

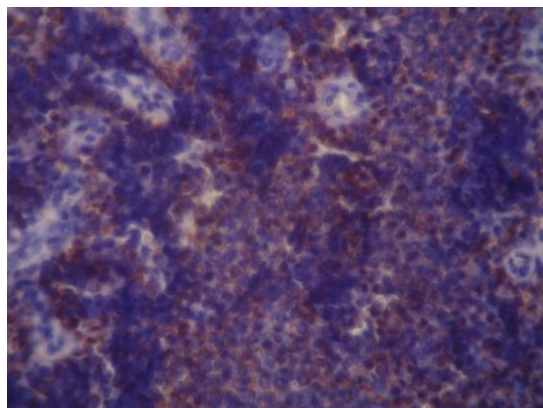


Figure 6: Microscopic images of the right mandible (x20 and x40) showing a uniform small round cells arranged in diffuse pattern with round to oval nucleus and mitotic figures

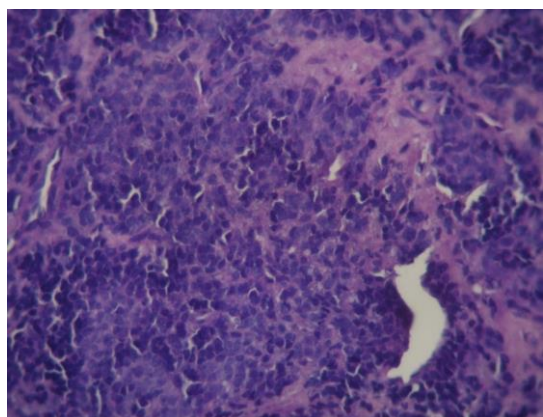


Figure 7: Microscopic images of the right mandible (x20 and x40) showing a uniform small round cells arranged in diffuse pattern with round to oval nucleus and mitotic figures

After the histological confirmation, our patient started chemotherapy immediately followed by tumor complete resection with no postoperative complications.

There was no local relapse neither oral infection on the two years of follow up (Figure 8).

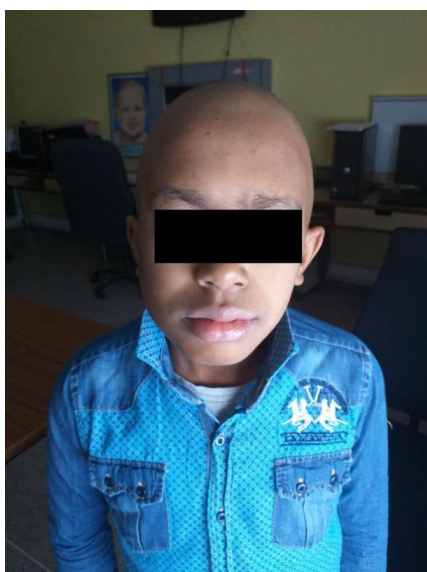

Figure 8: Picture of the child taken during the follow up

The patient now is closely followed in the paediatrics' oncology department to detect any local relapse, or oral infection.

DISCUSSION

Ewing's sarcoma (ES) was first described by James Ewing in 1920 as a diffuse endothelioma of bone [1]. It is the second most common malignant primary bone tumors of childhood after osteosarcoma [2].

Ewing's sarcoma (ES) is an uncommon round cell tumor with an aggressive course affecting mainly children and young adults. Radiographic finding in ES reflect many destructive nature of the lesion, like osteolysis, cortical erosion, periostitis and soft tissue mass. A case of ES of the mandible is reported with special consideration to the radiological appearance.

Ewing sarcoma, typically arising from the medullary cavity and presented as of long bones, with a large soft tissue invasion and typical onion skin periostitis. It can also involve flat bones and can appear sclerotic in up to 30% of cases.

Among jaw bones, mandible is more commonly affected than the maxilla, with an incidence from 1% to 10% [3].

Dentists should keep in mind bone tumors etiology and radiographs should be exposed routinely in such cases, especially when signs and / or symptoms are present and evaluating silently in more than one month.

In our case reported, the diagnosis of ES of the mandible have been made during the patient's initial consultation, and the patient has been diagnosed with bone tumor according to radiological features of the CT scan.

A site biopsy is the most important aspect in evaluating ES because of the lack of adequate tissue that can easily have led to misdiagnosis.

Chemotherapy with local control therapy should be the mainstay for primary Ewing's sarcoma treatment [4].

NCCN Clinical Practice Guidelines in Oncology for bone cancers 2018 [5], suggests that adjuvant radiotherapy can be indicated for three type of patients: in those with microscopic positive Margins after histology, in patients who need functional preservation (Head and neck region) and unresectable tumors (spine, vertebrae, weight bearing bones) [6]. But Radiotherapy generally should be avoided in pediatric patients because of induction of secondary cancers at radiated site Contemporary reconstruction of surgical defect subsequent is so important to restore an excellent functional and esthetic unit.

RÉFÉRENCES

1. Vidya, M., & Shetty, N. (2008). Ewing's Sarcoma Of The Mandible In 11 Year Old Female. s.l. *Internet J Pathol*, 8(1), 1–4.
2. Deore, S., Dandekar, R., Mahajan, A., & Pattar, P. (2015). Ewing's sarcoma of mandible: A case report presenting as odontogenic infection. *Journal of Oral and Maxillofacial Surgery, Medicine, and Pathology*, 27(5), 741-745.
3. Ko, E., Brouns, E. R., Korones, D. N., Pochal, W. F., Philipone, E. M., Zegarelli, D. J., & Yoon, A. J. (2013). Primary Ewing sarcoma of the anterior mandible localized to the midline. *Oral Surgery, Oral Medicine, Oral Pathology and Oral Radiology*, 115(6), e46-e50.
4. Chatzistefanou, I., Kabesi, S., Paraskevopoulos, K., Kolioukas, D., & Antoniadis, K. (2016). Ewing's sarcoma of mandible: an impressive case of spontaneous mandible regeneration. *International Journal of Clinical Pediatric Dentistry*, 9(3), 273-277.
5. NCCN Guidelines Version 1. Panel Members Bone Cancer. 2018.
6. Choi, Y., Do Hoon Lim, S. H. L., Lyu, C. J., Im, J. H., Lee, Y. H., & Suh, C. O. (2015). Role of radiotherapy in the multimodal treatment of Ewing sarcoma family tumors. *Cancer Research and Treatment: Official Journal of Korean Cancer Association*, 47(4), 904-912.