

Tracheopathia Osteoplastica: Rare Etiology of Hemoptysis

Hasna Jabri¹, Asmaa Fahmi^{1*}, Hajar Arfaoui¹, Wiam Elkhatabi¹, Hicham Afif¹

¹Pneumology Professor, Hospital 20 Aout, 6 Rue Lahcen Al Aarjoune, Casablanca 20250, Morocco

DOI: [10.36347/sasjm.2022.v08i03.016](https://doi.org/10.36347/sasjm.2022.v08i03.016)

| Received: 13.02.2022 | Accepted: 18.03.2022 | Published: 23.03.2022

*Corresponding author: Asmaa Fahmi

Pneumology Professor, Hospital 20 Aout, 6 Rue Lahcen Al Aarjoune, Casablanca 20250, Morocco

Abstract

Case Report

Tracheopathia osteoplastica, also called tracheobronchopathia osteochondroplastica (TBOP), is a rare and benign disease of unknown etiology and pathophysiology. Characterized by the formation of multiple cartilage or bone nodules in the submucosal layer of the trachea or large bronchi. We report an observation of a 41-year-old patient who consulted for the recurrence of low abundance hemoptysis evolving for 4 years. The clinical examination noted wheezing and sibilant rattles diffused during auscultation. The diagnosis of tracheopathiaosteoplastica was raised in view of the radiological imaging data and the characteristic endoscopic aspect. Treatment is most often symptomatic.

Keywords: Tracheopathia osteoplastica, Rare disease, wheezing.

Copyright © 2022 The Author(s): This is an open-access article distributed under the terms of the Creative Commons Attribution 4.0 International License (CC BY-NC 4.0) which permits unrestricted use, distribution, and reproduction in any medium for non-commercial use provided the original author and source are credited.

CASE REPORT

It's about a 41 year old man, without toxic habits or recent tuberculosis contagion. He consulted in pulmonology department because of the recurrence of low abundance hemoptysis evolving for 4 years associated with episodic bronchial syndrome made of cough bringing back mucopurulent sputum and wheezing without chest pain evolving in a context of apyrexia and preservation of the general state. The interrogation did not find any syndrome of penetration or area of atopy, he was not known to be chronic dyspneic and had no history of infectious pulmonary pathology. The pulmonary auscultation had perceived, in addition to the wheezing, a discreet snoring rales basal at the left basal level. The chest x-ray showed some hilar projection clarities associated with chest distension (Figure 1). Thoracic computed tomography objectified irregular horseshoe calcifications of the anterolateral walls of the trachea and the initial parts of the two main bronchi, associated with nodules protruding into the tracheal lumen thus reducing its lumen (Figure 2). This aspect is pathognomonic of tracheopathia osteoplastica.

Due to the episode of average abundance hemoptysis, a flexible bronchoscopy was necessary to

allow to exclude the differential diagnoses in particular a tracheal tumor; which was the main initial differential diagnosis considered; a foreign body, tracheal amyloidosis, tuberculosis or tracheal involvement in the context of a system disease (sarcoidosis, scleroderma, etc.). It objectified the presence of multiple hard whitish nodulations protruding in the tracheal lumen which was deformed, these nodules interested the anterior and lateral faces of the trachea, continuing on the two stem bronchi. The posterior surface was respected with the presence of purulent and bloody secretions (Figure 3). The biopsies were difficult to perform due to the hardness of the formations. The microbiological study of the bronchial suction fluid had not isolated common germs or bacillus of koch in direct examination and in culture.

Rigid bronchoscopy was indicated for the purpose of performing biopsies but refused by the patient. The diagnosis of tracheopathiaosteoplastica was retained. Exploration of the respiratory function outside the infectious episode showed a moderate non-reversible obstructive ventilatory disorder after the administration of beta 2 mimetics. The patient had received symptomatic treatment, with good clinical progress.

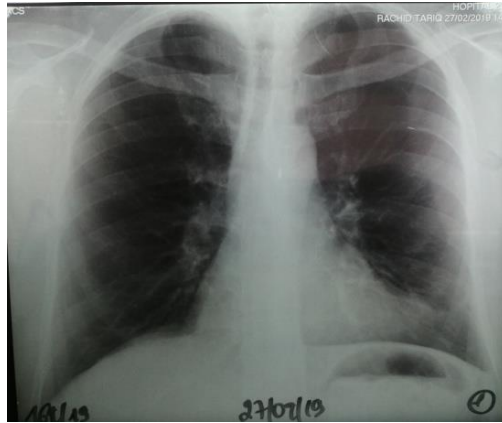


Figure 1: Chest x-ray face: thoracic distension

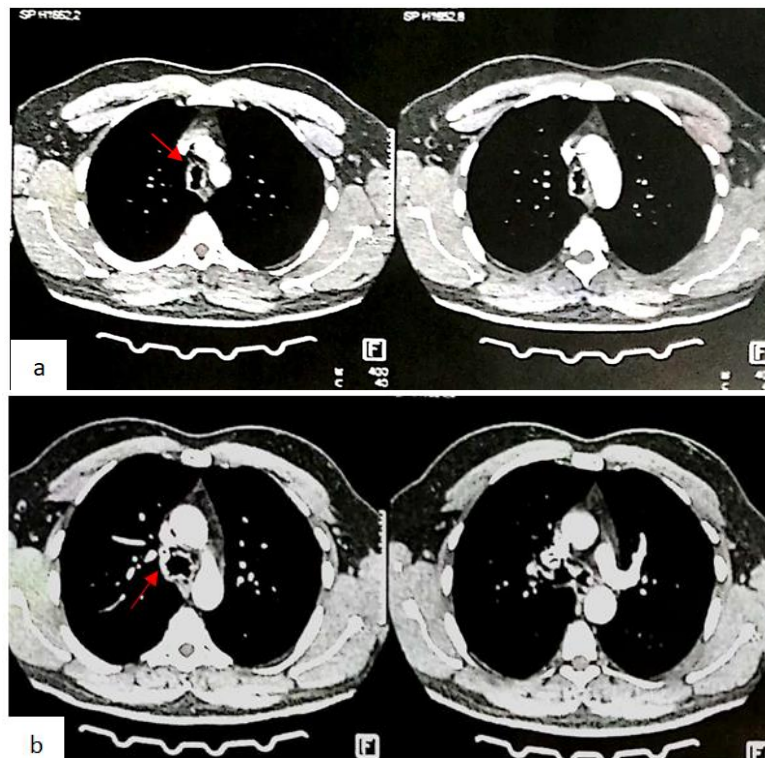


Figure 2: Thoracic computed tomography: a) irregular horseshoe calcifications respecting the posterior tracheal wall. b) nodules protruding into the tracheal lumen and main bronchi

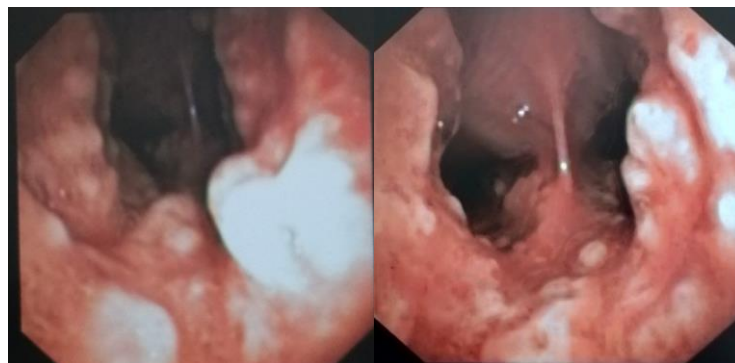


Figure 3: Bronchial endoscopic aspect. Irregular mucosa / Bulky cartilage bulges endotracheal

DISCUSSION

Tracheopathia osteoplastica, also called tracheobronchopathia osteochondroplastica (TBOP), is

a rare and benign condition [1, 2], of unknown etiopathogenesis. Several theories have been advanced to explain this affection, but two of them currently seem

more convincing: the tumor theory of Virchow in 1869 and the metaplastic theory of Aschoff in 1910 [3, 4]. Its incidence is estimated between 2 to 7 cases per 1000 inhabitants in patients who have undergone a systematic bronchoscopy for respiratory symptomatology. According to Secrest and al, it is estimated that only 51% of cases will be diagnosed [5]. The interval between the first symptoms and the diagnosis is around 4 years in 45% of cases; though, it can be longer than 25 years [5]. It mainly affects the elderly during the fifth decade and has a male predilection. However, there are few cases of TO affecting children [6]. Our patient was 41 years old.

The telltale signs are varied and non-specific [7]. They are often bronchopulmonary (85%) such as bronchial irritation syndrome, chronic bronchopneumopathy, cough, dyspnea, dysphonia, wheezing, hemoptysis [7, 8]. Asthma can sometimes reveal this condition [9]. In the absence of symptoms, its discovery remains fortuitous during an endoscopy, a chest scanner [7], an autopsy or difficult intubation [7, 8]. Functional respiratory tests find respiratory failure with obstructive syndrome in 40% of the cases [7].

Radiological abnormalities are easily overlooked on a standard chest X-ray which can be normal, especially in asymptomatic forms. The thoracic CT scan is of great diagnostic interest, revealing nodular densities calcified in rings involving the anterolateral walls of the trachea most often respecting the posterior wall and extending to the large bronchi [1]. The light is thus of reduced caliber with scalloped walls, bristling with endoluminal projections sometimes calcified [10]. This aspect is almost pathognomonic. The length of the affected trachea is on average 7.1 cm + / - 3.5 cm [7].

Endoscopy confirms the diagnosis, showing an almost specific aspect; rigid anterolateral walls, irregular due to the deformation of the mucosa by whitish nodules of 1 to 3mm, more or less confluent in plates reducing the caliber of the tracheal light. The mucosa is pale, atrophic but never ulcerated. Biopsy does not result in spotting, unlike amyloidosis which infiltrates the vessels [7]. This rigidity is perceived by the bronchoscope as a tactile sensation of screeching, making sampling difficult and often not very helpful. It is therefore necessary to resort to a rigid bronchoscope, offering the possibility of large biopsy taken when one absolutely wants histological confirmation [7, 8]. However, the latter is not necessary to retain the diagnosis of TO [2, 8].

These various aspects make it possible to eliminate other diseases of similar appearance such as tuberculosis, sarcoidosis, amyloidosis, recurrent polychondritis, tracheobronchial papillomatosis, a neoplastic process or physiological calcifications linked to age.

The histology reveals subepithelial osteocartilaginous foci without connection to the normal cartilage structures of the wall. The respiratory epithelium is the site of inflammation with a lymphoplasmacytic infiltrate. Hematopoiesis can be observed between the bone spans [8]. Coloring in Congo red with the search for green birefringence on polarized light eliminates amyloidosis [7].

Overall, this condition is not very progressive. The prognosis is generally linked to the degree of spread of the disease. It is dominated mainly by infectious, mechanical and more rarely hemorrhagic complications.

The etiological factors remain obscure, among the most incriminated are the association of a chronic pathology of the upper airways (such as ozene), chronic inflammation of the respiratory tract, the role of an endocrine factor, dermatomyositis [1, 8]. Some authors believe that tracheopathia osteoplastica is the final evolution of tracheobronchial amyloidosis.

There is no consensus for the treatment which is most often symptomatic and uses mucolytics, humidifiers, inhaled corticosteroids and antibiotics, the use of which can be preventive against bronchitis with positive bacteriology. In severe forms, endoscopy allows laser ablation of the nodules, the indication of a tracheobronchial stent can be put. Radiotherapy is of limited indication [5, 7].

CONCLUSION

In conclusion, tracheopathia osteoplastica is a rare idiopathic disease. Its origin is still unclear. The discovery is most often fortuitous. The evolution is slow and it does not jeopardize the vital prognosis. Treatment is most often symptomatic. Sometimes a therapeutic endoscopy or tracheostomy is possible in severe obstructive forms, thus improving the quality of life.

Conflict of Interest: No conflict of interest.

BIBLIOGRAPHY

1. De Wazières, B., Fest, T., Dalphin, J. C., Ranfaing, E., Capellier, G., & Dupond, J. L. (1994). Trachéopathie ostéochondroplastique associée à une dermatomyosite: à propos d'un cas. *La Revue de médecine interne*, 15(2), 121-123.
2. Leske, V., Lazor, R., Coetmeur, D., Crestani, B., Chatte, G., & Cordier, J. F. (2001). Tracheobronchopathia osteochondroplastica: a study of 41 patients. *Medicine*, 80(6), 378-390.
3. Jabbarjarjani, H. R., Radpey, B., Kharabian, S., & Masjedi, M. R. (2008). Tracheobronchopathia osteochondroplastica: presentation of ten cases and review of the literature. *Lung*, 186(5), 293-297.
4. Fois, A. G., Arcadu, A., Santoru, L., Trisolini, R., Marras, V., Ginesu, G. C., ... & Pirina, P. (2016).

- Tracheobronchopathia Osteochondroplastica: a rare case report of a non-smoker and non-atopic patient, with a long history of wheezing since childhood. *Multidisciplinary Respiratory Medicine*, 11(1), 1-5.
5. Saint-Blancard, P., Natali, F., Vaylet, F., Coutant, G., L'Her, P., & Le Vagueresse, R. (1997). Trachéobronchopathie ostéocondroplastique: cinq observations. *La Revue de médecine interne*, 18(11), 882-887.
 6. Jabri, H., Aichane, A., Afif, H., & Bouayad, Z. (2014). Trachéopathie ossifiante: diagnostic différentiel de l'asthme. *Revue Française d'Allergologie*, 54(2), 78-81.
 7. Devaraja, K., Sagar, P., & Chirom, A. S. (2017). Tracheobronchopathia osteochondroplastica: awareness is the key for diagnosis and management. *Case Reports*, 2017, bcr-2017.
 8. Nielsen, S. W., Stevens, J. R., Dion, G. R., & Howard, N. S. (2015). Dyspnea, dysphonia, and cough: varied presentations of tracheobronchopathia osteochondroplastica. *Annals of Otology, Rhinology & Laryngology*, 124(10), 829-833.
 9. Masson, E. (2021). Une cause inhabituelle de rétrécissement trachéal: diagnostic et prise en charge? EM-Consulte. <https://www.em-consulte.com/article/748789/impression/vue6>. Accessed 3 February 2021.
 10. Liétin, B., Vellin, J. F., Bivahagumye, L., Aumaître, O., Kemeny, J. L., Mom, T., & Gilain, L. (2008, July). Tracheopathia osteoplastica. In *Annales d'oto-laryngologie et de chirurgie cervico faciale: bulletin de la Société d'oto-laryngologie des hôpitaux de Paris* (Vol. 125, No. 4, pp. 208-212).