

Right Atrial Thrombus in Transit Complicated by Pulmonary Thromboembolism

Nagi S. Maglad¹, Elmutaz H. Taha², Ebtihal M. Osman³, Makawi. A. A. Osman^{2*}

¹Department of Internal Medicine, Faculty of Medicine, University of Dongola, Dongola, Sudan

²Department of Physiology, Faculty of Medicine, University of Dongola, Dongola, Sudan

³Dongola Specialized Teaching Hospital, Dongola, Sudan

DOI: [10.36347/sjmcr.2022.v10i03.018](https://doi.org/10.36347/sjmcr.2022.v10i03.018)

| Received: 30.01.2022 | Accepted: 05.03.2022 | Published: 25.03.2022

*Corresponding author: Makawi. A. A. Osman

Department of Physiology, Faculty of Medicine, University of Dongola, Dongola, Sudan

Abstract

Case Report

Echocardiography is one of a valuable and important tools which help in the diagnosis of right atrial thrombus in transit. Early diagnosis will help in early initiation of treatment and better outcome and prognosis. We present a case of right atrial thrombus in transit diagnosed by Transthoracic Echocardiography and treated with anticoagulant which gave a good result and the patient was completely recovered.

Key word: Right atrium, Thrombus, anticoagulant.

Copyright © 2022 The Author(s): This is an open-access article distributed under the terms of the Creative Commons Attribution 4.0 International License (CC BY-NC 4.0) which permits unrestricted use, distribution, and reproduction in any medium for non-commercial use provided the original author and source are credited.

1- BACKGROUND

Echocardiography representing corner stone for diagnosis of right atrial thrombus in current future. Right atrial thrombi in transit originated mainly from deep venous thrombus. They have been found that 4% of patients with pulmonary embolism had right atrial thrombi. or from right atrial (in situ), specially if the patient has atrial fibrillation. An other type of right atrial thrombi which is very rare resembling cardiac myxomas [1]. Right atrial thrombi in transit originating mainly from deep venous thrombosis, and represent 4% of patient suffering from Pulmonary embolism [1]. There are several types of treatment as thrombolysis, anticoagulant therapy, catheterbased treatment, and surgery.

2- CASE REPORT

A 30 years old lady, housewife, with clear medical background, bed ridden for 3 weeks, because of injury, by a sharp object -to her left thigh. The wound was sutured, ten days after she get injured, she developed swelling of the whole thigh above her left knee, then she started to complain of shortness of breath and left sided chest pain, the pain was pleuritic in nature. When she presented, she was distressed and tachypnic, pulse of 135b/m, regular and of good volume. BP 130/70 Heart examination revealed loud second heart sound, chest examination revealed crackles over the left lower base of the lung. Local

examination of her injured left thigh, revealed a scar of 10cm long, and tender swelling above knee. Initial ECG showed sinus tachycardia and S2Q3T3, (figure-1) ,a feature of right ventricular strain. A diagnosis of pulmonary embolism (PE) was put in mind and laboratory work up was significant for deep venous thrombosis and urgent Transthoracic Echocardiography (TTE) was performed which revealed a large freely mobile, floating thrombus in the right atrium, moderately dilated right atrium and right ventricle, with septal flattening and increased right ventricular systolic pressure, with normal left ventricular systolic function, (Figure 2, Video 2).

The patient was taken to the ICU and anticoagulant therapy was initiated. Heparin 80mg S/C bid and Warfarin 5mg started simultaneously. Continuous monitoring of vital signs and daily INR assessment was performed. The next day after starting treatment, the patient improved a lot ,and TTE showed free right atrium from the thrombus (Figure 3, Video 3). The patient stayed in hospital for one week and discharged thereafter in good condition and advised to continue on warfarin for 6 months ,taking into consideration assessment of PT and INR every two weeks.




Fig-1: ECG showed sinus tachycardia and S2Q3T3

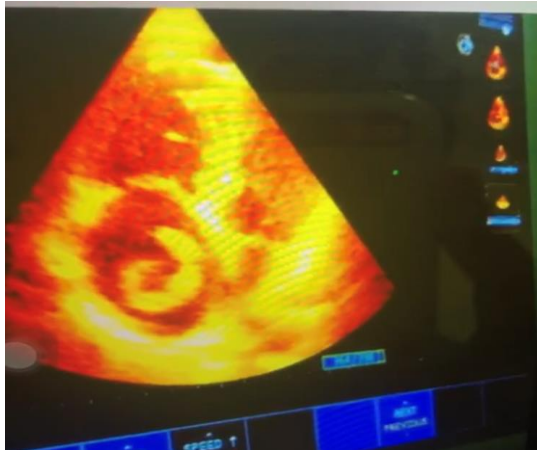

Fig-2: Apical four-chamber view showing a worm-like thrombus in the right atrium

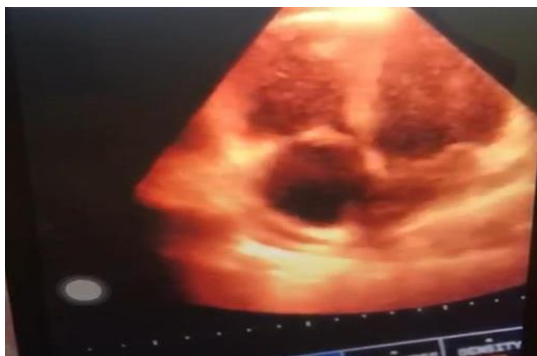

Fig-3: Apical four-chamber view showing free right atrium from the thrombus, 24hrs after starting treatment and also showing dilated right atrium and right ventricle

3- DISCUSSION

Right atrial thrombi in transit are the main cause of pulmonary embolism [2, 3] most of cases of present with increased heart rate, lower blood pressures, and right ventricular dysfunction in comparison to those who presented with pulmonary embolism without right heart thrombus [2]. Our patient was presented with shortness of breath, tachypnea and left sided pleuritic chest pain. These features are not much different from the presenting features of other cases. Unfortunately, right heart thrombi in transit has poor prognosis and its mortality rate has been reported to be about 45% [4]. One of the serious manifestations of the deep venous thrombosis appears in the form of right heart thrombus, which need vigorous and argent management plan since almost of deaths happen in the first 24h [5]. Treatment of the right heart thrombus in transit in different studies,

by thrombolytics or surgery are more efficient than anticoagulant alone [6]. In our case urgent transthorathic echocardiography has been performed, and immediately we gave the patient anticoagulant (Heparin and Warfarin) and the patient showed good response and she completely recovered.

4- CONCLUSION

Our patient who survived from acute sequel right atrial thrombus, had the option of medical treatment in the form of heparin and warfarin, and fortunately she recovered completely this scenario describes the importance of early diagnosis and early initiation of anticoagulant therapy.

5- RECOMMENDATION

Echocardiography should be done, not only, by cardiology team, but also by emergency and internal medicine house staff, for the early recognition of right atrial thrombus and its complications.

Conflict of interest

All authors declare that there is no conflict of interest

REFERENCES

1. Carson, J.L., Kelley, M.A., Duff, A. (1992). The clinical course of pulmonary embolism. *N Engl J Med*, 326; 1240–1245
2. Torbicki, A., Galié, N., Covezzoli, A., Rossi, E., De Rosa, M., Goldhaber, S. Z., & ICOPER Study Group. (2003). Right heart thrombi in pulmonary embolism: results from the International Cooperative Pulmonary Embolism Registry. *Journal of the American College of Cardiology*, 41(12), 2245-2251.
3. Casazza, F., Bongarzone, A., Centonze, F., & Morpurgo, M. (1997). Prevalence and prognostic significance of right-sided cardiac mobile thrombi in acute massive pulmonary embolism. *The American journal of cardiology*, 79(10), 1433-1435.
4. Chartier, L., Béra, J., Delomez, M., Asseman, P., Beregi, J. P., Bauchart, J. J., ... & Théry, C. (1999). Free-floating thrombi in the right heart: diagnosis, management, and prognostic indexes in 38 consecutive patients. *Circulation*, 99(21), 2779-2783.
5. Chapoutot, L., Nazeyrollas, P., Metz, D., Maes, D., Maillier, B., Jennesseaux, C., & Elaerts, J. (1996). Floating right heart thrombi and pulmonary embolism: diagnosis, outcome and therapeutic management. *Cardiology*, 87(2), 169-174.
6. Rose, P. S., Punjabi, N. M., & Pearse, D. B. (2002). Treatment of right heart thromboemboli. *Chest*, 121(3), 806-814.