

Management of Intra-Abdominal Hydatid Disease: A Surgical Experience in a Single Rural Hospital

Dr. Aftab Ahmad Khan, MS^{1*} and Dr. Rakesh Kumar, MS²

¹Senior Consultant, Gen. Surgery, District Hospital Doda, Jammu and Kashmir, India

²Department of Gen. Surgery, District Hospital Doda, Jammu and Kashmir, India

*Corresponding author: Dr. Aftab Ahmad Khan

| Received: 24.05.2019 | Accepted: 30.05.2019 | Published: 11.06.2019

DOI: [10.21276/sasjs.2019.5.6.1](https://doi.org/10.21276/sasjs.2019.5.6.1)

Abstract

Original Research Article

Hydatid disease is an anthroponosis and is caused by *Echinococcus granulosus*. Humans are accidental intermediate hosts of *Echinococcus*. Liver is the most common involved organ (59-75%) followed by the lung (27%), Kidney (03%), bone, (1-4%) and brain (1-2%). Other sites. Such as spleen pancreas, heart and muscles are rarely affected, 16 cases of intra-abdominal hydatid disease were diagnosed and managed surgically in a single rural hospital. Male are affected more than females, ultrasonography is diagnostic and non-radical open surgery is the safe procedure in rural set up.

Key words: Hydatid, Intra-abdominal, *Echinococcus*

Copyright © 2019: This is an open-access article distributed under the terms of the Creative Commons Attribution license which permits unrestricted use, distribution, and reproduction in any medium for non-commercial use (NonCommercial, or CC-BY-NC) provided the original author and source are credited.

INTRODUCTION

Human hydatid disease or echinococcosis has a worldwide distribution and is endemic in many countries in the Mediterranean region, the middle and Far East, and South America [1]. The disease is endemic in a few rural areas of India and poses a diagnostic and surgical dilemma to the attending surgeon. It is caused by the larval stage of *Echinococcus granulosus*, a parasite of the order cestoda and family Taeniidae. Humans are the accidental dead-end intermediate hosts. Canine animals such as dog, wolf, fox and jackal are definitive hosts while pigs, Cattle, Horses and Goats are intermediate hosts. Incidental human infestation with larval form results in formation of hydatid cysts in various part of the body. The liver, lungs and spleen are the most commonly affected organs.

Sixteen Patients of intra-abdominal hydatid disease diagnosed and treated surgically in a single Rural Hospital were studied retrospectively with an aim to achieve best available diagnostic and surgical approach.

MATERIAL AND METHODS

Sixteen patients with intra-abdominal hydatid disease were treated surgically between 2008 and 2013. All the patients belonged to cattle rearing rural areas eleven were male and five were female. The age ranged between 15 to 72 years.

The most common complaints were pain abdomen and abdominal mass. Symptoms at clinical presentation are summarized in Table 1.

Tabel-1: Clinical Presentation

Presenting sign or symptom	Number of patients (%)
Abdominal pain	14 (87.5%)
Abdominal Mass	14 (87.5%)
Fever	02 (12.5%)
Weight Loss	02 (12.5%)

Besides hydatid serology, routine haematological and radiological investigations were performed in all the patients. Among hydatid serology, ELISA IgG was performed and was positive in 13 patients (81%).

Haematological investigations including LFTs of all the patients were found to be within normal limits. Plain X-Ray abdomen and ultrasonography was performed in all the 16 cases. Plain X-Ray abdomen

showed calcification and raised dome of diaphragm in one patient of hydatid liver (Fig.01).

Ultrasound abdomen revealed cystic lesions with internal echoes and Septations (Fig. 02) in various organs.

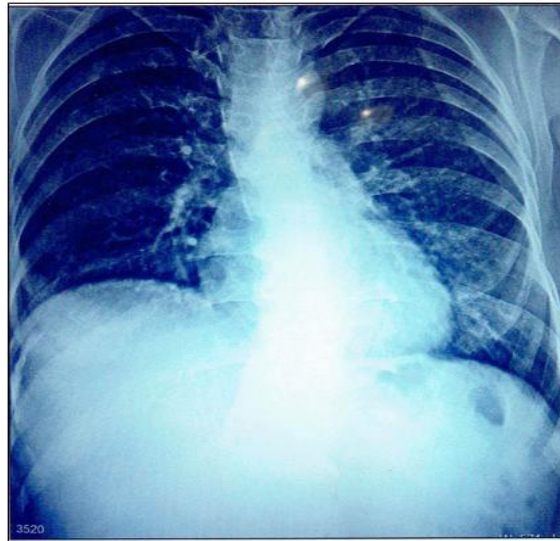


Fig-1: Plain X-Ray abdomen

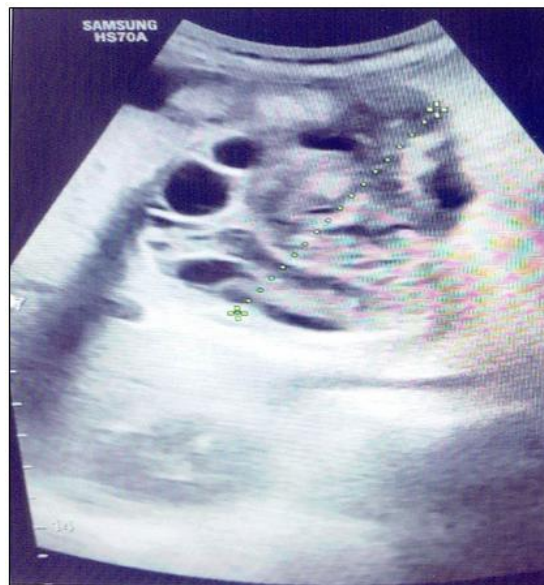

Fig-2: Ultrasound abdomen

Table-2: Distribution of cysts in various organs

Organs involved	No. of cases	(%)
Liver	12	(75.0%)
Mesentry	03	(18.75%)
Pelvis	01	(06.25%)

Computed tomography (CT abdomen) was not performed as it was not available in the Hospital. Prior

to surgery all the patients received Albendazole (10 mg/kg of body weight) for a period of one month.

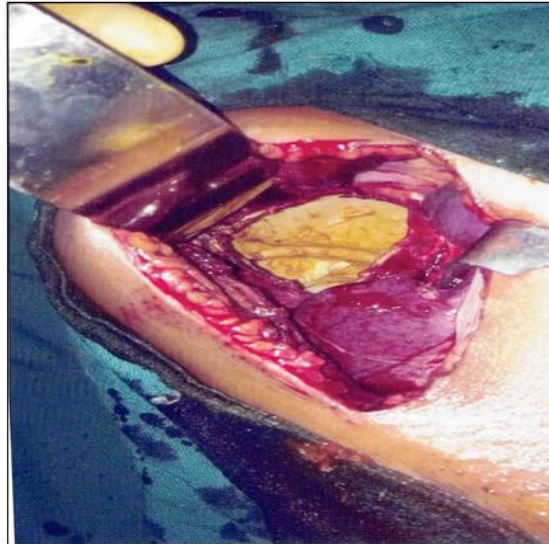


Fig-3: Residual cavity after removing hydatid

We use the scolical agent Povidine Iodine 10% for irrigating the cyst cavity. In case of hydatid liver, the cyst was isolated with guaze-soaked in 20% hypertonic saline solution, the cyst was punctured and hydatid fluid aspirated and same amount of Povidine Iodine (10%) injected into the cyst and kept for 10-15 minutes. Cysts were then deroofed by excising the projecting part of pericyst and evacuating the contents. The remaining cavity (Fig. 03) was again irrigated with the scolical agent who was sucked out after few minutes and cavity Fig. 03: Residual cavity after removing hydatid swept with the guaze to locate any contents from hydatid cyst liver biliary communication. In our study among the 12 cases (75%) of hydatid liver, omentoplasty was performed in 6 casees) 50%), capitonage was done in 4 cases (33.3%) while in 2 cases (16.6%) tube drainage was performed.

Biliary communication was noticed in one case per operatively which was sutured with vicryl 2-0 thread followed by omentoplasty of the cavity. The peritoneal cavity drain was kept in the subhepatic space by using a wide guaze rubber tube connected to a bag. The tubes were removed within 2 to 5 days in 10 cases (75%) where capitonage or omentoplasty was performed and in 2 cases (16.6%) tube was removed at the end of 2 weeks. In 1 case of biliary leak, the tube stayed longer and was removed at the end of 7 weeks. Cystectomy was performed in 04 cases having hydatid cyst in mesentry of gut and a single case of hydatid pelvis where in addition to cystectomy, right sided salpingoophrectomy was also performed. In a case of hydatid liver with cholelithiasis, cholecystectomy was performed in the same sitting beside capitonage of the cyst cavity.

RESULTS

All the patients in our study hailed from rural areas having close contact with livestock. Majority of our patients were between 15-72 years of age with a

mean age of 36 years. Both sexes were involved with male preponderance. Out of 16 patients 11 (68.75%) were males and five (31.25%) were female. Most of the patients came for surgical treatment with in three months of the onset of symptoms. However, a few patients had symptoms of over 03 years duration before coming for the treatment.

Most common symptom was mass abdomen with pain (Table-I) Two patients presented with history of fever and weight loss in addition to pain abdomen. The different organs involved by the hydatid cysts are shown in Table-2. The most frequent site of the intra-abdominal cysts was liver (68.75%) where one or more than one cysts were present (Table-2). In our study among the twelve cases of hydatid liver, six patients had more than one cyst in the liver, 01 patient had cholelithiasis in addition. 03 patients had cysts in the small or large gut mesentry while in one patient the cysts was in the pelvis densely adherent to right ovary and fallopian tube Table-2.

In the beginning of our surgical experience hydatid cysts of liver in two patients got ruptured during the removal but were immediately sucked out. For hydatid cysts of mesentry, cystectomy was performed which includes resection and complete removal of pericyst. In a single case of hydatid pelvis, right sided salpingo-oopherectomy was performed in addition to the cystectomy.

Average stay of the patients in the hospital was for 9 to 10 days after surgery. Two patients (12.5%) who had infected cysts liver, stay was prolonged up to three weeks and had surgical site wound infection also. There was bile leak in one patient of hydatid liver having biliary communication. The bile leak closed spontaneously after a period of seven weeks. Patients were followed monthly till six months and then every three months for a period of 02 years.

DISCUSSION

Hydatid disease is still a problem in developing countries. Although the disease is often asymptomatic for many years owing to slow growths of the cyst, it poses a technical challenge to the attending surgeon due to involvement of a variety of organs [2, 3].

Among intra-abdominal organs liver is the commonest site for hydatid disease (59-75%) and this is due to rich filtration activity of the liver [4].

The next organs involved in order of frequency are lung (27%), kidney (3%), bone (1-4%) and brain (1-2%). Other sites such as spleen, pancreas, heart, omentum, ovaries, parametrium, pelvis, retroperitoneum and muscles are rarely affected [6].

Peritoneal hydatid disease, either primary or secondary represents an uncommon but significant manifestation of the disease (approximately 13%).

Intraperitoneal hydatid cysts are usually secondary to the rupture (spontaneous or accidental at surgery) of a primary hepatic, splenic or mesenteric cyst [5]. The solution to the hydatid disease, easier said than done, lies in the prevention by means of socio economics, public health and sanitary measures. But once the problems has occurred, surgery is the main stay of treatment [2].

In our study of 16 patients male (68.75%) were affected more than females (31.25%) and it is due to more outdoor involvement with livestock management. The mean age of the patient was 36 years.

All patients belonged to rural areas with close contact with the livestock. Humans are the accidental intermediate host in the development cycle of hydatid disease.

14 out of 16 patients presented with symptoms of pain abdomen with abdominal mass. The symptoms are due to massive enlargement of the involved organ or due to large cyst occupying the significant portion of the peritoneal cavity [6,7]. Two patients presented with history of fever and weight loss in addition to pain abdomen. This may be attributable to low intake of food due to early satiety caused by infected hydatid cyst of the liver.

Diagnosis was confirmed by imaging techniques. Beside X-Ray chest, plain X-ray abdomen and ultra-sonography was performed in all the patients. Plain X-ray film showed calcification and raised dome of diaphragm in one patient Fig (1) which is a suggestive finding of hydatid disease of liver. In our study main diagnostic tool was ultra-sonography, which demonstrated cystic lesions with internal echoes and septations in all the patients. Ultrasonography and

computed tomography are highly sensitive in the diagnosis of hydatid disease of the abdomen. Ahmet a Balik *et al.* in a series of 304 cases of hydatid liver revealed a sensitivity of 97.7% and 100% for ultra-sonography and computed tomography, respectively [8]. We are not able to discuss about the sensitivity of CT scan in our study as it was not available with us. Ultra-sonography provided 100% sensitivity in our study and was a road map for the operating surgeon to approach the cyst.

All the patients in our study received antihelminthic therapy for a period of three months. Albendazole (10mg/Kg body weight) commencing 1 month prior to surgery and was continued for two months in the post-operative period. Continuation of antihelminthic therapy post operatively is essential to prevent the recurrence of the disease [9]. Co-existent disease such as diabetes, hypertension and ischaemic heart disease add to the morbidity and mortality in hydatid disease [10]. In our study one patient had hypertension and had no per operative or post-operative complications. The mean follow up in our study was two years. However, one patient was lost to follow up. None of the patient had any recurrence of the disease in the follow-up period. Of the 16 patients, 12 had hydatid cyst in the liver, 6 had more than one cyst in the liver. The high frequency of liver involvement may be due to filtration functions of the liver where in the parasites are filtered off [4].

For surgical interventions, general condition of patient, organ involvement and characteristics of the cysts are important considerations. Large cysts involving solid organs in the peritoneal cavity demand prompt surgical intervention [12]. Small calcified cysts which are deep and difficult to approach may be managed conservatively [11, 12].

In intra-abdominal solid organs like liver and spleen cyst wall is critical to handle as it consists of compressed parenchymatous tissue admixed with rich vasculature. Therefore, in intra-abdominal solid organs peri cyst is not resected [13]. A non-radical approach is the best and safe approach and includes prevention of intra-operative contamination, neutralization with removal of parasite and management of the residual cavity [11-13]. The hydatid fluid in the cavity is highly antigenic and infective and therefore sterilization prior to surgery is mandatory. This is commonly achieved by using scolicidal agent such as 20% hypertonic saline, 0.5% silver nitrate, 0.5% cetrimide or 10% povidine solutions. The scolicidal solution is left in the cyst for about 15 minutes before opening the cyst, meticulous isolations of the cyst is done using dark colored towels soaked in 20% hypertonic saline solution. The cyst is punctured and hydatid fluid aspirated. Cysts are deroofed and the contents removed out avoiding the spillage. After complete evacuation of the daughter cysts and contents (Fig. 03) the cavity is swept with the

dry gauze for identification of any biliary leak. In case of a biliary communication, the scolical agent may enter into the biliary tract and predispose to sclerosing cholangitis. After identification, the biliary communication is closed with an under-running stitch.

Having evacuated and sterilized the cyst cavity, the dead space is obliterated. This can be done by omentoplasty[16] or capitonage[15]. In case of suppurative tube drainage or marsupialization is unavoidable [14]. In our study one patient had biliary communication that was closed by using 2-0 vicryl thread followed by omentoplasty of the dead space. Out of 12 cases of hydatid liver, omentoplasty was performed in 6 cases (50%) capitonage in 4 cases (33.3%) and tube drained in 2 cases (16.6%). Omentoplasty is advantageous because it allows macrophages to invade the area thereby enhancing phagocytosis of residual parasitic material [16]. It also helps in prevention of any reactive fluid collection in the empty cavity. However, a sub hepatic drain is mandatory to prevent fluid collection in a suddenly created dead space.

For hydatid cysts in the peritoneal cavity or omentum, complete cystectomy including the pericyst lining is performed [7]. The pericyst in peritoneal hydatid is extremely thin and not as vascular as seen in solid organs. In our study we performed cystectomy in 4 cases having hydatid cyst in the mesentery of gut and a single case of hydatid pelvis where right sided salpingo-oophorectomy was also performed. In case of mesenteric hydatid, there is a possibility of compromise of bowel blood supply and therefore in rare cases, a segmental resection of the bowel may be required[17]. The removal of omental hydatid is easier as compared to mesenteric hydatids.

Complications of hydatid disease may occur and include bleeding, anaphylaxis, surgical site wound infection, infection in the remaining cavity, cholangitis, biliary fistulas, septicemia and recurrence or residual disease [8]. Meticulous haemostasis is necessary in preventing haemorrhagic complication. In our study we kept a fresh blood transfusion ready during the surgery in all the patients. Surgical site wound infection was observed in two patients. It may be related to suppurative condition of the hydatid cyst where tube drainage was performed. In both patients the wound healed with regular dressings followed by secondary suturing of the cutaneous wound under local anaesthesia.

Post-operative bile leak leads to significant morbidity after surgical management of hydatid cyst of liver. But a majority of them resolve spontaneously [18].

One patient had biliary leak (<300ml/24hrs) and it closed spontaneously at the end of seven weeks.

In this patient, suture ligation of the cyst-biliary communication was performed followed by omentoplasty of the residual cavity. Probably stitch had given way or there may be another small biliary communication that closed spontaneously.

The mean follow up period in our study was 2 years _____. However one patient was lost to follow up. None of the patient had any recurrence or residual diseases in the period of follow up.

CONCLUSION

Male patients are involved more as compared to females due to their more outdoor activity especially with the livestock. Symptoms may vary from vague fullness to development of pain abdomen and mass. Ultra-sonography in a rural set up provides an excellent guide line for surgical management. Open surgical methods especially conservative/non-radical operation are safe and easy and require minimal hospital stay. A 12 week course of Albendazole is essential and effective for preventing recurrence.

REFERENCES

1. Eckert J, Gemmell MA, Matyas Z, Soulsby EJ, World Health Organization. Guidelines for surveillance, prevention and control of echinococcosis/hydatidosis. Geneva: World Health Organization. 1984.
2. Lewall DB. Hydatid disease: biology, pathology, imaging and classification. *Clinical radiology*. 1998 Dec 1;53(12):863-74.
3. Siracusano A, Teggi A, Ortona E. Human cystic echinococcosis: old problems and new perspectives. *Interdisciplinary perspectives on infectious diseases*. 2009;2009.
4. Langer JC, Rose DB, Keystone JS, Taylor BR, Langer BE. Diagnosis and management of hydatid disease of the liver. A 15-year North American experience. *Annals of surgery*. 1984 Apr;199(4):412.
5. Akther J, Khanam N, Rao S. Clinico epidemiological profile of hydatid diseases in central India, a retrospective and prospective study. *Int J Biol Med Res*. 2011;2(3):603-.
6. Stojkovic M, Rosenberger K, Kauczor HU, Junghans T, Hosch W. Diagnosing and staging of cystic echinococcosis: how do CT and MRI perform in comparison to ultrasound?. *PLoS neglected tropical diseases*. 2012 Oct 25;6(10):e1880.
7. Vagholkar KR, Nair SA, Rokade N. Disseminated intraabdominal hydatid disease. *Bombay Hospital Journal*. 2004;46(2):218-.
8. Balik AA, Başoğlu M, Çelebi F, Ören D, Polat KY, Atamanalp SS, Akçay MN. Surgical treatment of hydatid disease of the liver: review of 304 cases. *Archives of Surgery*. 1999 Feb 1;134(2):166-9.
9. Teggi A, Lastilla MG, De Rosa F. Therapy of human hydatid disease with mebendazole and

- albendazole. Antimicrobial agents and chemotherapy. 1993 Aug 1;37(8):1679-84.
10. Sözen S, Emir S, Tükenmez M, Topuz Ö. The results of surgical treatment for hepatic hydatid disease. *Hippokratia*. 2011 Oct;15(4):327.
 11. Smego Jr RA, Sebanego P. Treatment options for hepatic cystic echinococcosis. *International journal of infectious diseases*. 2005 Mar 1;9(2):69-76.
 12. McManus DP, Gray DJ, Zhang W, Yang Y. Diagnosis, treatment, and management of echinococcosis. *Bmj*. 2012 Jun 11;344:e3866.
 13. Vagholkar K, Pawanarkar A, Vagholkar S, Pathan S. Surgical management of hepatic hydatid disease. *Int J Res Med Sci*. 2016 Jun;4(6):1834-7.
 14. Sayek I, Yalin R, Sanaç Y. Surgical treatment of hydatid disease of the liver. *Archives of Surgery*. 1980 Jul 1;115(7):847-50.
 15. Romero-Torres R, Campbell JR. An interpretive review of the surgical treatment of hydatid disease. *Surgery, gynecology & obstetrics*. 1965 Oct;121(4):851.
 16. Papadimitriou J, Mandrekas A. The surgical treatment of hydatid disease of the liver. *British Journal of Surgery*. 1970 Jun;57(6):431-3.
 17. Vagholkar KR. Healing of anastomosis in the gastrointestinal tract (Prospective study of 35 cases). *Bombay Hospital Journal*. 2001;43(2):269-79.
 18. Agarwal S, Sikora SS, Kumar A, Saxena R, Kapoor VK. Bile leaks following surgery for hepatic hydatid disease. 2005.