

## Contrast Enhanced CT-Scan of Aorta Thrombosis in Neonates: Case Report

Adam Hajjine<sup>1\*</sup>, Mohamed Amine Nouri<sup>1</sup>, Badr Boutakioute<sup>1</sup>, Btissam Zouita<sup>1</sup>, Meriem Ouali Idrissi<sup>1</sup>, Najat Cherif Guennouni Idrissi<sup>1</sup>

<sup>1</sup>Radiology department of Mohamed VI University Hospital, Marrakech, Morocco

DOI: [10.36347/sjmcr.2022.v10i03.021](https://doi.org/10.36347/sjmcr.2022.v10i03.021)

| Received: 10.02.2022 | Accepted: 17.03.2022 | Published: 30.03.2022

\*Corresponding author: Adam Hajjine

Radiology department of Mohamed VI University Hospital, Marrakech, Morocco

### Abstract

### Case Report

Aortic thrombosis of the newborn is a rare condition associated with poor functional and vital prognosis. Most cases are related to umbilical arterial catheterization, but other risk factors include sepsis, extreme prematurity, asphyxia and prothrombotic conditions. We present a case of neonatal aortic thrombosis presenting with a lower limb ischemia occurring at the second week after birth in association with respiratory distress. Its imaging features are displayed along with a literature review. The Doppler ultrasonography made the initial diagnosis and Contrast Enhanced Computed Tomography provided precise location and extension of the thrombus. In Conclusion, Doppler Ultrasonography is first-line examination for diagnosis of aortic thrombosis in neonates. However, its lack of anatomic precision makes the Contrast Enhanced Computed tomography the imaging technique of choice in investigation of ischemia due to aortic thrombosis, as it provides the topography and extension of the thrombosis, also identifies the ischemic phenomena of abdominal organs and limbs.

**Keywords:** Aorta thrombosis, Neonate, Doppler Ultrasonography, Contrast Enhanced Computed Tomography.

**Copyright © 2022 The Author(s):** This is an open-access article distributed under the terms of the Creative Commons Attribution 4.0 International License (CC BY-NC 4.0) which permits unrestricted use, distribution, and reproduction in any medium for non-commercial use provided the original author and source are credited.

## INTRODUCTION

Aortic thrombosis of the newborn is a rare but potentially life-threatening condition associated with poor functional and vital prognosis as the overall mortality varies from 4 to 18%. Most cases are related to umbilical arterial catheterization, but other risk factors include sepsis, extreme prematurity, and asphyxia and prothrombotic conditions [1, 2].

The clinical presentation varies following the location and extent of the clot. The diagnosis is made primarily by Doppler ultra-sonography, completed by Computed Tomography, MRI angiography or contrast angiography for further characterization [3].

We present a case of neonatal aortic thrombosis presenting with a lower limb ischemia. Its imaging features are displayed along with a literature review.

## CASE REPORT

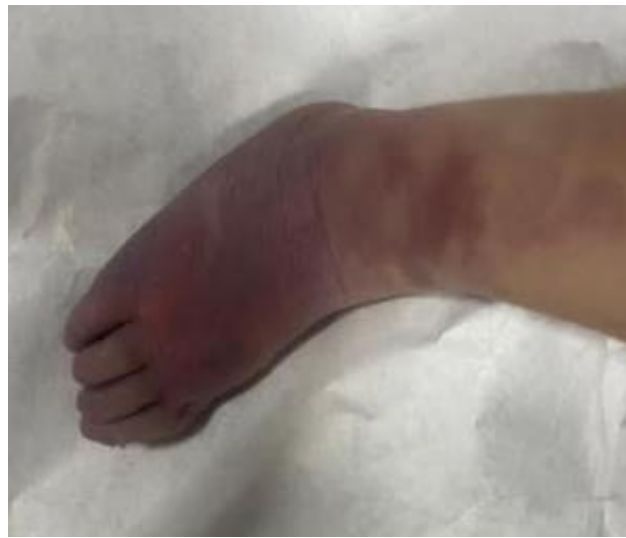The patient was a 2 weeks-old male of normal weight, born at home by vaginal delivery, at term from a gravida 5, para 5 healthy mothers. He developed a

respiratory distress associated to febrile seizures followed by an hemorrhagic syndrome including eyelid ecchymosis, purpura, subconjunctival hemorrhage, hematochezia and melena. On physical examination, the newborn had a fever at 39°C, a bradycardia at 96 bpm and a tachydyspnea. Otherwise, a right cold cyanotic foot with normal femoral pulse was found (Figure 1). Initial laboratory tests showed: polyglobulia (hematocrit= 65%), thrombocytopenia (21000), markedly elevated creatinine (52mg/L) and moderately increased C-reactive protein. The patient was referred to our department for lower limb cyanosis investigation. Abdominal ultrasound with Doppler revealed no flow through abdominal aorta. Contrast enhanced Computed Tomography showed thrombotic occlusion of the abdominal aorta from the origin of superior mesenteric artery extending to both common iliac arteries. Superior mesenteric arteries and renal arteries were occluded. Both kidneys were non perfused and edematous. Both common femoral arteries were collaterally perfused through epigastric arteries (Figure 2).

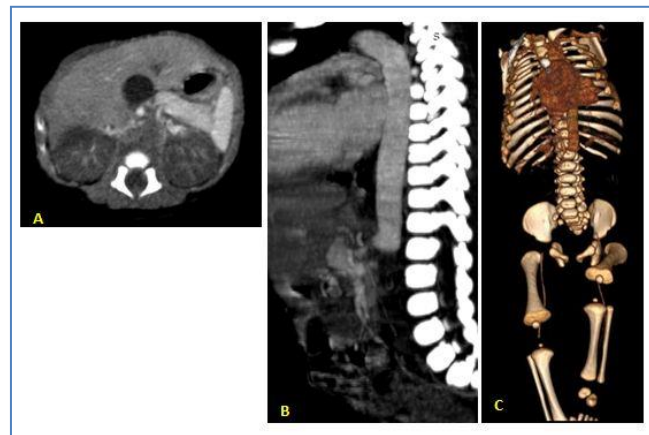
The hemorrhagic syndrome and thrombocytopenia prevented administration of a

systemic anticoagulation and the patient died 15 hours

after his admission.



**Fig-1:** Picture of the right foot showing cyanosis



**Fig-2:** Enhanced Computed Tomography: A. axial view revealing non opacified abdominal aorta with non perfused and edematous kidneys. B. Sagittal MIP view showing aortic thrombotic occlusion from origin of superior mesenteric artery till the common iliac arteries. C. Virtual Rendering Technique, in addition to location and extension of thrombus, exhibits perfusion of both femoral arteries.

## DISCUSSION

Symptomatic aortic thrombosis is a rare condition concerning 0, 1-1,1 per 100 000 live births [4]. They are mainly of iatrogenic origin namely umbilical artery catheterization, but they can be due to peripartum asphyxia and systemic septicemia where the balance of endothelial regulation leans towards a procoagulant state. Other risk factors include hyperviscosity promoted by polycythemia and dehydration in newborn of diabetic mother or cyanotic congenital heart disease, inherited coagulation disorders especially protein C, protein S and factor XII deficiencies, viral infections by cytomegalovirus and herpes which alters the normal thromboresistant endothelial surface, birth trauma and raised antiphospholipid antibodies [4-6].

Clinical features are variable according to the location, the extent of the thrombosis and effectiveness of collateral perfusion. Ischemia of a limb which

becomes cold, pale or cyanotic, with diminished or abolished pulses is the most frequent symptomatology seen in limb arteries or aorta thrombosis. Other symptoms may include renal failure with hypertension or congestive heart failure [2]. Symptoms may be ambiguous and mimic other disorders such as aorta coarctation which is also characterized by absent lower extremity pulse [7].

The diagnosis of aorta thrombosis is better assessed by imaging techniques with the Doppler ultrasonography being the first-line investigation of thrombosis in neonates; it is non-invasive, inexpensive and involves minimum risk to the patient. However, this technique provides imprecise anatomic details and is an operator-experience dependant technique. Angiography has the advantage of providing precise outline of aortic thrombus, but it requires a special technical platform and it's more invasive which can be dangerous in these sick children [5, 2, 8].

Magnetic resonance imaging or Contrast-enhanced CT may also play a role in the evaluation of arterial thrombosis. Contrast enhanced CT is widely available, almost non-invasive with a relatively affordable price, allowing visualization of very fine circulating channels due to its high resolution. Another advantage is its capacity to place the vessels in their anatomical environment on axial sections [1, 9, 10].

Management of neonatal abdominal aortic thrombosis is still controversial and is considered on a case-by-case basis according to the centers capabilities. Treatment options include expectant management in asymptomatic cases, therapeutic anticoagulation using heparin or Low molecular weight heparin, thrombolysis with tissue plasminogen activator and surgical thrombectomy which could be considered in major aortic thrombi with acute limb-threatening ischemia [1, 11].

Besides the role of radiology in diagnosis of thrombosis and evaluation of its relationship to the adjacent structures, it's crucial for post-treatment follow up which is essentially made by Doppler ultrasonography [9].

## CONCLUSION

Doppler Ultrasonography is first-line examination for diagnosis of aortic thrombosis in neonates. However, its lack of anatomic precision makes the Contrast Enhanced Computed tomography the imaging technique of choice in investigation of ischemia due to aortic thrombosis, as it provides the topography and extension of the thrombosis, also identifies the ischemic phenomena of abdominal organs and limbs [8, 10].

## Conflict of interest

The authors declare no conflict of interest

## REFERENCES

- Dieffenbach, B. V., Nath, B. D., Tracy, E. T., & Kim, H. B. (2019). Management of symptomatic neonatal aortic thrombosis: When is surgery indicated?. *Journal of Pediatric Surgery Case Reports*, 47, 101247.
- Ayad, A., Lemouakni, S., Tami, L., Oulja, M., Knouni, H., & Barkat, A. (2017). Spontaneous neonatal aortic thrombosis revealing protein S deficiency. *Journal de Medecine Vasculaire*, 43(1), 56-60.
- Wong, E. C., & Punzalan, R. (2021). Thrombotic disorders in children. In *Biochemical and Molecular Basis of Pediatric Disease* (pp. 601-634). Academic Press.
- Nowak-Göttl, U., von Kries, R., & Göbel, U. (1997). Neonatal symptomatic thromboembolism in Germany: two year survey. *Archives of Disease in Childhood-Fetal and Neonatal Edition*, 76(3), F163-F167.
- Chalmers, E.A. (2000). Neonatal thrombosis. *J Clin Pathol*, 53(6); 419-423.
- Nicholson, A. C., & Hajjar, D. P. (1999). Viral activation of the coagulation cascade. *American heart journal*, 138(5 Pt 2), S461-S464.
- Piersigilli, F., Auriti, C., Landolfo, F., Campi, F., Schingo, P., & Dotta, A. (2014). Spontaneous thrombosis of the abdominal aorta in two neonates. *Journal of Perinatology*, 34(3), 241-243.
- Deeg, K. H., Wölfel, D., & Rupprecht, T. H. (1992). Diagnosis of neonatal aortic thrombosis by colour coded Doppler sonography. *Pediatric radiology*, 22(1), 62-63.
- El Bakkari Asaad, O. A., Yassine, S., Youssef, D., Najlaa, S., Allali, N., & Chat, L. (2019). Umbilical artery catheterization a causé of abdominal aortic thrombosis in neonates: A case report. *Int J Case Rep Images*, 10, 101037Z01EA2019.
- Verbeeck, N., Cavez, N., Plawny, L., Weber, J., & Lens, V. (2014). Primary aortic thrombosis: role of enhanced multislice CT demonstrated in three exceptional cases. *Jbr-Btr*, 97(2), 76-80.
- Bogović, M., Papeš, D., Mitar, D., Smiljanić, R., Sršen-Medančić, S., Čavar, S., ... & Luetić, T. (2016). Abdominal aortic thrombosis in a healthy neonate. *Annals of Vascular Surgery*, 32, 131-e7.