

Presurgical Radiologic Delineation of Popliteal Pterygium Syndrome: Case Report

Adam Hajjine^{1*}, Btissam Zouita¹, Dounia Basraoui¹, Hicham Jalal¹

¹Radiology Department of Mohamed VI University Hospital, Marrakech, Morocco

DOI: [10.36347/sjmcr.2022.v10i03.022](https://doi.org/10.36347/sjmcr.2022.v10i03.022)

| Received: 21.02.2022 | Accepted: 26.03.2022 | Published: 30.03.2022

*Corresponding author: Adam Hajjine

Radiology Department of Mohamed VI University Hospital, Marrakech, Morocco

Abstract

Case Report

Popliteal pterygium refers to the presence of an abnormal triangular fold of connective tissue occurring in the knee extending from the ischium to the os calcis. The popliteal artery and peroneal nerve are abnormally located within or adjacent to the pterygium. Since their preservation is important, knowledge of their exact location before surgery is essential. Hence, the role of preoperative imaging. We present here the radiologic features of a popliteal pterygium and the position of neurovascular structures in 18 months-old boy referred to radiology department for presurgical delineation. MRI is the imaging test of choice for the presurgical delineation in children who are candidate to surgical correction of contractures of popliteal pterygium. It may depict the popliteal artery and posterior tibial and peroneal nerves either in the normal position or abnormally located to the pterygium.

Keywords: Popliteal pterygium, presurgical delineation, MRI.

Copyright © 2022 The Author(s): This is an open-access article distributed under the terms of the Creative Commons Attribution 4.0 International License (CC BY-NC 4.0) which permits unrestricted use, distribution, and reproduction in any medium for non-commercial use provided the original author and source are credited.

INTRODUCTION

The first case of popliteal pterygia was recorded by Trelat in 1869 and only 200 cases have been so far reported in the literature [1]. Popliteal pterygia is described as a wringlike structure typically attached to the ischium and os calcis responsible of a functional impairment of the knee [2, 3].

Since conservative treatments such as casting and traction didn't give satisfying results, the surgical resection of pterygium bands remains the method of the choice to relief the contracture [1]. However, in popliteal pterygium, the popliteal artery and peroneal nerve are abnormally located within or adjacent to the pterygium. Their preservation is crucial and knowledge of their exact location before surgery is essential. Hence, the role of preoperative imaging.

We present here the radiologic features of a popliteal pterygium in 18 months-old boy referred to radiology department for presurgical delineation, along with a literature review.

CASE REPORT

An 18-months old boy was referred to the radiology department for presurgical evaluation of bilateral knee flexion contracture due to popliteal

pterygium as a part of popliteal pterygium syndrome. The child also presented with a bilateral epicanthus, bilateral cryptorchidism, an incomplete left hand syndactyly and bilateral talipes equinovarus (Figure 1).

At first, a computed tomography of both lower limbs was performed showing presence of subcutaneous soft tissue bands arising from the ischium and terminating on the upper half posterior aspect of the leg, after passing through the posterior aspect of the thigh and popliteal fossa. These bands were made up of fatty tissue crossed by the muscles of the medial and dorsal compartments of the thigh which are at a distance from the bone. The superficial femoral arteries were permeable, of normal caliber, located on the posteromedial aspect of the femur at respectively a distance of 1cm on the right and 1.3cm on the left. The popliteal arteries were permeable, of normal caliber and located at a distance of 3cm from the knee joint. They branches into anterior tibial artery and tibioperoneal trunk, the latter one running besides the bone at a distance of 1,6cm on the right and 2cm on the left (Figure 2).

As the exact location of the peroneal nerves was difficult to assess by the CT scan, a magnetic resonance imaging was performed which revealed an abnormally positioned peroneal nerve coursing away

from the knee joint at 6,5 cm on the right and 6.3cm on

the left (Figure 3).

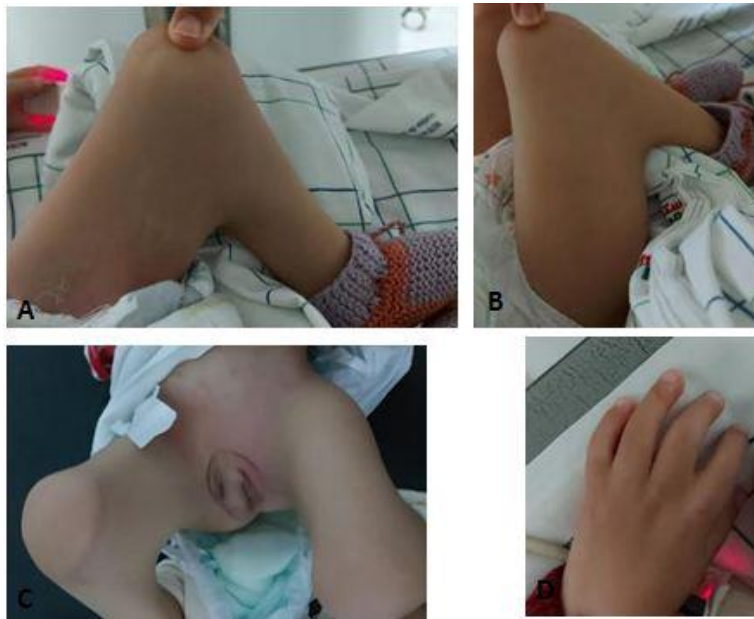

Figure 1: A. Left knee flexion contracture due to popliteal web. B. Right knee flexion contracture due to popliteal web. C. Bilateral cryptorchidism. D. Incomplete syndactyly of the right hand

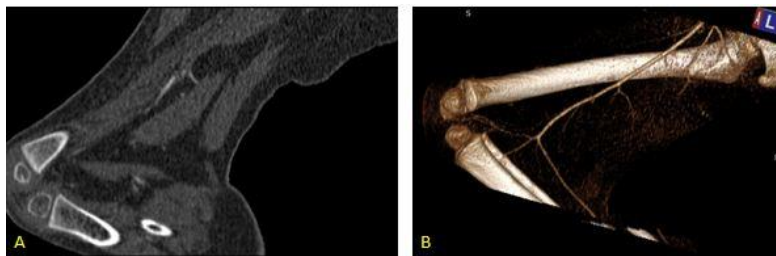


Figure 2: A. Sagittal view on computed tomography characterizing the right popliteal pterygium as subcutaneous soft tissue bands composed of fatty tissue crossed by muscles. B. Volume rendering Technique view on Computed tomography showing the trajectory of the right popliteal artery and its branches

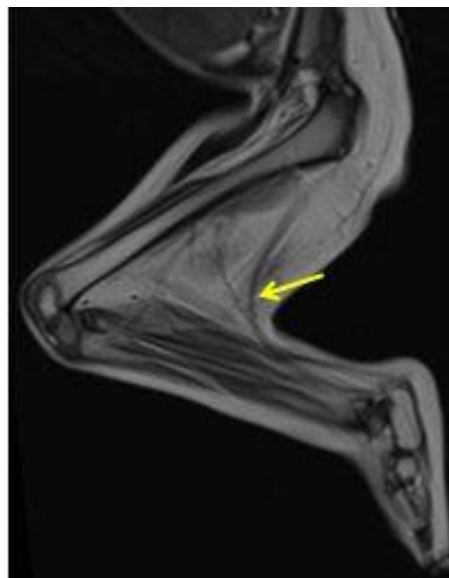

Figure 3: MRI of right popliteal pterygium showing an abnormally positioned popliteal nerve coursing away from the knee joint

DISCUSSION

Popliteal pterygium refers to the presence of an abnormal triangular fold of connective tissue occurring in the knee extending from the ischium to the os calcis. [2-4]

Popliteal pterygia may be incomplete, unilateral or bilateral. It is usually syndromic included within the multiple pterygium syndrome or Escobar syndrome characterized by the presence of webbing in the neck, fingers, forearms or inner thighs. It could also be part of the popliteal pterygium syndrome which is a rare autosomal dominant disorder that consists of popliteal webs associated to craniofacial anomalies (lower lip pits, cleft palate, micrognathia, choanal atresia), to genitourinary anomalies (absent or cleft scrotum, cryptorchidism, ambiguous genitalia), and to extremity anomalies (syndactyly, other hand or feet deformities, scoliosis, rib abnormalities) [2-5].

Surgical resection of the popliteal pterygium may be performed to relieve the resulting flexion deformity of the lower extremity. The popliteal artery and peroneal branch of the sciatic nerve are often abnormally positioned immediately adjacent to or in the pterygium which makes surgery precarious and difficult [2].

It is important to know the exact position of the neurovascular bundle before a surgical resection of the pterygium or correction of the contracture to avoid an accidental transecting of these structures [2, 3]. Therefore, CT scan and MR imaging are useful for the presurgical delineation by screening the anatomic location of the popliteal artery and peroneal nerves and depicting their relationship to the pterygium [3].

Ct scan and 3D reconstruction may be used to analyze the anatomy of the deformity. Contrast enhanced CT can accurately identifies the popliteal artery [1].

MRI does not involve ionizing radiation, which is important to the patients in the pediatric age-group. And due to its excellent soft tissue resolution, it

is useful for locating the sciatic and peroneal nerves. The pterygium appears as a band of fibrous tissue with characteristic signals extending from the ischium to the os calcis and often attached to a belly of anomalous muscle along portions of the fibrous bands. Axial and sagittal T1- weighted MRI show the position of the peroneal nerve in relation to the pterygium bands. Post-contrast fat-suppressed sagittal T1-weighted MRI and Angio MRI display the position of the popliteal arterie in relation to the pterygium [1].

CONCLUSION

MRI is the imaging test of choice for the presurgical delineation in children who are candidate to surgical correction of contractures of popliteal pterygium. It may depict the popliteal artery and posterior tibial and peroneal nerves either in the normal position or abnormally located to the pterygium.

Conflict of Interest: The authors declare no conflict of interest.

REFERENCES

1. Mariappan, N., & Sanket, S. (2016). Popliteal Pterygium Syndrome (Facio-Genito-Popliteal Syndrome). *Journal of Advanced Plastic Surgery Research*, 2, 33-43.
2. Oppenheim, W. L., Larson, K. R., McNabb, M. B., Smith, C. F., & Setoguchi, Y. (1990). Popliteal pterygium syndrome: an orthopaedic perspective. *Journal of pediatric orthopedics*, 10(1), 58-64.
3. Donnelly, L. F., Emery, K. H., & Do, T. T. (2002). MR imaging of popliteal pterygium syndrome in pediatric patients. *American Journal of Roentgenology*, 178(5), 1281-1284.
4. Taybi, H., & Lachman, R. S. (1996). Radiology of syndromes, metabolic disorders, and skeletal dysplasias, 4th ed. St. Louis: Mosby, 411-413.
5. Oppenheim, W. L., Larson, K. R., McNabb, M. B., Smith, C. F., & Setoguchi, Y. (1990). Popliteal pterygium syndrome: an orthopaedic perspective. *Journal of pediatric orthopedics*, 10(1), 58-64.