

Outcome Analysis of Urethroplasty in Distal Hypospadias with Minimal Period of Postoperative Stenting

Dr. Mohammad Billal Hossain^{1*}, Dr. Md. Naheen Rezuan Shehran Asif², Dr. Zia Uddin Ahmed³, Dr. Md. Sakhawat Hossain⁴, Dr. Debashis Chakraborty⁵, Dr. Anowrul Azim⁶, Dr. Lubaba Mushtab Shirah⁷

¹Assistant Registrar, Department of Paediatric Surgery, Mymensingh Medical College Hospital, Mymensingh, Bangladesh

²Specialist, Department of Paediatric Surgery, Evercare Hospital, Dhaka, Bangladesh

³Assistant Professor, Department of Paediatric Surgery, Jalalabad Ragib Rabeya Medical College Hospital, Sylhet, Bangladesh

⁴Registrar, Department of Paediatric Surgery, Mymensingh Medical College Hospital, Mymensingh, Bangladesh

⁵Assistant Professor, Department of Paediatric Surgery, Eastern Medical College Hospital, Cumilla, Bangladesh

⁶Medical Officer, Godagari Upazila Health Complex, Rajshahi, Bangladesh

⁷MS Resident, Department of Paediatric Surgery, Mymensingh Medical College Hospital, Mymensingh, Bangladesh

DOI: [10.36347/sasjs.2022.v08i03.020](https://doi.org/10.36347/sasjs.2022.v08i03.020)

| Received: 19.02.2022 | Accepted: 25.03.2022 | Published: 30.03.2022

*Corresponding author: Dr. Mohammad Billal Hossain,

E-Mail ID: bh677992@gmail.com

Assistant Registrar, Department of Paediatric Surgery, Mymensingh Medical College Hospital, Mymensingh, Bangladesh

Abstract

Original Research Article

Background: Glandular, coronal, and distal penile are the variants of distal hypospadias. Surgical techniques for distal hypospadias varied based on the location of the meatal opening. Usual variants of techniques of surgery are glanduloplasty, MAGPI, and tabularized incised plate with or without internal urethral stenting postoperatively. **Aim of the study:** To see the outcome of urethroplasty in distal hypospadias with a minimal period (<48 hours) of postoperative stenting. **Methodology:** This Quasi-experimental study was conducted from January 2018 to April 2019 in the Department of Pediatric Surgery, Mymensingh medical college hospital, Mymensingh. Among the 50 patients with distal hypospadias who fulfill the inclusion and exclusion criteria. MAGPI and TIP procedures were done with a minimum period of postoperative stenting (<48hours). Postoperative care by nothing per oral for 4-6 hours, intravenous fluid, intravenous antibiotics, parenteral, and per rectal analgesics. Postoperative follow-up was observed and recorded if any uneventful events occurred, measures were taken accordingly. The stent was removed on the 2nd POD and discharged the patient on the 3rd POD. After discharge, all patients were followed up for 3 months. Data were analyzed by statistical package for social sciences (SPSS) version 20. **Results:** Among the 50 patients, the age range was 6 months to 12 years with the mean age 6.08 ± 3.69 years. 8(16%) patients were glandular variety, 22(44%) patients were coronal and 20(40%) were distal shaft variant. Among them, MAGPI procedures were performed in 18(36%) patients and TIP in 32(64%) patients. Immediate postoperative complications- hematoma 2(4%), stent block 2(4%), wound disruption 2(4%). Stent block treated by normal saline irrigation through stent, hematoma, and wound disruption by local wound care. Among the 2(4%) patients with hematoma, 1(2%) patient developed wound infection, later on, U-C fistula occurred and among the 2(4%) patients of wound disruption, wound infection occurred in 2(4%) patients and finally developed U-C fistula in spite of all measures were taken. Urinary stream after urethroplasty 43(86%) patients were a normal stream, 4(8%) patients were narrow stream which was gentle neo meatal dilatation by lubricated BMI feeding tube with 2% jesocaine jelly. The skin condition of 47(94%) patients during stent removal were healthy and 3(6%) patients' skin condition was unhealthy. Finally, among the 50 cases, 44(88%) patients were uneventful, 2(4%) patients were hematoma formation, 2(4%) patients were stent blockage, 2(4%) patients developed wound disruption, 3(6%) patients developed wound infection and 3(6%) patients developed U-C fistula. **Conclusion:** Urethroplasty for distal hypospadias with a short period of urethral stenting is safer, reduces hospital stay, increases patient compliance with minimal morbidity compared long period of urethral stenting.

Keyword: Glandular, Distal hypospadias, Glanduloplasty, MAGPI procedure.

Copyright © 2022 The Author(s): This is an open-access article distributed under the terms of the Creative Commons Attribution 4.0 International License (CC BY-NC 4.0) which permits unrestricted use, distribution, and reproduction in any medium for non-commercial use provided the original author and source are credited.

INTRODUCTION

Hypospadias is an anomaly characterized by a urethral meatus that opens abnormally in the ventral surface of the penis, proximal to the end of the glans.

The meatus may be located anywhere along the shaft of the penis from the glans to the perineum [1]. Hypospadias is the result of the failure of fusion of the urethral folds on the ventral aspect of the penis. It occurs approximately 3.2 per 1000 male live births or 1

Citation: Mohammad Billal Hossain, Md. Naheen Rezuan Shehran Asif, Zia Uddin Ahmed, Md. Sakhawat Hossain, Debashis Chakraborty, Anowrul Azim, Lubaba Mushtab Shirah. Outcome Analysis of Urethroplasty in Distal Hypospadias with Minimal Period of Postoperative Stenting. SAS J Surg, 2022 Mar 8(3): 176-181.

in every 300 male children. Anatomical anomalies of the penis in hypospadias include, (i) An abnormal ventral opening of the urethral meatus which can be located anywhere of the ventral aspect of the penis or in the perineum, (ii) An abnormal ventral curvature of the penis. (iii) An abnormal distribution of foreskin around the glans with the ventrally deficient hooded foreskin [2]. Hypospadias is a congenital deformity and its surgery is both an art and science, and the fact that over two hundred different types of repairs have been reported in the literature confirms that it is difficult surgery with many complications and frequently inadequate cosmetic and functional results [3]. The type and incidence of complications vary with the particular form of hypospadias and its repair. urethrocutaneous fistula is the most commonly reported complication of hypospadias surgery: currently, an expected fistula formation of 10-15% exists for one-stage hypospadias surgery [4]. All hypospadias repair has been the use of a bladder drainage catheter or a stent, the purpose of which has been to provide temporary urinary diversion, immobilize the suture line, drain the neourethra and reduce retraction of neourethral caliber. On the other hand, the disadvantage of catheter drainage or stenting include the length of hospital stay (4-8 days), decrease patient mobility, bladder spasm, and increased potential for infection. Other complications include migration into the bladder and mechanical catheter problems that may create inadequate drainage and even result in pressure ischemia of the neourethra [5]. In an effort to reduce complications, patients are typically left with an indwelling urethral stent or catheter following hypospadias repair. However, a variety of surgical techniques have documented low complication rates for distal hypospadias repair with stent durations ranging from overnight to a week or longer without significant differences in complication rates, the benefit of the ideal duration of urethral stenting is unknown. The benefit of stentless repair is avoiding the associated adverse events, including infections, bladder spasms, stent migration, need for additional medications, short-term follow-up for stent removal, and parental anxiety. Previously this sort of study was done comparing urethroplasty for distal hypospadias with stenting and nonstenting postoperatively. From their recommendation, I like to see the outcome of urethroplasty with a minimal period (<48 hours) of postoperative stenting.

OBJECTIVES

General objective

To see the outcome of urethroplasty in distal hypospadias with a minimal period (<48hours) of postoperative stenting.

Specific Objective

- To see the post-operative complications following urethroplasty with a minimal period (<48hours) of stenting.
- To see the patient compliance.

MATERIALS AND METHODS

It was a Quasi-experimental study conducted in the Department of Paediatric Surgery, Mymensingh Medical College Hospital, Mymensingh from January 2018 to April 2019. The Institutional Review Board (IRB) of Mymensingh Medical College approved the study. A total number of 50 patients who were admitted to the Paediatric Surgery Department in Mymensingh Medical College Hospital as routine admission in the outpatient department (OPD) with distal hypospadias who fulfill the inclusion and exclusion criteria were recruited as the study population. Purposive sampling methods were followed for sample selection. The patient who was at the age of 6 month-12 years had distal hypospadias with minimal chordee or without chordee were included in the study. Patients with distal variant hypospadias with mega meatus intact prepuce and who underwent a secondary or redo surgery for hypospadias was excluded. After obtaining the written consent of the parents/guardian detailed information was collected from the patient’s mother or accompanying guardian. All this information was gathered systematically and put into the questionnaire. After obtaining a detailed history of each patient, a diagnostic work-up was done by thorough clinical examination and relevant investigations. MAGPI and TIP procedures were done with a minimum period of postoperative stenting (<48hours). Postoperative care by nothing per oral for 4-6 hours, intravenous fluid, intravenous antibiotics, parenteral, and per rectal analgesics. Postoperative follow-up was observed and recorded if any uneventful events occurred, measures were taken accordingly. The stent was removed on the 2nd POD and discharged the patient on the 3rd POD. After discharge, all patients were followed up for 3 months. Data were analyzed by statistical package for social sciences (SPSS) version 20.0 software.

RESULTS

Table-I: Age distribution of the study population (N=50)

Age	n	(%)
6 months -2 yrs.	10	20.0
2-6 yrs.	14	28.0
6-12 yrs.	26	52.0
Age Mean ±SD	6.18±3.53	

Table I showed, regarding the participant’s age highest was 6-12 years age group 26(52%). The mean age was 6.18±3.53 years.

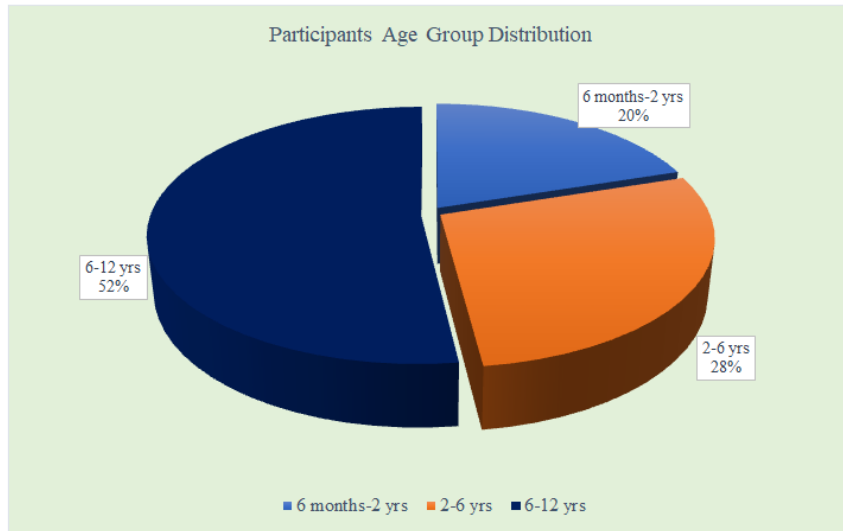


Figure 1: Participants Group-wise Age Distribution (N=50)

Table-II: Distribution of type of hypospadias (N=50)

Type	n	(%)
Coronal	16	32.0
Sub coronal	14	28.0
Distal penile shaft	20	40.0

Table II showed the distribution of types of hypospadias. Coronal, sub coronal, and distal penile shaft variety of distal hypospadias were included in this study. Among them 16(32%) were coronal, 14(28%) were sub coronal and 20(40%) were distal penile shaft variety of distal hypospadias.

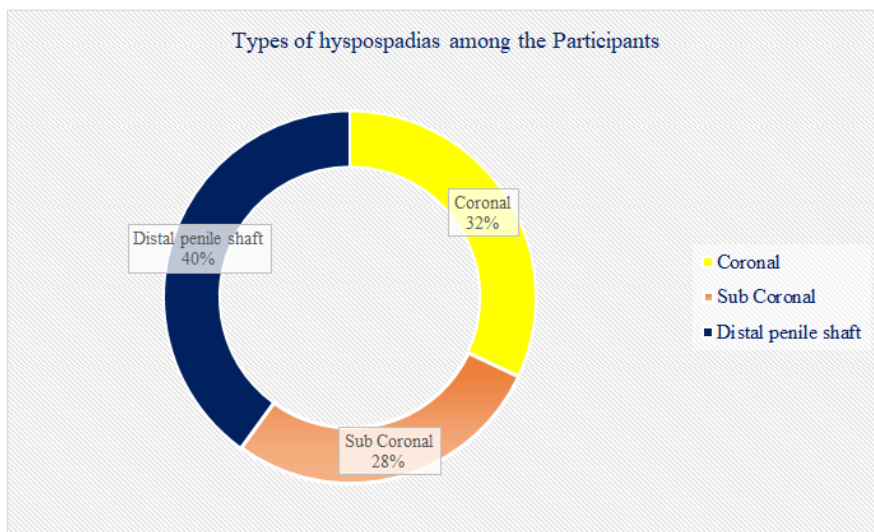


Figure II: Participants Group-wise Age Distribution (N=50)

Table III: Treatment modalities of the study population (N=50)

Age	Treatment modalities				P-value
	MAGPI		TIP		
	n	(%)	n	(%)	
6 months -2 yrs.	8	50.0	2	5.9	0.001 **
2- 6 yrs.	6	37.5	8	23.5	
6 -12 yrs.	2	12.5	24	70.6	
Total	16	100	34	100	

Table III showed, in treatment modalities of 16 MAGPI, 6 months-2 years age group was highest 8(50%) and of 34 TIP 6-12 years age group was highest

24(70.6%). P-value was 0.001, which was significantly significant.

Table IV: Immediate postoperative complications (N=50)

Type	Frequency (n)	Procedure		Percentage (%)
		MAGPI	TIP	
Hematoma	2	1	1	4.0
Stent blockage	2	0	2	4.0
Partial wound disruption	2	0	2	4.0
Stenosis	0	0	0	0.0

Table IV showed immediate postoperative complications (within 24 hours). The hematoma was in 2(4%) patients; one in each procedure, stent blockage

was 2(4%) patients (TIP) and partial wound disruption was 2(4%) of the patients (TIP). Stent blockage was relieved by normal saline irrigation through the stent.

Table V: Subsequent postoperative complication (N=50)

Primary complication	Frequency (n)	Improved	Wound infection & Urethrocutaneous Fistula (U-C)	Percentage (%)
Hematoma	2	1	1	4.0
Partial wound disruption	2	-	2	4.0

Table V showed subsequent complications (after 48 hours) of urethroplasty, 2(4%) patients of hematoma, 1(2%) was improved, and 1(2%) developed wound infection and subsequently developed U-C

fistula. 2(4%) patients of partial wound disruption which were subsequently developed wound infection and U-C fistula.

Table VI: Quality of urinary stream after urethroplasty (n=47)

Urinary stream	n	(%)
Normal	43	92.0
Narrow	4	8.0

Table VI showed the urinary stream after urethroplasty. 43(86%) patients were good stream and 4(14%) patients were narrow stream which was

calibration by BMI feeding tube with jesocaine jelly, 3(6%) patients developed fistula which was excluded from the following table.

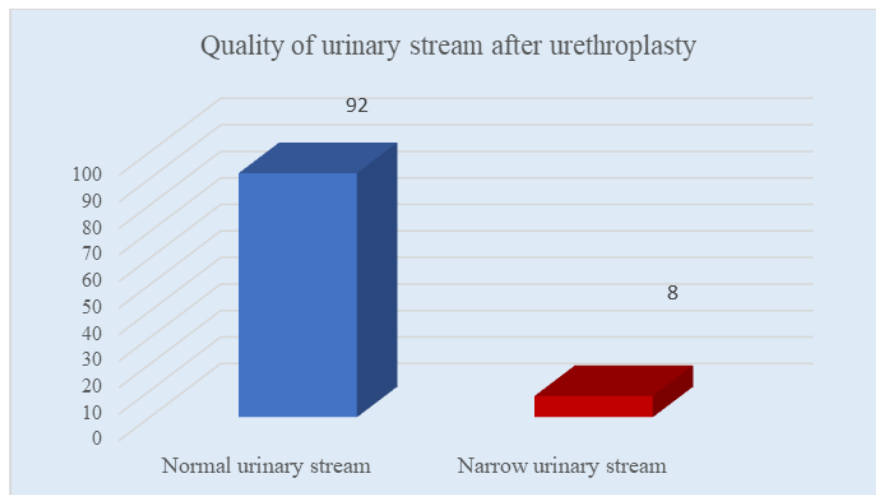


Figure III: Quality of urinary stream after urethroplasty (n=47)

Table VII: Skin condition during stent removal (N=50)

Skin condition	n	(%)
Healthy	47	94.0
Unhealthy	3	6.0

Table VII showed skin conditions during stent removal. Among the 50 cases 3(6%) patients' skin was unhealthy and 47(94%) patients' skin was healthy.

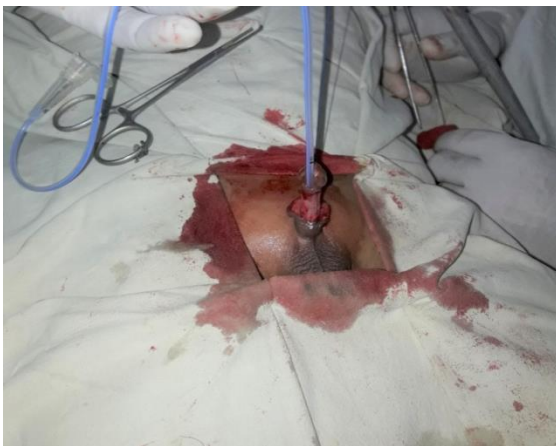Table VIII: The outcome of urethroplasty (N=50)

Uneventful	Hematoma		Stent blockage	Partial wound disruption Leading to wound infection following U-C fistula formation	Total
	Resolved	Not resolved (To lead to wound infection later on fistula formation)			
44(88%)	1(2%)	1(2%)	2(4%)	2(4%)	50(100%)

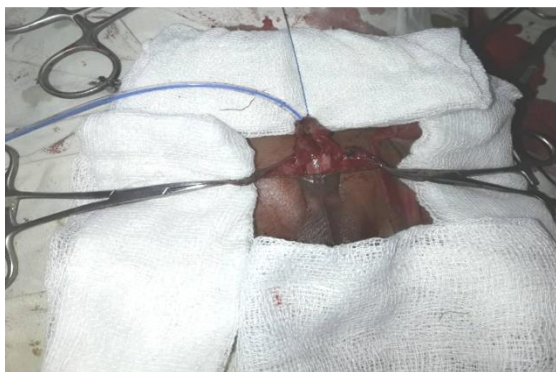Table VIII showed the outcome of urethroplasty. Among the 50 cases, 44(88%) patients were uneventful, 2(4%) patients were hematoma, 1(2%) was resolved by wound care and 1(2%) was developed wound infection, and later on, U-C fistula developed. 2(4%) patients were stent blockage, which was managed by normal saline irrigation through the stent. 2(4%) patients were partial wound disruption leading to wound infection and later on U-C fistula developed.



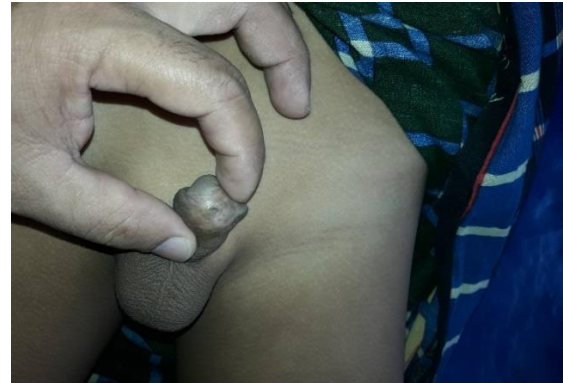Photograph A: Arrow shows distal variant (coronal) hypospadias



Photograph B: Degloving of penis same patient



Photograph C: Formation of neourethra the patient



Photograph B: Arrow shows U-C fistula after urethroplasty

DISCUSSION

The term distal hypospadias implies abnormal urethral opening located at the ventral aspect of proximal to glans. Coronal, sub coronal, and distal penile shaft variants are the variants of distal hypospadias. To reconstruct the hypospadias anomaly, still, that field is ready to accept new techniques, ideas, or tricks searching for operation. Surgical modalities depend on the site of the urethral opening. MAGPI and TIP are the usual surgical techniques of distal hypospadias repair. In this study age ranges of the patients were 6 months to 12 years with a mean age of 6.08 ± 3.69 years. Perlmutter AE *et al.*, study showed [6] age ranges of repair of distal hypospadias between 4 ± 1.2 years which is a bit lower than our study. This is due to ignorance, poverty, and lack of awareness of hypospadias surgery in our country. Schulz *et al.*, 1983 [7] compared the emotional, psychosexual, cognitive, and surgical risk for hypospadias, and the optimal window recommended for repair was 6-15 months of age. So, the mean age of urethroplasty in our study is higher. Coronal, sub coronal, and distal penile shaft variants of distal hypospadias were included in this study. Among them 16(32%) were coronal, 14(28%) were sub coronal and 20(40%) were distal penile shaft variants. The site of hypospadias is not consistent with other studies due to differences in study design. MAGPI procedure was performed in 16(32%) patients and TIP procedure was done in 34(68%) patients in this study. Coronal variants of distal hypospadias performed MAGPI procedure and sub coronal, distal penile shaft variants of distal hypospadias performed TIP procedure of urethroplasty. That's why procedures of urethroplasty in this study were not consistent with other studies. Immediate postoperative complications were hematoma 2(4%) patients 1 from MAGPI procedure and 1 from TIP procedure, stent blockage 2(4%) patients, both were from TIP procedure. And

partial wound disruption 2(4%) patients from TIP procedure in this study. 2(4%) patients with stent blockage occur due to mucous plug with clotted blood resolved by irrigation with normal saline through the stent. Among 2(4%) patients with hematoma 1(2%) was resolved by adequate management and 1(2%) was developed wound infection. Hasan MK *et al.*, (2011) [8] study showed hematoma occurred in 2(5%) patients, stent blockage occurred in 4(10%), and wound disruption occurred in 3(7.5%) which were more or less consistent with this study. Subsequent postoperative complications were wound infection and fistula formation. 1(2%) patient developed wound infection from hematoma which was not resolved subsequent management and thereby fistula formation occurred. 2(4%) wound infections occurred from subsequent 2(4%) partial wound disruption which later on fistula formation. So, in this study subsequent postoperative complications were wound infection and fistula formation 3 and 3 respectively. In Hadidi's [9] study fistula formation was 2% in the non-stented group which is not consistent with the present study. This may be due to the small study population in the Hadidi study [9]. Urinary stream following urethroplasty was normal in 43(86%) and narrow were 4(8%) which was minimized by gentle neo meatal dilatation by lubricated BMI feeding tube after two weeks of urethroplasty. 3(6%) patients were not included due to fistula formation Which is more or less consistent with the present study. Skin condition at the time of stent removal was healthy in 47(94%) and unhealthy-3(6%) patients. The overall outcome of urethroplasty for distal hypospadias with a minimal period (<48 hours) of stenting 44(88%) were uneventful, 2(4%) were hematoma formation 2(4%) were stent blockage, 2(4%) was wound disruption and 3(6%) were fistula formation. Overall, results and observations in the present study are consistent with other studies of non-stented groups with a bit deviation which is due study design of different studies.

LIMITATIONS OF THE STUDY

Due to the purposive sampling technique being followed, there might be some bias ness. The small sample size and short duration of the study was also the limitation of the study.

CONCLUSION AND RECOMMENDATION

Urethroplasty for distal hypospadias with a short period of urethral stenting is safer, reduces hospital stay, increases patient compliance with minimal post-operative complications Urethroplasty for distal hypospadias with minimal period of stenting showed good outcome with minimal post-operative complications with the increase of patient compliance and thereby longer period of stenting is no more needed in distal

REFERENCES

1. Murphy, J. P. (2005). Hypospadias. In: Ashcraft, K. W., Hholcomb, G. N., Murphy, J. P. (ed) 2005, paediatric surgery, W. B. Saunders Company, Philadelphia, 807-825
2. Sweet, R. A., Schrott, H. G., Kurland, R., & Culp, O. S. (1974, January). Study of the incidence of hypospadias in Rochester, Minnesota, 1940-1970, and a case-control comparison of possible etiologic factors. In *Mayo Clinic Proceedings* (Vol. 49, No. 1, pp. 52-58).
3. Duckett Jr, J. W., Kaplan, G. W., Woodard, J. R., & Devine Jr, C. J. (1980). Panel: complications of hypospadias repair. *The Urologic Clinics of North America*, 7(2), 443-454.
4. Duckett, J. W., & Baskin, L. S. (1998). Hypospadias. In: O'Neill, J. A., Rowe, M. I., Grosfield, J. A., Fankalsrud, E. W., Coran, A. G. (ed) Paediatric Surgery, 5th edn, Mosby Yearbook, St.Louis, Missouri, 2, 1761-1777.
5. Rabinowitz, R. (1987). Outpatient catheterless modified Mathieu hypospadias repair. *The Journal of Urology*, 138(4), 1074-1076.
6. Perlmutter, A. E., Morabito, R., & Tarry, W. F. (2006). Impact of patient age on distal hypospadias repair: a surgical perspective. *Urology*, 68(3), 648-651.
7. Schultz, J. R., Klykylo, W. M., & Wacksman, J. (1983). Timing of elective hypospadias repair in children. *Pediatrics*, 71(3), 342-351.
8. Hassan, M. K., Paul, A. C., Khair, M. A., Saha, R. K., Hanif, A., & Chowdhury, A. S. M. J. (2011). Single Stage Urethroplasty for Proximal Hypospadias with Chordee. *Faridpur Medical College Journal*, 6(2), 66-69.
9. Hadidi, A. (2004). 'Principles of hypospadias surgery', in Hadidi, A. T., & Azmi, A. F. (eds), Hypospadias Surgery, Springer company, Verlag Berlin, 99-105.