

Evaluation of Extra Dartos Pouch Fixation Technique of Orchiopexy in Ultrasonologically Detectable Inguinal Undescended Testis

Dr. Md. Naheen Rezuan Shehran Asif^{1*}, Dr. Mohammad Billal Hossain², Dr. Humyra Alam Mou³, Dr. Debashis Chakraborty⁴, Dr. Anowrul Azim⁵, Dr. Zia Uddin Ahmed⁶, Dr. A. K. M. Fahmid Noman⁷

¹Specialist, Department of Paediatric Surgery, Evercare Hospital, Dhaka, Bangladesh

²Assistant Registrar, Department of Paediatric Surgery, Mymensingh Medical College Hospital, Mymensingh, Bangladesh

³Clinical Trainer, Reproductive Health Services Training and Education Program (RHSTEP), Bangladesh

⁴Assistant Professor, Department of Paediatric Surgery, Eastern Medical College Cumilla, Bangladesh

⁵Medical Officer, Godagari Upazila Health Complex, Rajshahi, Bangladesh

⁶Assistant Professor, Department of Paediatric Surgery, Jalalabad Ragib Rabeya Medical College Hospital, Sylhet, Bangladesh

⁷Biochemist, 250 Bedded TB Hospital, Shaymoli, Dhaka, Bangladesh

DOI: [10.36347/sasjs.2022.v08i03.021](https://doi.org/10.36347/sasjs.2022.v08i03.021)

| Received: 23.02.2022 | Accepted: 26.03.2022 | Published: 30.03.2022

*Corresponding author: Dr. Md. Naheen Rezuan Shehran Asif,

Email: naheen.rezuan@gmail.com

Specialist, Department of Paediatric Surgery, Evercare Hospital, Dhaka, Bangladesh

Abstract

Original Research Article

Background: Undescended testis is a common genitourinary anomaly in a male child. Orchiopexy is the mainstay of treatment for undescended testis (UDT). Method of fixation may be sub dartos or extra dartos approach technique. This study is designed to find out the outcome of the extra dartos pouch fixation technique of orchiopexy in undescended testis. **Objective:** To evaluate the outcome of the extra dartos pouch fixation technique of orchiopexy in retaining testis in the scrotum. **Methodology:** This prospective observational study was conducted from January 2019 to April 2020 in the Department of Pediatric Surgery, Mymensingh Medical College, Mymensingh. A total of 30 patients with UDT who fulfilled the inclusion and exclusion criteria were included in this study group. History was recorded in a data collection sheet after taking informed written consent from the parents/guardians. Proper clinical examination, investigations were done. Pre and postoperative clinical and sonographic findings were taken to evaluate the outcome of the extra dartos pouch fixation technique of orchiopexy in undescended testis. All data were analyzed by SPSS version 20.0 software. **Result:** A total of 30 patients with undescended testis were included in this study. Age range 6 months to 6 years with a mean age of 3.48 ± 1.77 years. Among 30 patients 19(63.3%) had right-sided and 11(36.7%) had left-sided UDT. Sonological localization in the inguinal canal was 21(70%), the superficial inguinal ring was 9(30%). The associated hernia was present in 27(90%) patients. Preoperative sonographic measurements of mean length and breadth of testis were 1.49 ± 0.45 cm and 0.88 ± 0.34 cm respectively. Postoperative sonographic measurements of mean length and breadth were 1.46 ± 0.47 cm and 0.87 ± 0.35 cm respectively. The comparison between pre and postoperative sonographic measurement of length and breadth of testis was 0.098 ± 0.027 cm and 0.03 ± 0.01 cm respectively. No ascent of the testis nor testicular atrophy and no torsion of testis and the spermatic cord was observed in the follow-up period which extended up to 6 months. **Conclusion:** Extra dartos pouch fixation of orchiopexy in undescended testis provides adequate scrotal fixation, prevents recurrent torsion of the testis and spermatic cord, ascend of the testis, and increases the patient's parents' compliance.

Keywords: Undescended testis, Extra dartos pouch, Sub dartos pouch, Orchiopexy.

Copyright © 2022 The Author(s): This is an open-access article distributed under the terms of the Creative Commons Attribution 4.0 International License (CC BY-NC 4.0) which permits unrestricted use, distribution, and reproduction in any medium for non-commercial use provided the original author and source are credited.

INTRODUCTION

Undescended testis is a clinical disorder characterized by the absence of the testis from the base of the hemiscrotum to be arrested during development along the route of its descent [1]. With the 3% incidence at birth undescended testis is a common genitourinary anomaly in male infants and it decreases

to about 1% at age 1year [2]. The testicle develops in the abdomen and falls into the scrotal sac at the end of pregnancy in a developing male fetus. The testicles may not completely come down to the scrotal sac, one or both, which is referred to as cryptorchidism. The undescended testis can remain in the abdominal cavity or in the inguinal canal. The recommended treatment will be determined by the position of the testis or

Citation: Md. Naheen Rezuan Shehran Asif, Mohammad Billal Hossain, Humyra Alam Mou, Debashis Chakraborty, Anowrul Azim, Zia Uddin Ahmed, A. K. M. Fahmid Noman. Evaluation of Extra Dartos Pouch Fixation Technique of Orchiopexy in Ultrasonologically Detectable Inguinal Undescended Testis. SAS J Surg, 2022 Mar 8(3): 182-187.

whether it is palpable or not [3]. Treatment of undescended testis is hormonal and surgical. But surgical treatment is the mainstay of treatment for undescended testis. Hormonal treatment can be done alone or as complementary with surgical treatment. Both the treatment modalities can be done alone or combined to reduce the risk of impairment of spermatogenesis, decrease the risk of testicular germ cell tumor, minimize the risk of recurrent torsion of the testis and spermatic cord [4]. Timing of the orchiopexy should be as early as possible if there is no life-threatening condition. To maximize fertility and potentially reduce the risk of future malignancy, current guidelines recommended surgery should be performed before 12 months of age [5]. The operative procedure for undescended testis is orchiopexy which is appropriately done as an “open” or as a “laparoscopy” operation. Laparoscopy combined with an incision may maximize the result. In the case of the very high testicle, the orchiopexy procedure is done in more than one operation, this is called a “staged” operation [3]. Orchiopexy can be done by sub dartos and extra dartos pouch fixation technique. The traditional sub dartos pouch fixation technique involves trans fixation of the testicular wall at two separate points and fixation of the dartos fascia, the 'window' procedure, eversion of the parietal tunica vaginalis, and actual orchiopexy of the dartos pouch with the forming of a window in the dartos fascia and closing of the window from both sides which helps to retain the testes in position [6]. In this procedure, there is a chance of torsion of the testis and spermatic cord, trauma to the testis during fixation, and ascent of the testis [4]. The extra dartos pouch fixation procedure was first reported by Ritchey and Bloom as an alternative to the sub dartos pouch fixation procedure for its advantage. In this procedure, there is no need for suture fixation thus reducing the risk of testicular injury and producing a subcutaneous tract, that induces some adhesion between the cord covering and subcutaneous tissue thus preventing testicular ascent and torsion of the testis and spermatic cord. This present study evaluated the outcome of the extra dartos pouch fixation technique in retaining testis in the scrotum [6].

OBJECTIVES

General objective

Evaluation of the outcome of extra dartos pouch fixation technique of orchiopexy in undescended testis.

Specific Objective

- To observe the retained of the testis at the site of fixation.
- To evaluate the testis size & position, torsion of the testis, and spermatic cord.
- To evaluate the compliance of the patient's parents on the basis of satisfaction.

MATERIALS AND METHODS

This was a prospective observational study executed in the Department of Pediatric Surgery at Mymensingh Medical College Hospital, Mymensingh from January 2019 to April 2020. The Institutional Review Board (IRB) of Mymensingh medical college approved the study. A total number of 30 male child patients were admitted to the Pediatric Surgery Department in Mymensingh Medical College Hospital as routine admission through the outpatient department (OPD) with undescended testes had been recruited as the study population. For sample selection, a purposive sampling technique was followed. All patients were evaluated through proper clinical history, careful physical examination, and relevant investigations. All 30 patients underwent extra dartos pouch orchiopexy to see the outcome of this procedure. After obtaining the written consent detailed information was collected from the patient's mother or accompanying guardian. After obtaining a detailed history of each patient, a diagnostic work-up was done through clinical examination and relevant investigation. Proper evaluation of the patient was done by clinical examination and investigation the patient was placed in the supine position. Then general anesthesia was given with endotracheal intubation. Draping and painting were done from mid-chest to midhigh by chlorhexidine and povidone-iodine. A lower inguinal skin crease incision was made on the affected side followed by opening the external oblique aponeurosis and identification of the testis. Then the testis is dissected to free from the surrounding structure. Herniotomy was performed for the associated hernial sac. After freeing of the testis, the length of the spermatic cord is measured and if the length is adequate a transverse scrotal incision is made on the affected side of the scrotum followed by passage of blunt-tipped artery forceps to dissect the subcutaneous tissue to produce a roomy subcutaneous pouch that will retain the freed testis. The artery forceps then pushed upwards till the neck of the scrotum where it pierces the subcutaneous tissue to become in line with the open groin space. Catch the mobilized testis in its normal anatomical direction and brought down to the created pouch where it is not fixed by suture. Then both the skin incision is closed by absorbable suture (vicryl 4-0). Data were analyzed to obtain the result by standard statistical formula by using computer-based software, Statistical Package for Social Science (SPSS, version 20.0). P-value < 0.05 considered statistically significant.

RESULTS

Table-I: Age distribution of study population (N=30)

Age of the children	n	(%)
6 months-2 years	10	33.3
3-4 years	9	30.0
5-6 years	11	36.7
Age of the children Mean \pm SD	3.48 \pm 1.77	

Table I showed among the total of 30 participants, 5-6 years was the highest 11(36.7%) in the age group, and the mean age was 3.48±1.77.

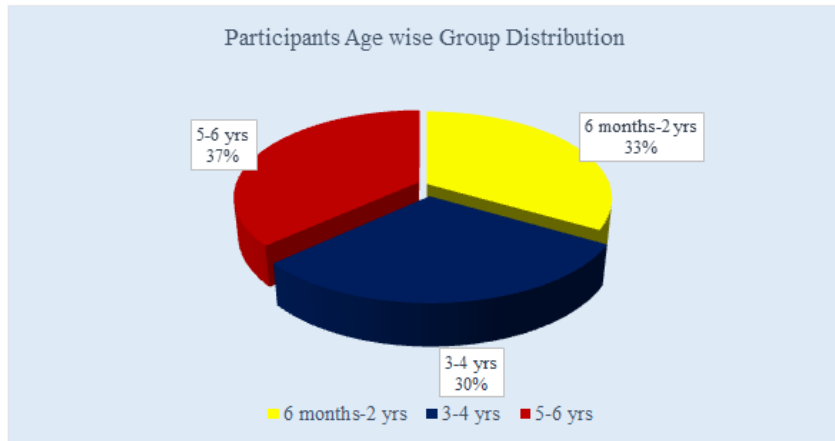


Figure 1: Participants Age-wise Groups Distribution

Table-II Side distribution of study population (N=30)

Side of undescended testis	n	(%)
Right	19	63.3
Left	11	36.7

Table II showed among side distribution, the right side was highest 19(63.3%), followed by the left side 11(36.7%).

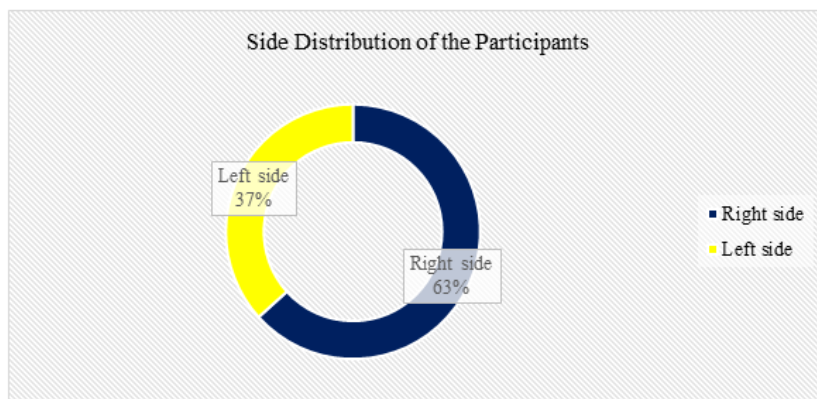


Figure 2: Side Distribution of the Participants

Table-III: Clinically detectability of the testis among study population (N=30)

Clinically detectability	n	(%)
Palpable	24	80.0
Impalpable	6	20.0

Table III showed clinically detectability palpable was highest 24(80%) and rest 6(20%) was impalpable respectively.

Table-IV: Preoperative sonographic location of the testis of the study population (N=30)

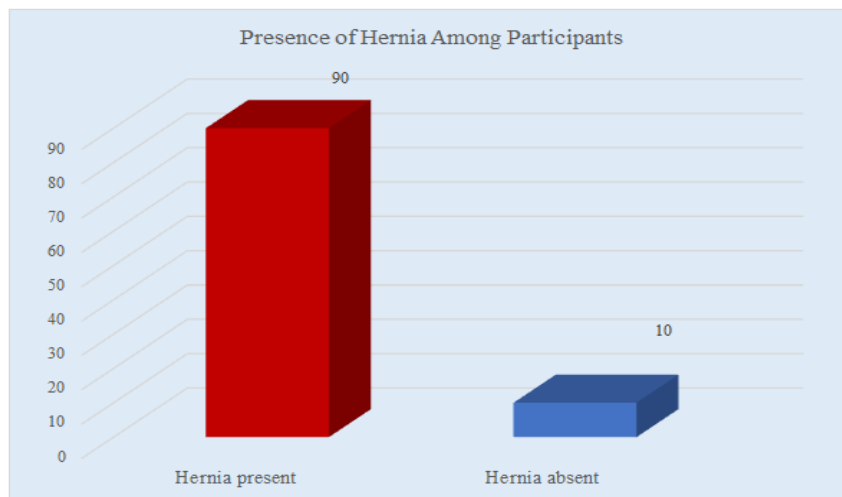
Location of testis	n	(%)
Inguinal Canal	21	70.0
Superficial inguinal ring	9	30.0

Table IV showed in preoperative sonographic location, the inguinal canal was highest at 21(70%) and the superficial inguinal ring was 9(30%) respectively.

Table-V: Associated hernia (N=30)

Presence of hernia	n	(%)
Present	27	90.0
Absent	3	10.0

Table V showed among the total participants, hernia presence was almost maximum participants 27(90%) and absent was only 3(10%).

**Figure 3: Presence of Hernia among the Participants****Table-VI: Preoperative sonographic length and breadth measurement (N=30)**

Preoperative	Mean \pm SD
Length (cm)	1.49 \pm 0.45
Breadth (cm)	0.88 \pm 0.34

Table VI showed in preoperative sonographic findings the mean length of testis of the participants was 1.49 \pm 0.45 cm and the mean breadth was 0.88 \pm 0.34.

Table-VII: Postoperative sonographic length and breadth measurement (N=30)

Postoperative	Mean \pm SD
Length (cm)	1.46 \pm 0.47
Breadth (cm)	0.87 \pm 0.35

Table VII showed in postoperative sonographic findings the mean length of testis of the participants was 1.46 \pm 0.47cm and the mean breadth was 0.87 \pm 0.35.

Table-VIII: Relation between pre and postoperative length and breadth of the testis (N=30)

Traits	Difference between pre and postoperative length/width of testis		t score	p-value
	Mean	\pm SD		
Length of testis	0.098	0.027	1.49	0.147
Breadth of testis	0.03	0.01	1.80	0.083

Table VIII showed the mean difference of testis pre-and post-operative length was 0.098 \pm 0.027 and 0.03 \pm 0.01. The t- score length & breadth was 1.49 & 1.8 and the p-value was 0.147 & 0.083 respectively.

Table-IX: Postoperative complications (N=30)

Types of postoperative complications (On 3rd POD)	n	(%)
Hematoma	1	3.3
Wound infection	2	6.7

Table IX showed in postoperative complications among the participants, wound infection was 2(6.7%) and the hematoma was only 1(3.3%).

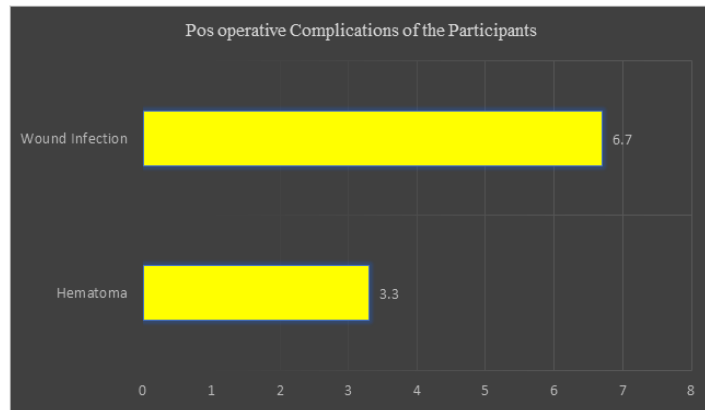
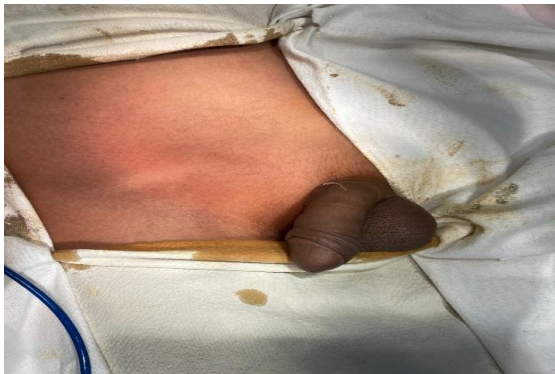
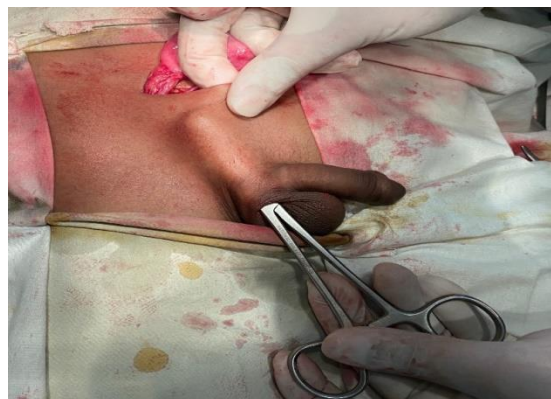
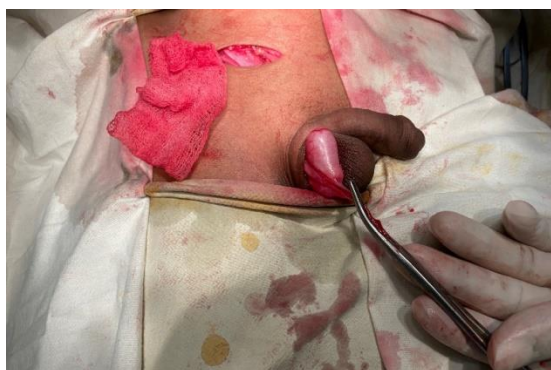Figure 4: Post Operative Complication of the Participants



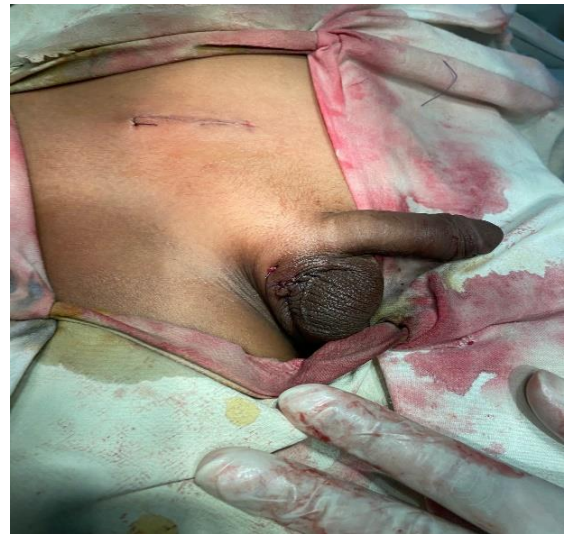Photography II: A patient with rt-sided palpable UDT



Photography II: Subcutaneous tunnel formation of the patient



Photography III: Descent of the testis through the tunnel of the patient



Photography IV: After positioning of the testis at extra dartos pouch, closure of the scrotal and inguinal incision of a patient

DISCUSSION

Undescended testis is a common genitourinary anomaly in a male child and affects 3% of male newborns. The incidence is slightly less than 1% at the age of 1 year [2]. Treatment of undescended testis is hormonal, surgical, or a combination of both. Orchiopexy is the mainstay of therapy for UDT with the targets to provide adequate scrotal fixation, prevent recurrent torsion of the testis and spermatic cord, and the ascent of the testis. Methods of orchiopexy may be sub dartos or extra dartos fixation technique, where extra dartos pouch fixation technique fulfilled the above criteria [6]. Age at presentation of the patients ranges from 6 months to 6 years. Peak incidence was observed within 5-6 years of age group, which was 11(36.7%) in number and lowest incidence observed within 3-4 years of the age group which was 9(30%) in number. The average age of presentation was 3.48 ± 1.77 years. Tseng, Huang, and Chiang (2016) [7] reported in their study that the average patient's age at presentation was 2.1 years. Age at presentation of this study is more or less consistent with other studies. The side of involvement in this study were 19(63.3%) on the right side, 11(36.7%) were on the left side. Van der Plas

(2013) [8] study showed right-sided predominance. Ghnnam, Ghazy, and Saed (2011) [6] showed 49.1% on the right side and 32.7% on the left side. Side of involvement of present study consistent with other studies with right-sided predominance. Preoperative evaluation of sonographic localization 21(70%) was in the inguinal canal, 9(30%) were in the superficial inguinal ring. Ghnnam, Ghazy, and Saed (2011) [6] study showed 54.16% were intracanalicular and 45.86% were in the superficial inguinal ring. The sonological location of the testis of the present study is consistent with other studies. The associated hernia was present in 27(90%) patients and absent in 3(10%) patients in the present study. In Ghnnam, Ghazy, and Saed. (2011) [6] study showed hernial sac was found in 95% of cases. The associated hernia is consistent with this study. Preoperative sonographic measurements of mean length and breadth of testis were 1.49 ± 0.45 cm and 0.88 ± 0.34 cm respectively. SK Jahid Boksh (2006) [9] showed that mean length and breadth were 1.36 ± 0.2 cm and 0.90 ± 0.01 cm respectively. So, this present study is consistent with other studies. Postoperative sonographic measurements of mean length and breadth were 1.46 ± 0.47 cm and 0.87 ± 0.35 cm respectively, other studies did not show the postoperative sonographic measurement of the testis, so consistency could not be evaluated. Here the comparison between pre and postoperative sonographic measurement of length and breadth of testis was 0.098 ± 0.027 cm ($P=0.147$) and 0.03 ± 0.01 cm ($P=0.083$) respectively. Both of them are not statistically significant. In this study, postoperative complications were hematoma 1(3.3%) patients, wound infection 2(6.7%) patients. In Ghnnam, Ghazy, and Saed. (2011) [6] study showed postoperative complications were hematoma (2.77%) and wound infection (1.38%), which is more or less consistent with this present study. The overall outcome of extra dartos pouch orchiopexy in undescended testis, no ascent of the testis nor testicular atrophy, and no torsion of testis and the spermatic cord was observed because we produce a long subcutaneous track for the spermatic cord and the testis to avoid the testis to be immediately facing the opening in the dartos and tunica thus reduce the possibility for the testicular ascent. This track also provides adhesion between cord coverings and subcutaneous tissue thus further preventing testicular ascent. Overall, the findings and observations in this study are consistent with those of other studies, with a small change due to differences in study design.

CONCLUSION

Pouch fixation of orchiopexy in undescended testis provides adequate scrotal fixation, prevents recurrent torsion of the testis and spermatic cord,

ascend of testis and increase the patient's parent's compliance with minimal trauma to the testis.

LIMITATIONS & RECOMMENDATION

The surgical procedure was performed by different surgeons and the short duration of follow-up could affect the outcome result of the study. It is recommended to perform the study in a large group of participants and reassure its sustainability. The long-term follow-up may give more precise data and more significance to the study.

REFERENCES

- Hutson, J. M. (2006). Undescended testis, torsion, and varicocele. In *Pediatric surgery* (pp. 1193-1214). Mosby.
- Hurtson, J. M. (1985). A biphasic model for the hormonal control of testicular descent. *Lancet*, 2, 419-421.
- Adesanya, O. A., Ademuyiwa, A. O., Bode, C. O., & Adeyomoye, A. A. (2013). Diagnostic value of high resolution ultrasound in localisation of the undescended testis in children. *African Journal of Paediatric Surgery*, 10(2), 127.
- Deltamedix.com. 2020. Delta Medix Scranton Doctors. [online] Available at: <http://www.deltamedix.com/urology/urology_location.php> [Accessed 25 July 2018].
- Niedzielski, J. K., Oszukowska, E., & Słowikowska-Hilczer, J. (2016). Undescended testis—current trends and guidelines: a review of the literature. *Archives of medical science: AMS*, 12(3), 667-677.
- Schneuer, F. J., Holland, A. J., Pereira, G., Jamieson, S., Bower, C., & Nassar, N. (2016). Age at surgery and outcomes of an undescended testis. *Pediatrics*, 137(2).
- Ghnnam, W. M., Saed, B., & Ghazy, H. (2011). A modified technique for scrotal fixation during orchiopexy. *African Journal of Paediatric Surgery*, 8(2), 203.
- Tseng, C. S., Huang, K. H., Pu, Y. S., & Chiang, I. N. (2016). Volume alteration of undescended testes: Before and after orchiopexy. *Urological Science*, 27(3), 161-165.
- van der Plas, E. M., Zijp, G. W., Froeling, F. M., van der Voort-Doedens, L. M., Meij-de Vries, A., Goede, J., & Hack, W. W. (2013). Long-term testicular volume after orchiopexy at diagnosis of acquired undescended testis. *The Journal of urology*, 190(1), 257-262.
- Jahid Boksh, S. K. (2006). Results and discussion in Operative validation of ultrasonographic finding in case of the non-palpable testis (Thesis). Bangladesh institute of child health under Dhaka University.