

## Infective Endocarditis Complicated by Fistulized Pseudoaneurysm in the Left Ventricle: Case Report

Marwan El Qady<sup>1\*</sup>, Fongnikin Ismael Gildas Ganse<sup>1</sup>, Tibou Camara<sup>1</sup>, Dicko Arafaou<sup>2</sup>, Drissi Boumzebra<sup>2</sup>, Saloua El Karimi<sup>1</sup>, Mustapha El Hattouai<sup>1</sup>

<sup>1</sup>Department of Cardiology, Mohammed VI University Hospital, Marrakesh, Morocco

<sup>2</sup>Department of Cardiovascular Surgery, Mohammed VI University Hospital, Marrakesh, Morocco

DOI: [10.36347/sjmcr.2022.v10i04.023](https://doi.org/10.36347/sjmcr.2022.v10i04.023)

| Received: 13.03.2022 | Accepted: 18.04.2022 | Published: 21.04.2022

\*Corresponding author: Marwan El Qady

Department of Cardiology, Mohammed VI University Hospital, Marrakesh, Morocco

### Abstract

### Case Report

This is a case report of a 39-year-old patient with a history of recurrent angina since her childhood, who was diagnosed with an endocarditis complicated by pseudoaneurysm. The pseudoaneurysm is a rare complication. We report the case of a pseudo aneurysm of the right coronary sinus fistulized into the left ventricle complicating a surgically treated aortic infective endocarditis.

**Keywords:** Infective endocarditis, pseudoaneurysm, complications.

**Copyright © 2022 The Author(s):** This is an open-access article distributed under the terms of the Creative Commons Attribution 4.0 International License (CC BY-NC 4.0) which permits unrestricted use, distribution, and reproduction in any medium for non-commercial use provided the original author and source are credited.

## INTRODUCTION

Perivalvular extension of infective endocarditis is a frequent cause of uncontrolled infection and is responsible for a worse prognosis. Surgical intervention is often required. Perivalvular complications of infective endocarditis include abscess formation, pseudoaneurysm or fistula. We report the case of a pseudo aneurysm of the right coronary sinus fistulized into the left ventricle complicating a surgically treated aortic infective endocarditis.

## CASE PRESENTATION

A 39-year-old patient with a history of recurrent angina since her childhood, without any cardiovascular risk factor, was referred for complementary management of an infective endocarditis not controlled by a medical treatment well conducted.

The interrogation allowed to find the notion of a fever not quantified accompanied by an asthenia evolving one month before his hospitalization. Progressively, dyspnea appeared, first for sustained efforts and then, at the slightest effort.

The physical examination: notes a weight loss of 9 kg, a temperature of 38.5 C, a tachycardia of 109bpm, a blood pressure of 130/40mmhg. There is a diastolic murmur of aortic insufficiency, there is no sign

of right or left heart failure. The rest of the examinations, in particular ENT, didn't find any portal of entry.

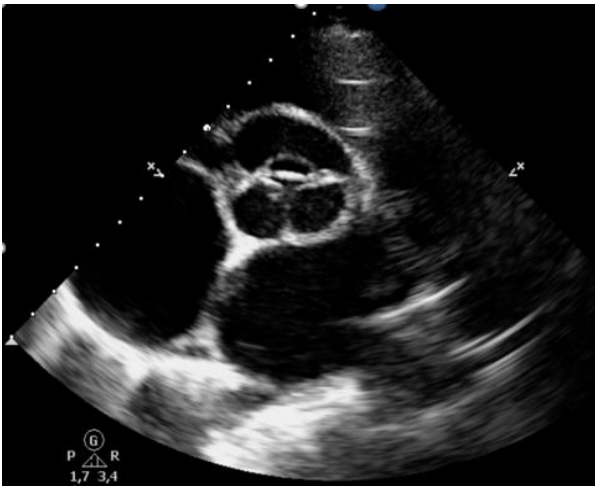The chest X-ray: visualizes a normal parenchyma, no cardiomegaly, free air sacs.

The biology test showed an inflammatory syndrome with a CRP level 145.2mg/l, leukocytes level 16810/mm<sup>3</sup> and this was observed despite 15 days of probabilistic bi-antibiotic therapy followed by 16 days monotherapy with ceftriaxone. The echocardiogram completed by a TOE (Figure 3).

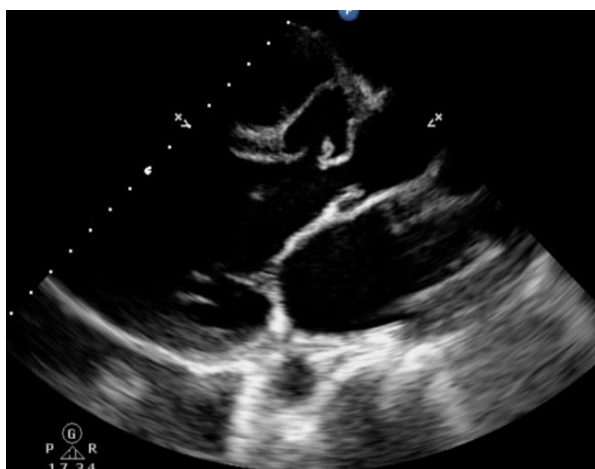Reveals a tricuspid and remodelled aortic valve, presence of a pseudoaneurysm (measuring 28x20mm) at the level of the antero-right coronary sinus ruptured in the LV (Figure 1 and 2) and a vegetation of 14mm of large axis on the antero-right cusp (Figure 1). A prolapse of the right antero-cusp (Figure 3) caused a severe aortic insufficiency; The mitral valve is little remodelled and causes a severe mitral insufficiency.

The patient was referred to the surgeon for a double mitral and aortic valve replacement by mechanical prosthesis and a cure of the aneurysm.

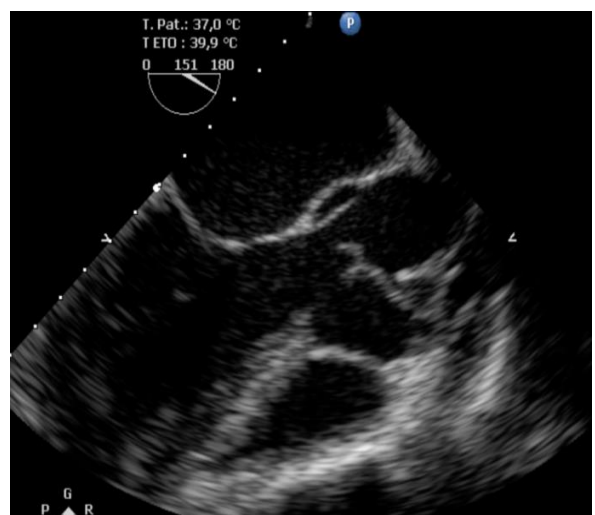The postoperative course was simple with clinical and biological improvement under bi-antibiotic therapy.



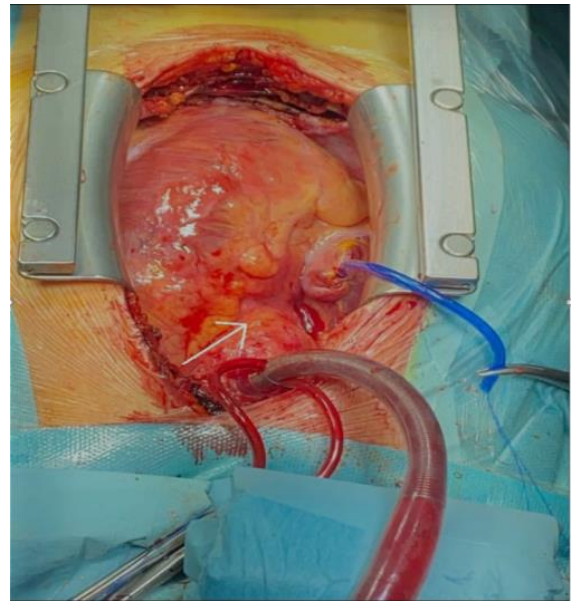
**Figure 1: TTE Short Axis Parasternal Section: Visualization of pseudoaneurysm**



**Figure 2: TTE Parasternal long axis view: showing a huge pseudo aneurysm of the coronary sinus and an image of vegetation on the right antero cusp**



**Figure 3: TOE: visualization of the pseudo aneurysm**



**Figure 4: Bulge of the aortic root (white arrow) corresponding to the site of the pseudo aneurysm**

## DISCUSSION

Infective endocarditis (IE) is characterized by ulcerative lesions related to the transplplantation of a microorganism, most often bacterial, onto the valvular endocardium, much less the parietal endocardium.

Perivalvular complications include abscess formation, pseudoaneurysm or fistula (Anguera *et al.*, 2006). Pseudoaneurysms and fistulas are rare (1-2%) but severe complications of IE, which are often associated with very extensive valvular and perivalvular damage (Anguera *et al.*, 2005).

Pseudoaneurysms of the sinus of Valsalva affect in 80% the right coronary sinus, followed in frequency by the non-coronary sinus (16%) and the left coronary sinus (4%) (Chu *et al.*, 1990). Our patient presented with a pseudoaneurysm extending from the chasse chamber to the sino-tubular junction.

A perivalvular extension should be suspected in case of unexplained persistent fever or new atrioventricular block. An electrocardiogram should therefore be performed frequently during treatment of AR, especially in aortic AR.

Transoesophageal echocardiography, CT and PET scans are particularly useful for the diagnosis of perivalvular complications, while the sensitivity of transthoracic echocardiography is less than 50% (Camm, Lüscher, & Serruys, 2009).

The best time for surgical intervention in case of persistent infection is not clear. Surgical intervention is recommended as soon as possible. Rarely, if there is no other surgical indication, and if fever is controlled with antibiotic treatment, small abscesses or false

aneurysms can be treated medically, with close clinical and cardiographic monitoring (Leontyev *et al.*, 2016).

In hospital, the mortality rate when surgery is performed is around 20%, and the medium-term results are favourable with a 5-year survival rate of between 50 and 60% (Graupner *et al.*, 2002).

Surgery should systematically be considered in cases of complicated IE despite the technical difficulties of the operation, since it offers the best prognosis.

## CONCLUSION

This case illustrates the management of a rare complication of infective endocarditis.

## REFERENCES

- Anguera, I., Miro, J. M., Evangelista, A., Cabell, C. H., San Roman, J. A., Vilacosta, I., ... Corey, G. R. (2006). Periannular Complications in Infective Endocarditis Involving Native Aortic Valves. *The American Journal of Cardiology*, 98, 1254–1260.
- Anguera, I., Miro, J. M., Vilacosta, I., Almirante, B., Anguita, M., Muñoz, P., ... Guma, J. R. (2005). Aorto-cavitary fistulous tract formation in infective endocarditis: Clinical and echocardiographic features of 76 cases and risk factors for mortality. *European Heart Journal*, 26, 288–297.
- Camm, A. J., Lüscher, T. F., & Serruys, P. W. (Eds.). (2009). *The ESC Textbook of Cardiovascular Medicine* (2nd ed.). Oxford University Press.
- Chu, S. H., Hung, C. R., How, S. S., Chang, H., Wang, S. S., Tsai, C. H., ... Lee, Y. T. (1990). Ruptured aneurysms of the sinus of Valsalva in Oriental patients. *The Journal of Thoracic and Cardiovascular Surgery*, 99, 288–298.
- Graupner, C., Vilacosta, I., SanRomán, J., Ronderos, R., Sarriá, C., Fernández, C., ... Pinto, A. G. (2002). Periannular extension of infective endocarditis. *Journal of the American College of Cardiology*, 39, 1204–1211.
- Leontyev, S., Davierwala, P. M., Krögh, G., Feder, S., Oberbach, A., Bakhtiary, F., ... Mohr, F. W. (2016). Early and late outcomes of complex aortic root surgery in patients with aortic root abscesses. *European Journal of Cardio-Thoracic Surgery*, 49, 447–455.