

Bilateral Anterior Scleritis from a Bacterial Origin: About One CaseM. Aachak^{1*}, I. Jeddou¹, H. Boui¹, H. Brarou¹, T. Abdellaoui¹, F. El Asri¹, Y. Mouzarii¹, K. Reda¹, A. Oubaaz¹¹Department of Ophthalmology, Military Hospital, Mohammed V University, Rabat, MoroccoDOI: [10.36347/sasjs.2022.v08i04.010](https://doi.org/10.36347/sasjs.2022.v08i04.010)

| Received: 09.03.2022 | Accepted: 16.04.2022 | Published: 23.04.2022

*Corresponding author: M. Aachak

Department of Ophthalmology, Military hospital, Mohammed V University, Rabat, Morocco

Medical Image

Copyright © 2022 The Author(s): This is an open-access article distributed under the terms of the Creative Commons Attribution 4.0 International License (CC BY-NC 4.0) which permits unrestricted use, distribution, and reproduction in any medium for non-commercial use provided the original author and source are credited.

A 35-year-old patient with no notable history presented to the ophthalmology clinic for bilateral ocular redness with intense photophobia and a gritty sensation in the eyes; evolving in a context of fever at 102.2°F with a preserved general condition. Visual acuity was 20/20 without optical correction in both eyes. Slit-lamp examination showed a diffuse bulbar conjunctival injection with bilateral diffuse non-necrotizing anterior scleritis (fig 1), anterior segment and fundus examination was without abnormalities. Given the context of the current pandemic, a COVID 19-PCR was carried out which came back negative. The biological assessment revealed an important inflammatory syndrome with hyperleukocytosis at 18000/ml and a C-reactive protein at 170mg/l. Procalcitonin was positive in favour of a bacterial

infection. The etiological assessment showed a group B streptococcus bacterial urinary infection sensitive to third-generation cephalosporins. Treatment was based on intravenous *ceftriaxone* 2 grammes per day for 5 days, relayed 48 hours after apyrexia, by *Cefixime* per os for 10 days. Evolution was marked by regression of ocular redness and full recovery 12 days after starting treatment (fig 2).

Scleritis is an inflammation of the sclera, the outer layer of the globe. Although the majority of cases of scleritis are due to an autoimmune aetiology, approximately 5-10% of cases are infectious. [1] Untreated; infectious scleritis can lead to loss of the eye due to the spread of infection to surrounding structures or perforation of the eyeball [2].

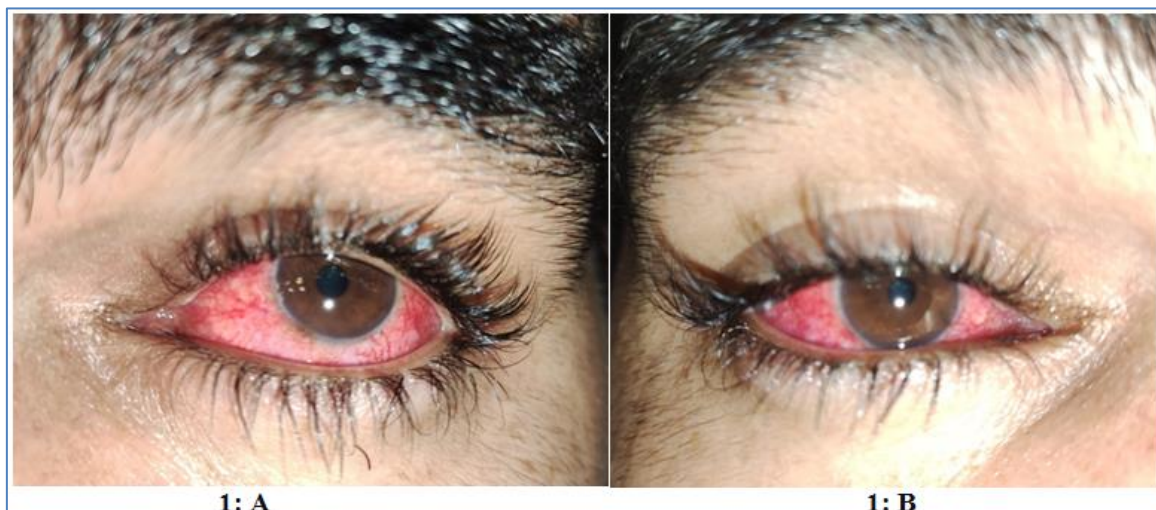


Fig-1: (a) Patient's left eye at admission: diffuse bulbar conjunctival injection with bilateral diffuse non-necrotizing anterior scleritis (b) right eye

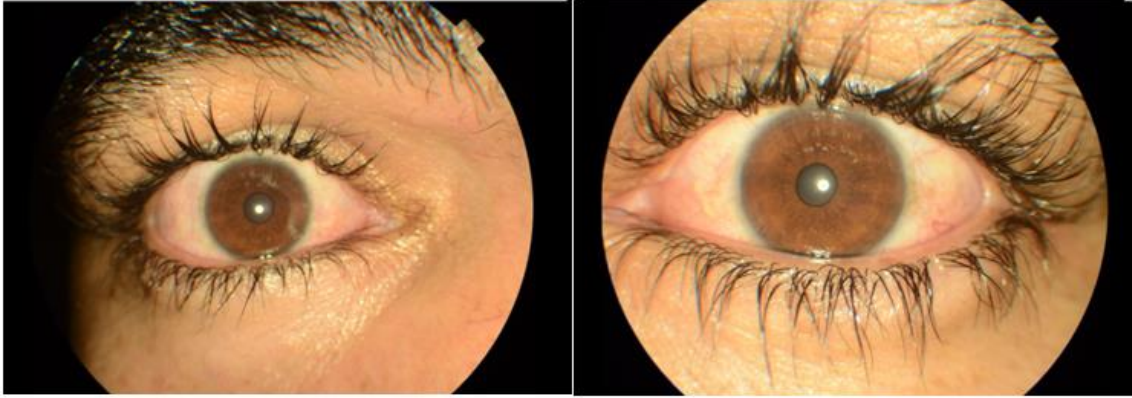

Fig-2: Appearance of the eyes after the treatment

REFERENCE

1. Leal, C., Le Roux, K., Rahmi, A., Varron, L., Broussolle, C., Denis, P., ... & Seve, P. (2013). Scleritis, clinical features, etiologies and treatment: a case series of 32 patients. *La Revue de Medecine Interne*, 35(8), 491-497.
2. Héron, E., & Bourcier, T. (2017). Sclérites et épisclérites. *Journal Français d'Ophtalmologie*, 40(8), 681-695.