

A Large Pseudoaneurysm Revealing Post Traumatic Common Carotid-Jugular Fistula: A Case Report

Macédoine Nijimbere^{1*}, Issaka Zalle¹, Yves Marien Mpira¹, Zouizra Zahira¹, Drissi Boumzebra¹

¹Cardiovascular Department, Mohammed VI University Hospital Morocco

DOI: [10.36347/sasjs.2022.v08i04.012](https://doi.org/10.36347/sasjs.2022.v08i04.012)

| Received: 17.03.2022 | Accepted: 21.04.2022 | Published: 30.04.2022

*Corresponding author: Macédoine Nijimbere

Cardiovascular Surgery Department, Mohammed VI University Hospital, Marrakech, Morocco

Abstract

Case Report

Traumatic common carotid artery-jugular vein fistulas are rare. The treatment requires direct closure of the fistula or occlusion of the carotid artery above and below the fistula, by a surgical or endovascular approach. A 21-year man presented with a left-sided pulsatile neck swelling 9 months following a stab wound. Neck computed tomography demonstrated a vascular mass protruding into the anterior neck. The direct closure of jugular vein and common carotid defect was performed. The common carotid-jugular vein fistula and dilatation of the jugular vein disappeared and the parent artery and vein were preserved.

Key words: Common carotid-jugular vein fistula, Pseudoaneurysm, Surgical management.

Copyright © 2022 The Author(s): This is an open-access article distributed under the terms of the Creative Commons Attribution 4.0 International License (CC BY-NC 4.0) which permits unrestricted use, distribution, and reproduction in any medium for non-commercial use provided the original author and source are credited.

INTRODUCTION

Post-traumatic arterio-venous fistula between the carotid artery and the jugular vein is a rare entity representing 4% to 7% [1, 2]. It is caused by penetrating injury or by internal jugular venous cannulation, and may remain untreated for months or years after the initial injury [2]. Signs and symptoms of an arteriovenous fistula include pulsatile neck swelling, systolic murmur, palpable thrill, and dilated superficial veins [3]. Treatment of carotid artery-to-jugular vein fistulas requires direct closure of the fistula or occlusion of the carotid artery above and below the level of the fistula, by a surgical or endovascular approach [4].

CASE REPORT

A 21-year-old man presented with a palpable thrill over a swelling in the left lateral cervical region. The patient had suffered a stab injury 9 months prior and had no symptoms until he noticed a cervical swelling a month ago. Clinical examination revealed an old, small scar on the inferior left side of the neck and a palpable soft swelling with continuous thrill and systolic murmure. The cardiac examination was normal. No ECG and chest radiography signs (Figure 1). Doppler ultrasound of the supraortic trunks revealed a lateral sacciform aneurysm and an anteromedial fistulous path communicating with the internal jugular vein.

Neck computer tomography angiography revealed large arterio venous fistula of 1.5 cm in length, between the left common carotid artery and the left internal jugular vein associated with carotid pseudoaneurysm. Open surgery was performed under general anesthesia via a longitudinal neck incision anterior to the sternocleidomastoid muscle. The exploration found a dilated internal jugular vein, tense, with a very thin wall measuring 3cm covering the anterior wall of the common carotid artery (Figure 2). After laborious dissection of the jugular vein and control with loops, we were able to expose the carotid artery which was controlled upstream and downstream. The heparin was administered and the carotid artery clamped. Communication between the common carotid artery and jugular vein was confirmed to be due to a 1.5 cm diameter fistulous tract, with venous opening localized in the posterior wall of the jugular vein (Figure 3). The fistulous track was divided revealing a longitudinal defect of 1.5 cm in the long axis. The defects in the common carotid artery and in the internal jugular vein were repaired by direct and discontinuous sutures with 6-0 prolene. The thrill disappeared upon palpation of the jugular vein and the dilatation vein regressed spontaneously (Figure 4). The patient tolerated the procedure well. Postoperative anticoagulation with heparin and salicylic acid was started in day 1 and continued for 1 month.

Citation: Macédoine Nijimbere, Issaka Zalle, Yves Marien Mpira, Zouizra Zahira, Drissi Boumzebra. A Large Pseudoaneurysm Revealing Post Traumatic Common Carotid-Jugular Fistula: A Case Report. SAS J Surg, 2022 Apr 8(4): 336-339.

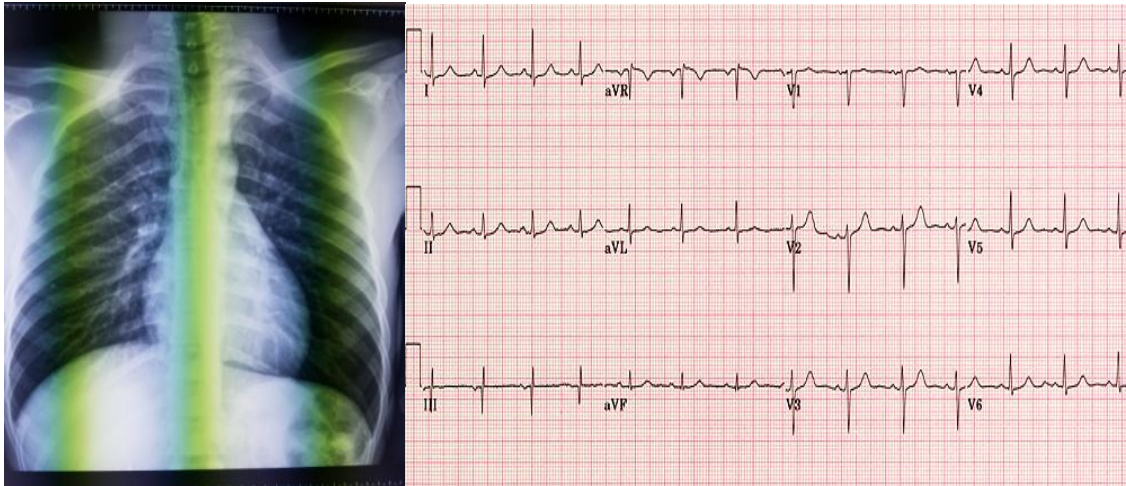


Figure 1: Chest radiography and electrocardiography

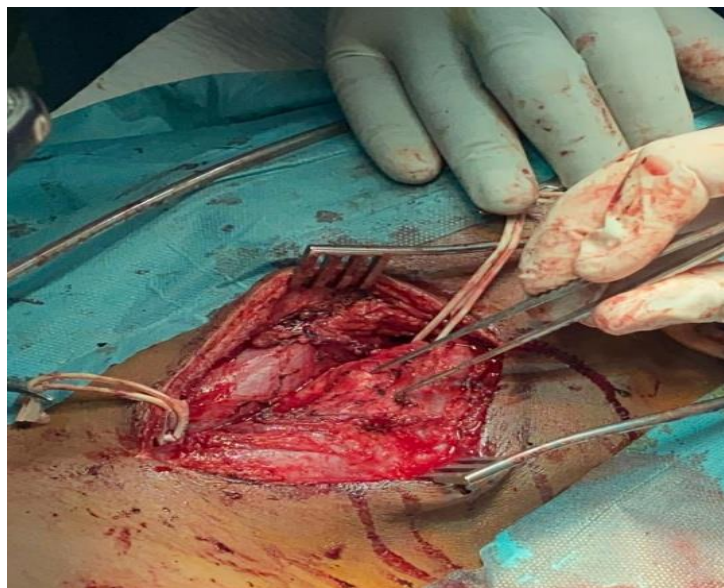


Figure 2: Dilated jugular vein

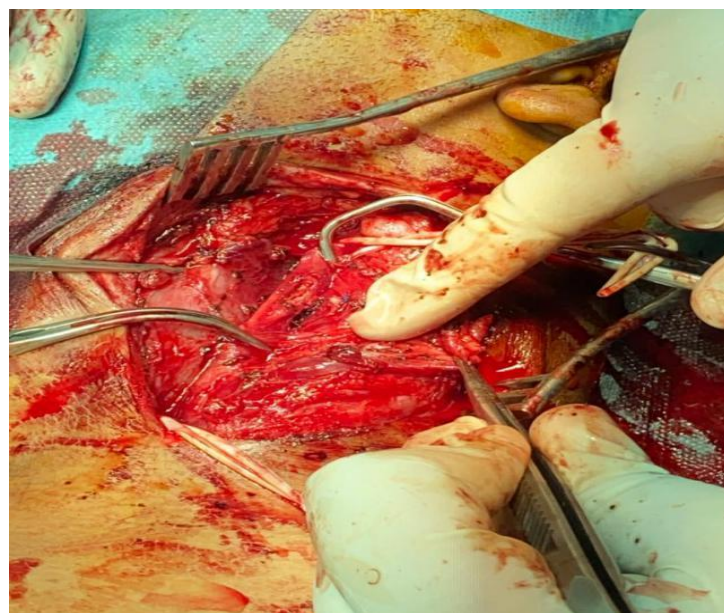


Figure 3: Carotid artery defect

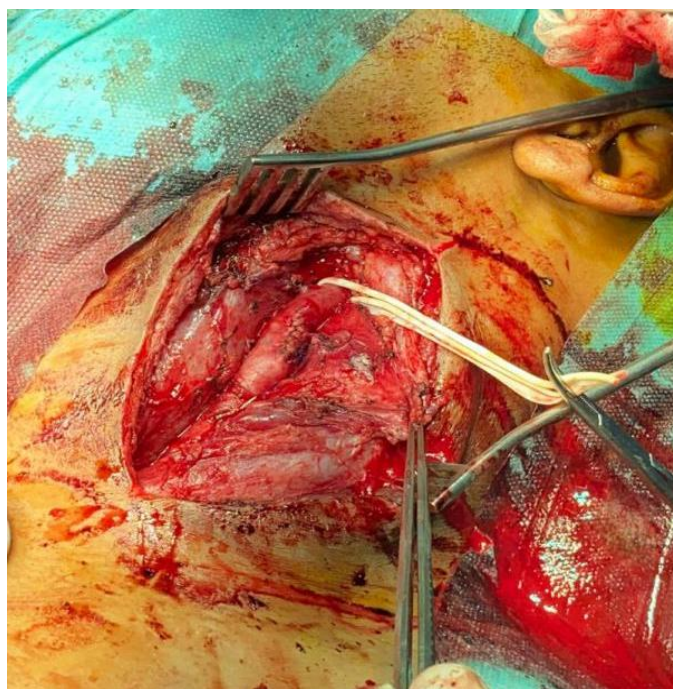


Figure 4: After the carotid and vein defect closure

DISCUSSION

Post-traumatic carotid-jugular arteriovenous fistula represents less than 4% of all vascular lesions in this region [5]. A penetrating injury such as a stabbing or gunshot wound is the usual mechanism, but occasionally a closed injury of the neck may be responsible [6]. The mechanism of stabbing aggression mentioned in the literature is the same found in our patient. The main complaints of patients with arteriovenous fistula are a noise synchronous with the arterial pulse. Physical signs are often a continuous murmur with systolic accentuation and the thrill on palpation. Patients with carotid artery fistula may have a decrease in the pulse when compression is applied on the carotid vessel [4]. These patients may also complain of headaches, fainting, visual and hearing disturbances, and hemiparesis. In our case, patient complained a swelling on his neck and main physical signs were thrill on palpation and systolic murmur on auscultation. This explains the late onset of complications. Depending on the size of the artery involved, its position relative to the arch of the aorta, and the size and duration of the fistula, cardiac decompensation may occur. The involved vessels cannot usually be identified before angiography. The most logical approach is to start with a digital subtraction angiogram which will reveal the fistula [4, 7]. By far the most commonly preferred imaging was CTA (60.5%), followed by MRI/MRA (22.8%), angiogram (15%), and Doppler (1.7%) [8]. For our patient, CTA and Doppler were sufficient to diagnose the fistula. A large-diameter (>8 mm) fistula leads to early high cardiac output failure [2]. In our patient, the fistula diameter was 15mm and its duration was 9 months. The young age and the absence of cardiovascular risk factors could delay the occurrence of complications, especially cardiac ones and it is for

that reason that some explorations including chest x-ray and ECG were normal. The approach to treatment of a carotid-jugular fistula should be endovascular or surgical is debatable, and this determination is still made on a case-by-case basis [2, 3]. However, the primary indications for surgery are a large fistula, an associated aneurysm, the presence of the fistula in zone II, and/or the involvement of other vessels [2]. These characteristic lesions were similar to those found in our patient and this was why the surgery was the preferred technique. Surgery for carotid-jugular fistula involves adequate exposure, vascular control, and direct vascular procedures. In the observation of Ndubueza Ezemb *et al.* [7], a longitudinal neck incision was made anterior to the sternocleidomastoid muscle and this approach was also performed in our case. Systemic heparin (5,000 IU) was administered to increase the international normalized ratio (INR) to 1.4. As our surgical technique, after exposure of the internal jugular vein, the right common carotid artery, and the internal and external carotid arteries, control of these vessels was achieved by use of slings and vascular clamps. The fistulous track was divided, and the openings in the common carotid artery and in the internal jugular vein were closed with direct and discontinuous sutures. The thrill disappeared upon palpation of the jugular vein after surgical management and patient was discharged on the third postoperative day. In the observation of Claudio Caldarelli *et al.* [3], the same technique was performed and the spontaneous disappearance of the thrill was also noticed.

CONCLUSION

Penetrating neck injuries should be carefully evaluated for arteriovenous fistula. A CT-scan must be systematically done to notice initial lesions and early

treatment of common carotid–jugular fistula is necessary in order to avoid associated complications such as cardiac failure.

REFERENCE

1. Dell'Amore, A., Castriota, F., Calvi, S., Magnano, D., Noera, G., & Lamarra, M. (2009). Post-traumatic Carotid–Jugular Arterio-venous Fistula. *Heart, Lung and Circulation*, 18(4), 293
2. Sinha, V. K., Yaduvanshi, A., Kataria, V., & Nair, M. (2019). Traumatic common carotid–internal jugular arteriovenous fistula manifesting as life-threatening epistaxis. *JACC: Case Reports*, 1(4), 576-578.
3. Caldarelli, C., Biricotti, M., Materazzi, G., Spinelli, C., & Spisni, R. (2013). Acquired carotid-jugular fistula: its changing history and management. *International Scholarly Research Notices*, 2013.
4. Ahn, J. Y., Chung, Y. S., Lee, B. H., Choi, S. W., & Kim, O. J. (2004). Stent-graft placement in a traumatic internal carotid-internal jugular fistula and pseudoaneurysm. *Journal of Clinical Neuroscience*, 11(6), 636-639.
5. Dammak, A., Jmaà, B., Hadhri, S., Cheikhrouhou, H., Dhouib, F., Haddar, S., ... & Frikha, I. (2017). Post-traumatic carotido-jugular fistula: Case report and review of the literature. *Journal de Medecine Vasculaire*, 42(6), 388-391.
6. Nandapalan, V., O'Sullivan, D. G., Siodlak, M., & Charters, P. (1995). Acute airway obstruction due to ruptured aneurysmal arterio–venous fistula: common carotid artery to internal jugular vein. *The Journal of Laryngology & Otology*, 109(6), 562-564.
7. Ezemba, N., Ekpe, E. E., Ezike, H. A., & Anyanwu, C. H. (2006). Traumatic common carotid—jugular fistula: report of 2 cases. *Texas Heart Institute Journal*, 33(1), 81.
8. Lee, T. S., Ducic, Y., Gordin, E., & Stroman, D. (2014). Management of carotid artery trauma. *Craniofacial Trauma & Reconstruction*, 7(3), 175-189.