

## Case Report of an Adrenocortical Carcinoma

M. Lazrak<sup>1\*</sup>, S. Benslimane<sup>1</sup>, A. Zerhouni<sup>1</sup>, T. Souiki<sup>1</sup>, K. Ibnmajdoub<sup>1</sup>, I. Toughrai<sup>1</sup>, K. Mazaz<sup>1</sup>

<sup>1</sup>Visceral Surgery Department of the Hassan II Hospital Center Fes, Morocco

DOI: [10.36347/sjmcr.2022.v10i06.013](https://doi.org/10.36347/sjmcr.2022.v10i06.013)

| Received: 26.04.2022 | Accepted: 02.06.2022 | Published: 09.06.2022

\*Corresponding author: M. Lazrak

Visceral Surgery Department of the Hassan II Hospital Center Fes, Morocco

### Abstract

### Case Report

Adrenocortical carcinoma is a primary malignant tumor developed at the expense of the adrenal cortex. It is a rare tumor (1 or 2 cases per million and per year), with two peaks of occurrence, in the first decade and between 40 and 50 years. The treatment is surgical whenever possible and aims at the complete resection of the tumour, the affected lymph nodes and any extra-adrenal lesions. Medical treatment is required in case of incomplete or impossible surgery or after surgery even when it is possibly complete (adjuvant treatment). If there is an excess of hormonal secretion (cortisol) a special treatment (Anticortisol) will be instituted. In the event of metastases, qualified or loco-regional treatments can be associated. We present the case of a 67-year-old patient, diabetic, with no particular clinical signs, in whom, during a routine radiological assessment, a large tumor was discovered fortuitously at the expense of the left adrenal which measures 8 cm in long axis. The biological assessment did not show any hormonal hypersecretion. The treatment had consisted of a surgical resection from the outset without postoperative complications. Postoperative hemodynamic control was satisfactory with a transfer to the endocrinology department on day 3 postoperatively.

**Keywords:** Adrenocortical carcinoma, Medical treatment, tumour, Anticortisol, hormonal hypersecretion.

Copyright © 2022 The Author(s): This is an open-access article distributed under the terms of the Creative Commons Attribution 4.0 International License (CC BY-NC 4.0) which permits unrestricted use, distribution, and reproduction in any medium for non-commercial use provided the original author and source are credited.

## INTRODUCTION

The fortuitous discovery of the adrenal mass must lead to an effective etiological investigation of the hypersecretion and then the malignancy. The clinic allows orientation and biology and imaging confirmation.

The Weiss score defines the malignancy of an adrenocortical tumor when it is greater than or equal to 3 [9]. Clinically, it is most often manifested by a Cushing's syndrome made of excess weight, hypertension and diabetes.

Biological confirmation is done by measuring plasma and urinary cortisol levels, with recourse to the dexamethasone braking test.

## CASE PRESENTATION

This is a 53-year-old patient who is followed in endocrinology for a well-balanced type 2 diabetes under treatment hypertensive under treatment, in whom an incidentaloma at the expense of the adrenal gland was discovered fortuitously during the etiological assessment of her hypertension left which is 8 CM.

Clinically the patient had blood pressure figures varying between 12 and 14 cmHg of systolic and 7 and 8 cmHg of diastolic, in good general condition WHO at 0, BMI at 23.4 without signs in favor of a Cushingoid syndrome.

On clinical examination, there was no palpable mass in the left hypochondrium or the left flank and there was no lumbar contact.

The biological assessment carried out showed an increase in cortisolemia, a negative dexamethasone braking test, and in particular no hypersecretion of methoxylated derivatives and no longer ionic disorders.

After a pre-anaesthetic visit that did not show any contraindications, the patient was admitted to the operating room.

Surgical exploration by left subcostal laparotomy revealed a tumor mass measuring 9cm, adherent to the left renal vein but without invasion. After ligation of the main adrenal vein, the dissection proved easy thereafter without tension disorders during the resection.

The postoperative course was uncomplicated and the patient was transferred to endocrinology for additional follow-up on day 3 postoperatively.

## DISCUSSION

Adrenocortical tumor is a rare cancer with a 5-year survival of less than 30% [1], its incidence is estimated at one or two cases per million inhabitants per year. Exceptionally occur in a congenital or family context, Wiedemann-Beckwith Syndrome, Li-Fraumeni Syndrome, more rarely MEN type 1, familial colonic polyposis [2].

The clinical manifestations of this tumor is secondary to hormonal hypersecretion, which results in a cushing syndrome, More specific symptoms such as symptoms of hypercatabolism:

- Muscular (proximal amyotrophy);
- Cutaneous (cutaneous fragility, bruising, stretch marks);
- Bone (osteoporosis).
- Slowing of height growth, particularly if associated with paradoxical weight gain, in children.
- Type 2 diabetes as part of a plurimetabolic or unbalanced syndrome with no obvious cause.
- Arterial hypertension in young or resistant subjects.

An atypical psychiatric picture or resistance to antidepressants usual. Any adrenal tumor of cortical origin discovered incidentally [3].

These tumors can be classified into 2 types, hypersecreting and non-hypersecreting adrenocortical tumors. Our patient was paucisymptomatic, with paroxysmal pain in the left hypochondrium, controlled hypertension under treatment without other signs.

Biologically, the assessment to be made is:

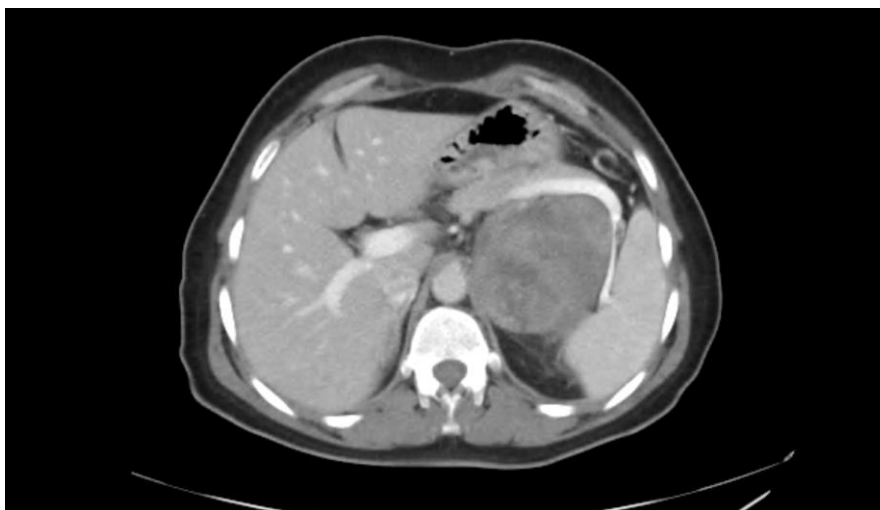- 2 to 3 measurements of cortisoluria for 24 hours with creatinine.
- A minute braking (dexamethasone 1 mg per os at midnight and dosage of plasma cortisol at 8 a.m. the next morning) (and/or saliva with referral to a specialized laboratory).
- 2 to 3 measurements of nocturnal salivary cortisol (typically at 24 hours) (sent to a specialized laboratory) [3].

In our case we objectified an increase in plasma cortisol which was at 78 ng/mL with a negative braking test.

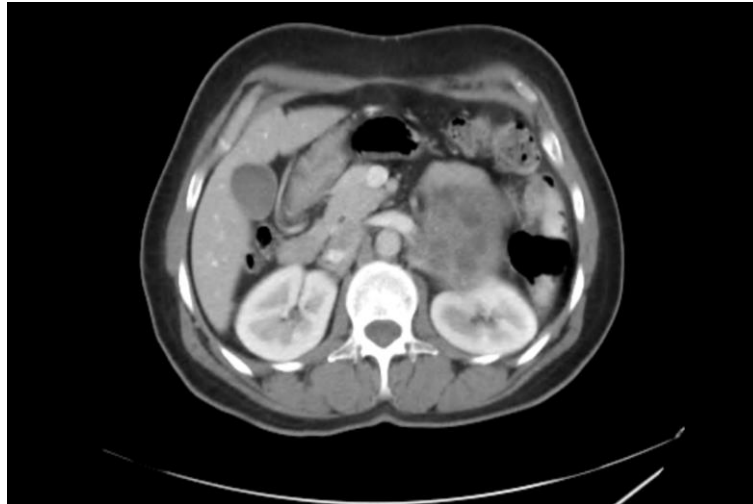CT is the essential examination [4] to specify the size, the heterogeneous character which is a sign of malignancy, calcifications, invasion either of the ipsilateral kidney or of the right vena cava and distant metastases in the event of an aggressive tumor. Adrenal scintigraphy is not essential.

The pet-scan is a very effective examination for distinguishing benign lesions from malignant lesions and it contributes to non-invasive imaging in the search for distant metastases which are sometimes silent and only revealed by this examination [5, 6].

The examination of first intention in our context is the CT scan, having objectified an adrenal tumor measuring 9cm which presents an intimate contact with the splenic artery and the left renal artery (Figure 1), it served us to eliminate the metastases and invasion of neighboring organs (Figure 2). An adrenal scan was done, showing left adrenal uptake. The pet scan was not performed.



**Figure 1: CT section showing an adrenal tumor in intimate contact with the splenic artery**

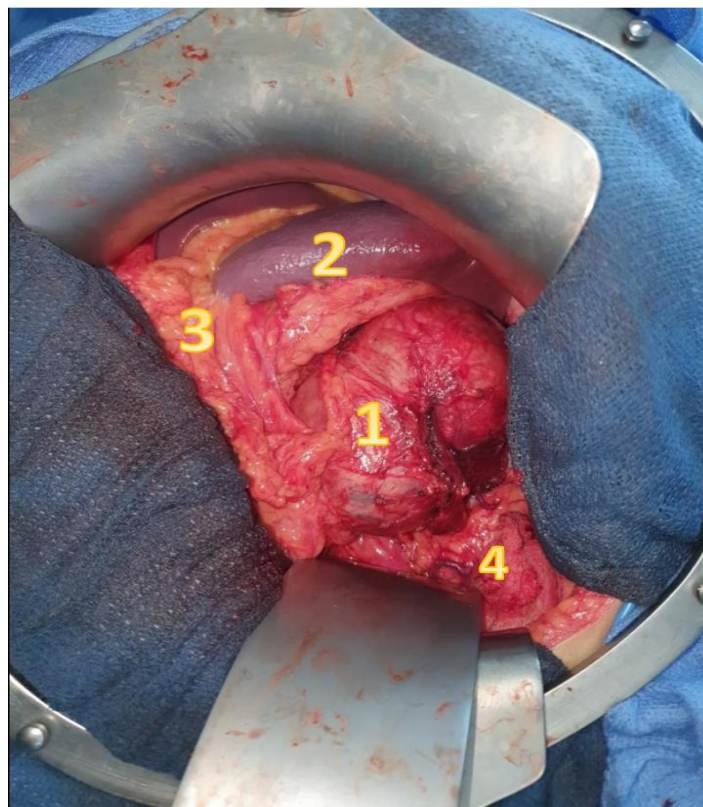


**Figure 2: CT couple showing intimate contact with the left renal artery**

The curative treatment for adrenal cortex is complete R0 excision by laparotomy [7]. Our surgical approach was a left subcostal laparotomy, a lowering of the left colic angle with a left coloparietal detachment were necessary for adrenal exposure (Figure 3).

The tumor mass had intimate contact with the left kidney, spleen, tail of the pancreas, but after primary ligation of the middle adrenal vein the dissection was uneventful. The mass was completely resected, R0, a drain was placed, removed on D2.

## Votre texte ici



**Figure 3: Intraoperative view showing the adrenal tumor (1) which has intimate relationships with: the spleen (2), the pancreas (3) and the left kidney (4)**

The patient was transferred to endocrinology on D3 for additional care. The pathological study of the specimen is essential to determine the nature of the tumor, the size of the tumor is an excellent predictor of

malignancy, so a WEISS score must always be established [8].

The anatomopathological study with an immunohistochemical study of the part of our resection showed an aspect in favor of a benign corticoadrenaloma with a WEISS score of 2.

The therapeutic follow-up was simple, with no early or late postoperative complications. The clinical and biological control at 1 month and at 3 months was satisfactory.

## CONCLUSION

Adrenocortical carcinoma is a primary malignant tumor developed at the expense of the adrenal cortex. CT is the reference examination for making the diagnosis and the biological is based on the serological and urinary dosage of the cortisol level.

The treatment is surgical whenever possible and aims at the complete resection of the tumour, which makes it possible to carry out a precise anapath study to establish a WEISS score.

## REFERENCES

1. Allolio, B., Hahner, S., Weismann, D., & Fassnacht, M. (2004). Management of adrenocortical carcinoma. *Clinical endocrinology*, 60(3), 273-287.
2. Libé, R., & Bertherat, J. (2005). Molecular genetics of adrenocortical tumours, from familial to sporadic diseases. *European Journal of Endocrinology*, 153(4), 477-487.
3. Syndrome de Cushing Protocole national de diagnostic et de soins; 7; haute autorité de santé – 2008.
4. Boland, G. W., Lee, M., Gazelle, G. S., Halpern, E. F., McNicholas, M. M., & Mueller, P. R. (1998). Characterization of adrenal masses using unenhanced CT: an analysis of the CT literature. *AJR. American journal of roentgenology*, 171(1), 201-204.
5. Becherer, A., Vierhapper, H., Pötzi, C., Karanikas, G., Kurtaran, A., Schmaljohann, J., ... & Kletter, K. (2001). FDG-PET in adrenocortical carcinoma. *Cancer Biotherapy and Radiopharmaceuticals*, 16(4), 289-295.
6. Leboulleux, S., Dromain, C., Bonniaud, G., Aupérin, A., Caillou, B., Lumbroso, J., ... & Schlumberger, M. (2006). Diagnostic and prognostic value of 18-fluorodeoxyglucose positron emission tomography in adrenocortical carcinoma: a prospective comparison with computed tomography. *The Journal of Clinical Endocrinology & Metabolism*, 91(3), 920-925.
7. Icard, P., Goudet, P., Charpenay, C., Andreassian, B., Carnaille, B., Chapuis, Y., ... & Proye, C. (2001). Adrenocortical carcinomas: surgical trends and results of a 253-patient series from the French Association of Endocrine Surgeons study group. *World journal of surgery*, 25(7), 891-897.
8. Weiss, L. M. (1984). Comparative histologic study of 43 metastasizing and nonmetastasizing adrenocortical tumors. *The American journal of surgical pathology*, 8(3), 163-169.
9. Chirurgie des glandes surrénales, Monographie AFC 113e congrès, 2011.