

What about Locoregional Anesthesia in Maxillofacial Emergencies?

Mabika Bredel Djeri Djor*, Saad Lahimiti, Garango Allaye, Aboulouidad Salma, El Bouihi Mohamed, Mansouri Nadia Hattab

Oral and Maxillo-facial Surgery Department, Faculty of Medicine and Pharmacy, Cadi Ayyad University, Marrakech, Morocco

DOI: [10.36347/SASJS.2019.v05i10.007](https://doi.org/10.36347/SASJS.2019.v05i10.007)

| Received: 21.09.2019 | Accepted: 28.09.2019 | Published: 30.10.2019

*Corresponding author: Mabika Bredel Djeri Djor

Abstract

Original Research Article

Background: The purpose of this study is to discuss the different methods of facial regional anesthesia and, to state our indications and the locoregional anesthetic technique in emergency maxillofacial trauma. **Materiel and methods:** Our study is retrospective during 9 months in the maxillofacial emergencies Unit in the University Hospital center of Marrakech, concerning a series of one thousand traumas that were subject to locoregional anesthesia. It has been practiced for suturing wounds and fractures correction. **Results:** The management of maxillofacial emergencies under locoregional anesthesia required the production of 349 supraorbital supra-orbital blocks, 176 infraorbital blocks, 76 mental blocks, 64 nasal blocks and 9 atrial blocks. **Conclusion:** Maxillofacial trauma is a common pathology. Locoregional anesthesia is a simple, fast, reproducible method and very important for the emergencies maxillofacial management.

Keywords: locoregional anesthesia, maxillofacial, emergency, wound, fracture.

Copyright © 2019: This is an open-access article distributed under the terms of the Creative Commons Attribution license which permits unrestricted use, distribution, and reproduction in any medium for non-commercial use (NonCommercial, or CC-BY-NC) provided the original author and source are credited.

INTRODUCTION

Maxillofacial trauma is a common condition mainly related to the high incidence of road accidents and assaults in our country. Locoregional anesthesia retains a key role in the management of these emergencies. Its simplicity and efficiency make it a technique of choice [1]. Its provides significant advantages for the surgeon because it eliminates the presence and cost of the anesthesiologist. Advantages for the patient are also present because it is possible to apply this anesthesia at any time, e.g., patient in a poor general health condition, and no need for fasting.

It is with this in mind, that we lead this study whose purpose is to discuss the different methods of facial regional anesthesia and, to state our indications and the locoregional anesthetic technique in emergency maxillofacial trauma.

PATIENTS AND METHODS

Type and Period of Study

A descriptive and cross sectional study with retrospective data collection, conducted in the department of Maxillofacial Emergencies of the Mohammed 6 Teaching Hospital of Marrakech, over a period of 9 months from January to September 2018.

Thousand (1000) patients presenting a maxillofacial emergency (the facial wounds and the facial fracture) repaired under locoregional anesthesia and / or local anesthesia, admitted to the emergency department and taken in charge by the maxillofacial surgery team were retained of study.

Variables Studied

The following variables have been studied: Age, sex, and the general and nutritional state, etiology of the trauma, topography of the lesion, type of the lesion, indication of treatment, type of treatment, type of anesthesia, duration of anesthesia, type of anesthesia technique, and type of complication.

RESULTS

Thousand patients were collected in this study. The average age of our patients was 27 years with extremes ranging from 11 years to 43 years, with a clear male predominance of 84%. The mechanism of the trauma was essentially a road accident (45%) or an assault (35%).

The types of lesions consisted mainly of wounds and loss of the face and auricular region, fractures of the bones of the nose, alveolodentary fractures, and mandibular fractures.

The topography of wounds was variable predominantly by frontal localization (35.6%) followed by sub-orbital (22%), palpebral (9.7%) and atrial (3.5%) localization, followed by other locations.

Therefore these facial wounds were distributed according to the territory of innervation of the branches of the trigeminal nerve: 45.9% of the wounds were in the territory of the ophthalmic nerve (V1), 28% in the territory of the maxillary (V2), 22.6% in the territory of the mandibular nerve (V3). 3.5% cases were in the mixed territory of the cervical plexus and auriculotemporal localization.

The bone lesions managed by locoregional anesthesia were divided between the alveolodentary fractures (33%), fracture of the bones of the nose (47%) and mandibular fractures (37%) treated with locoregional anesthesia respectively by mono-maxillary compression bow, endonasal reduction-contention and intermaxillary blockages.

94.3% of the wounds were repaired by simple suture and the rest by local plasties. The management of maxillofacial emergencies under locoregional anesthesia required the production of 349 supraorbital supra-orbital blocks, 176 infraorbital blocks and 76 mental blocks, 64 nasal blocks and 9 atrial blocks.

43% of wounds were repaired under local anesthesia and 57% by locoregional anesthesia or a combination of both. This was supraorbital block +/- supra-trochlear block in (60%), followed by infra-orbital blocks in 26% of cases and mentally in 11% of cases and 3% atrial.

The soft tissues were the most affected maxillofacial structure and most repaired under locoregional anesthesia and / or local anesthesia. In 92.7% of cases of facial wound and in 7.3% of cases of bone involvement.

The contribution of locoregional anesthesia was objectified by evaluating the comfort of the patient and the surgeon intraoperatively. A calm patient, a controlled hemostasis, ensured the comfort of the maxillofacial surgeon and a gesture thus facilitated. This comfort was reported in 75% of cases and considered moderate in 25%. The visual analogue scale evaluated the comfort of the patient. It was maximal in 85% of the cases, judged moderate by 11% of the patients, and supplemented by local infiltration. The gesture was painful in 4% of cases.

The occurrence of a few general incidents during the realization of the ALR, type of lipothymia in 10 patients, syncope in 5 patients and 2 convulsions in two epileptic patients. In the postoperative period, 5% of patients had spontaneous resolution hematoma and 3% residual edema. No case of motor deficit.

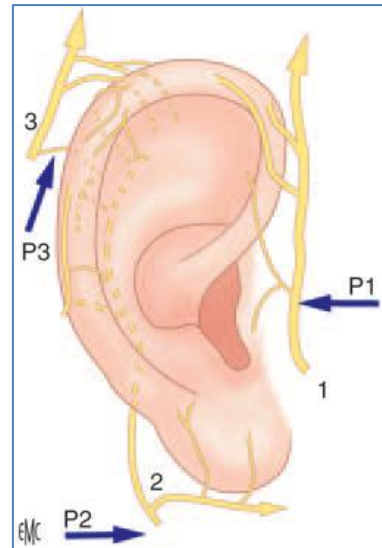


Fig-1: Ear blocks. P1: block of the auriculotemporal nerve (1); P2: block of the great auricular nerve (2); P3: C2 block (small occipital nerve, 3) [1]

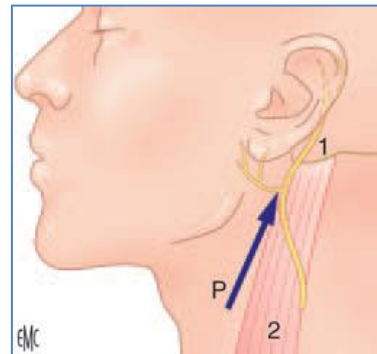


Fig-2: Block of the great auricular nerve. P: puncture. 1. mastoid; 2. Sternocleidomastoid [1]

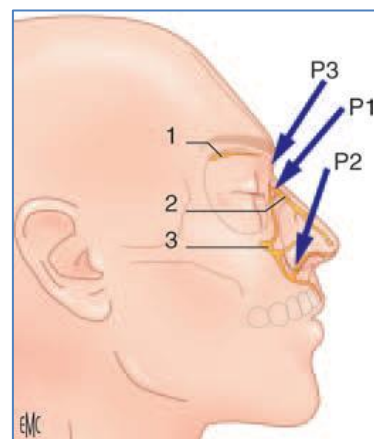


Fig-3: Block of the nasal nerve and nose. 1. Anterior ethmoidal nerve; 2. nasal nerve; 3. infraorbital nerve. P1: puncture at the origin of the external portion of the nasal nerve; P2: puncture in the nasolobar groove; P3: puncture at the root of the nose [1]

DISCUSSION

The maxillofacial emergencies in Marrakech are frequent and constitute about 10% of the surgical emergencies at the Mohammed 6 Teaching Hospital of Marrakech [2]. Locoregional anesthesia of the truncal block face is a simple, reliable method with very low

iatrogenic risk. In maxillofacial surgery, this technique seems to be a complement and not an alternative to local anesthesia. In fact, it allows the anesthesia of an extensive and deep territory with a low number of punctures and a high success rate [3]. However, the duration of the block at the level of the face does not exceed, in our hands, one hour. Therefore, the addition of a local anesthesia in addition to the locoregional anesthesia seems useful to us because the locoregional anesthesia makes it possible to make the injections of local anesthesia painless, whereas the addition of the local infiltration makes it possible to perpetuate the effect of locoregional anesthesia and add to it the advantage of local vasoconstriction.

There are blocks of the face accessible to no anesthesiologist, which we used. There are several methods of regional anesthesia available. Basically, we can divide regional anesthesia into main categories: the supra-orbital and supra-trochlear nerve blocks, infra-trochlear and nasal ethmoidal nerve block constituting the nasal block, the infraorbital block, the mental block, the auriculotemporal nerve block, the nerve great auricular and small occipital nerve made as part of a complete atrial block. They should be widely used and should supplant, in the emergency department, traditional infiltration anesthesia [4].

Their performance techniques are simple and must take into account the anatomy of facial sensitivity that is dependent on the trigeminal nerve and the superficial cervical plexus. To perform a complete anesthesia of the auricle of the ear for example, we associated three blocks: the block of the auriculotemporal nerve (2 ml), the block of the great auricular nerve (7 ml) and the block of the small occipital nerve or C2 (4 ml). Only the area of Ramsay-Hunt [5] escapes these blocks.

Technically our step of realization of the blocks were stereotyped

- Block of the auriculotemporal nerve (Figure 1.) [1].

The necessary material was an intradermal insulin needle (26 G). The point of puncture is in front of the tragus at 15 mm. The needle penetrates to 10 mm medially of this point, and goes horizontally towards the tragus; the injection is done right in front of it. The injection of 1 to 2 ml of anesthetic solution should be very slow, in a lateral direction. After the removal of the needle, a discreet massage promotes the diffusion of the product. The area concerned by this block includes the ear flag in its anterior zone, the external auditory canal and the temporal zone above the earlobe [6].

- Block of the small occipital nerve C2 (Figure 1) [1].

The small occipital nerve is a terminal branch of the superficial cervical plexus that protrudes behind the sternocleidomastoid muscle and goes to the

posterior superior part of the earlobe where it gives branches, then will end in the lateral occipital zone of the skull. The point of puncture is behind the pavilion of the ear at its mid-height occipital zone.

The needle will allow the injection of local anesthetic in a quarter of a circular arc (typically from "9 am to 12 am") to complete the injection at the top of the auricle (Figure 1. A technical device can facilitate the block: the needle is slightly curved and can in one way inject the anesthetic solution behind the pavilion of the ear, parallel to this one. This block gives an anesthetized territory to the auricle of the ear, in its posterior and superior zone ("from 9 o'clock to 12 o'clock") where branches of this nerve participate in the sensibility of the lobe [7.]. In emergency, this block is useful in scalp wounds in the occipital zone.

- Block of the great auricular nerve (Figure 2) [1].

The patient should be installed with the head turned away from the block [8]. The first mark is the lower part of the mastoid (mark it in the felt); the second marker is the lateral edge of the sternocleidomastoid muscle at the cricoid cartilage. The block is on the line joining these two points. The puncture site is 10 mm outside (laterally) from the lateral edge of the sternocleidomastoid muscle. The needle goes sub-dermal and goes to the mastoid. The injection is done throughout the. The injection is very slow, with 7 ml of anesthetic solution, advancing to the mastoid. After the removal of the needle, a discreet massage promotes the diffusion of the product. It is necessary to privilege the volume to reach all the branches of this nerve. Anesthesia of the auricle of the ear, in its inferior and posterior zone (lower half) is obtained, as well as of a small cutaneous territory of the angle of the jaw.

- Block for the nose (Figure.3) [1].

The association of two bilateral blocks anesthetized the nasal integuments: infraorbital block and nasal block. Simple bone surgery such as nasal fracture reduction is practicable with this block, which is very interesting in emergency (association of the supratrochlear block and the nasal block in bilateral realization), is appropriate [9].

For nasal blockage, we use the extra-orbital technique. It imposes itself by its obvious simplicity [8], its safety and its effectiveness [10], with a high benefit-risk ratio. The operator places himself in front of the patient and traces two points of puncture where the injections are made:

- A first at the root of the nose, facing the internal angle of the eye, followed by infiltration, closer to the nasal bone, pricking near the edge of the nose towards the base of the last,

- Another in the nasal furrow, with an injection from the back of the nose to the cheek-nose limit.

The injection should be particularly slow because a little painful: 1 ml on the first site and 1.5 ml of anesthetic solution on the second site. After the removal of the needle, a discreet massage promotes the diffusion of the product. The anesthetized area involves the nasal bone, the bridge of the nose, the lateral part of the tip of the nose, the nasolobar groove. The root of the nose requires in addition a block of supra trochlear nerve.

These blocks were effective in the context of a broken nose or nasal wounds. The general anesthesia keeps very precise indications in particular, in the child, in front of a very important decay, an extended dermabrasion, and open fractures or in front of a general state not allowing the realization of the locoregional anesthesia.

The ideal method of suturing a wound should be painless but also quick, easy to perform, safe, with few complications and a satisfactory aesthetic and psychological rendering [4]. In addition, the truncal anesthesia of the face is of a real comfort for the patient and the practitioner [3].

To assess the comfort of the patient, and therefore the overall quality of anesthesia of the face during the management of maxillofacial trauma, a self-evaluative scale evaluates pain at the time of truncal anesthesia and during the therapeutic gesture since the verbal contact is kept with the patient throughout the procedure. The Visual Analogue Scale (EVA) is the most widely used and described scale in this field.

In case of block considered ineffective, the physician operator indicated the possible need for another anesthetic mode, including a recovery of local anesthesia banks [10]. In Guerin's study [11], the success of face blocks was 93%. Whereas in the Pasca J. study [12], we find a truncular block success rate of 72%. The reasons for the failures most mentioned in the literature are: the inappropriate topography of the block with respect to the wound which requires knowing perfectly the territories of innervation of the blocked nerves, the non-cooperating patients, the lack of training of the operator, the insufficient amount of local anesthetic compared to the recommendations.

When absolute and relative contraindications are correctly assessed, serious complications during peripheral locoregional anesthesia are rare. Lipothymia and vagal syncope are the most common complication during local anesthesia or locoregional anesthesia. All anesthetic agents are capable of inducing convulsive accidents related to central nervous toxicity.

The main indications of locoregional anesthesia in emergency are justified by the desire to avoid the risks of general anesthesia and the disadvantages of local anesthesia. The locoregional anesthesia makes it possible to overcome the organizational problems related to the emergency (duration of the preoperative phase not always known with certainty, order of the patients permanently modified because of the more or less urgent character of the intervention, late liberation of the operating rooms ...) [13].

Among the other advantages of locoregional anesthesia, one can evoke the probable reduction of post-traumatic stress and the prevention of the chronicization of pain by a powerful antalgic action [13]. In addition to some patients, these blocks have a place of choice (elderly, insufficient respiratory or fragile, diabetic ...) and represent 3% of our patients. Another important fact, the locoregional anesthesia allows ambulatory care of all patients.

In addition, the equipment used for the realization of the locoregional anesthesia of the face is the same as that required for the local anesthesia by infiltration, so there is no additional cost and new materials to be put in place at the level of the services of emergency room [14].

The risk of failure is the main disadvantage of ALR in emergency [13]. To remedy this, a good training in the realization of the locoregional anesthesia is necessary. Indeed, the practice of locoregional anesthesia techniques by non-anesthetise intensive care physicians, in the specific context of emergency medicine, can be conceived, provided that it is carried out in compliance with universal regulations and recommendation after having benefited from a recognized theoretical and practical training [14,15]. In our study, the blocks were made by the residents of maxillofacial surgery in emergencies, previously trained for the locoregional anesthesia. Truncular anesthesia of the face is still very little practiced in adults in emergencies. This is why we decided to carry out here a simple, non-comparative study to highlight clear and elementary objectives, thus demonstrating the effectiveness of locoregional anesthesia, its safety and ease of use.

CONCLUSION

Maxillofacial trauma is a common pathology. Locoregional anesthesia is a simple, fast, reproducible method with a high success rate is therefore the permissive technical means of choice in the management of emergencies of the face provided you know the indications and non-indications.

DECLARATIONS

Authors' contributions

All authors made substantial contributions to conception and design of the study and performed data analysis and interpretation

Conflicts of Interest

All authors declared that there are no conflicts of interest.

Financial support and sponsorship

None

Ethical approval and consent to participate

"Not applicable."

Consent for publication

"Not applicable."

REFERENCES

1. Pulcini A, Guerin JP, Sibon S, Balaguer T, Ichai C. Blocchi del viso. EMC-Anestesia-Rianimazione. 2007 Jan 1;12(4):1-4.
2. Hattab NM, Lahmiti S, El Bouihi M, Hiroual A, Bouaichi A, Fikry T. Plaies faciales: étude épidémiologique de 850 cas. Revue de Stomatologie et de Chirurgie Maxillo-faciale. 2011 Jun 1;112(3):135-8.
3. Lefort H, Lacroix G, Cordier A, Bey E, Duhamel P. Anesthésies locorégionales de la face: principes et précautions. In Annales de chirurgie plastique esthétique 2009 Dec 1. Elsevier Masson. 54(6): 577-581
4. Gilles P. Prise-en-charge des plaies aux urgences. In Société Francophone de médecine d'Urgence Conférence de Consensus. 2005; 12: 1-22.
5. Moore KL, Dallay AE. *Anatomie médicale*. Paris, Bruxelles : De Boeck université. 2001 857-61, 922-3, 951.
6. Péri G, Mondié JM. Blocs nerveux de l'extrémité céphalique. In: Dalens B, editor. *Anesthésie locorégionale de la naissance à l'âge adulte*. Paris: Pradel. 1993: 401-70.
7. Salam GA. Regional anesthesia for office procedures: part I, head and neck surgeries. *Am FAM Physician*. 2004;69:585-90
8. Zide BM, Swift R. How to block and tackle the face. *Plastic and reconstructive surgery*. 1998 Mar;101(3):840-51.
9. Mollieux S, Navez M, Baylot D, Prades JM, Elkhoury Z, Auboyer C. Regional anaesthesia for outpatient nasal surgery. *British journal of anaesthesia*. 1996 Jan 1;76(1):151-3.
10. Deleuze A, Gentili ME, Vial G. Anesthésie locorégionale en ORL: les blocs de la face. In *Annales francaises d'anesthésie et de reanimation*. 2004; 11(23): 1110-1113.
11. Guerin T, Cannamela A, Ageron FX, Messai S, Emptoz J, Beaka P. prise en charge des plaies de la face par blocs tronculaires aux urgences. *Urgences pratiques*. 2004;64:2-6.
12. Pascal J, Navez M, Mollieux S. Blocs des nerfs de la face. *Prat Anesth Réanim*. 2000; 4,94-9.
13. Fuzier R, Richez AS, Olivier M. Anesthésie locorégionale en urgence. *Réanimation*. 2007 Nov 1;16(7-8):660-4.
14. Bourgain JL. Anesthésie-réanimation en stomatologie et chirurgie maxillofaciale. EMC-Anesthésie-Reanimation. 2004 Mar 1;1(1):2-4.
15. Lacroix G, Meaudre E, Prunet B, Guerin T, Allary M, Kaiser E. Appréciation de la place de l'anesthésie locorégionale pour la prise en charge des plaies de la face aux urgences. In *Annales francaises d'anesthésie et de reanimation*. 2010 Jan 1. Elsevier Masson. 29(1): 3-7.