

# Takayasu's Disease and Pregnancy: A Rare Case Report and Review of the Literature

Haddout, S<sup>1\*</sup>, Jalal, M<sup>2</sup>, Lamrissi, A<sup>2</sup>, Bouhya, S<sup>3</sup><sup>1</sup>Intern in the Gynecology and Obstetrics Department of the University Hospital of Casablanca, Morocco<sup>2</sup>Assistant Professor in the Department of Obstetrics and Gynecology at the University Hospital of Casablanca, Morocco<sup>3</sup>Head of the maternity department of the University Hospital of Casablanca, MoroccoDOI: [10.36347/sjams.2022.v10i07.001](https://doi.org/10.36347/sjams.2022.v10i07.001)

| Received: 11.05.2022 | Accepted: 29.06.2022 | Published: 03.07.2022

\*Corresponding author: Haddout, S

Intern in the Gynecology and Obstetrics Department of the University Hospital of Casablanca, Morocco

## Abstract

## Case Report

Takayasu's disease is a chronic vasculitis affecting the aorta and its main branches. The main complication of this disease during pregnancy is severe preeclampsia and its complications that can lead to fetal death in utero. Multidisciplinary surveillance is recommended. Currently no preventive treatment is validated. An evaluation of antiplatelet agents and corticosteroids is therefore necessary.

**Keywords:** Takayasu disease and Pregnancy; Preeclampsia; Anti-aggregating platelets and pregnancy.

Copyright © 2022 The Author(s): This is an open-access article distributed under the terms of the Creative Commons Attribution 4.0 International License (CC BY-NC 4.0) which permits unrestricted use, distribution, and reproduction in any medium for non-commercial use provided the original author and source are credited.

## INTRODUCTION

Takayasu's disease is a chronic vasculitis affecting preferentially large arteries such as the aorta and its main branches. The incidence of this disease is 1.2 to 2.6 cases / million per year. It predominates in young women of childbearing age. It can lead to maternal and / or fetal complications during pregnancy. In pregnancies with Takayasu arteritis or after diagnosis, Takayasu arteritis negatively affects pregnancy by increasing the likelihood of complications such as hypertensive disorders by 13-fold [1]. The clinical manifestations of Takayasu's disease are very polymorphous; they can be asymptomatic as at the origin of serious attacks. This disease evolves classically in 2 phases, systemic and occlusive. It is characterized by the destruction of the media of the wall of the arteries, thus leading to the development of stenoses or arterial aneurysms. Pregnancy may have a favorable outcome, but complications are inevitable, especially for those diagnosed for the first time during pregnancy. Although those already diagnosed can enter pregnancy into remission and medication.

## CASE REPORT

We report the case of a 22-year-old primiparous patient. She is being treated for essential hypertension controlled for 3 months. The current pregnancy is at 27 weeks of amenorrhea and 4 days.

Our admission examination revealed a conscious patient, hypertensive to 200/120 mmHG, with headache resistant to symptomatic treatment, intermittent diplopia and vertigo with painful left ptosis dating back 3 months and lower limb edema (Figure 1). On cardiovascular examination, the B1B2 sounds are well perceived, without murmur at the aortic foci and subclavian arteries. There is an absence of sensitivity to carotid palpation and an absence of tension asymmetry of the limbs.

Obstetrically, our patient had no contractions or contractures and there was no externalized bleeding. Furthermore, the patient did not report any vomiting or photophobia. The patient was admitted to the hospital, evaluated by the resuscitating physician, and an emergency biologic workup was performed. Anti-HTA therapy and a loading and maintenance dose of magnesium sulfate were administered. Corticosteroid therapy for lung maturation with betamethasone was prescribed. The patient was strictly monitored for blood pressure profile as well as diuresis and osteotendinous reflexes. A neurological opinion was sought. The neurological examination revealed preserved muscle strength, normal sensitivity with left nerve IV involvement, complete left nerve III involvement and left nerve VI paresis without nerve V or VII involvement. The diagnosis of carotid aneurysm in its primary cavernous portion was evoked and an MRI with angiography was performed. The MRI revealed a heterogeneous mass in T1 hyposignal with a center in

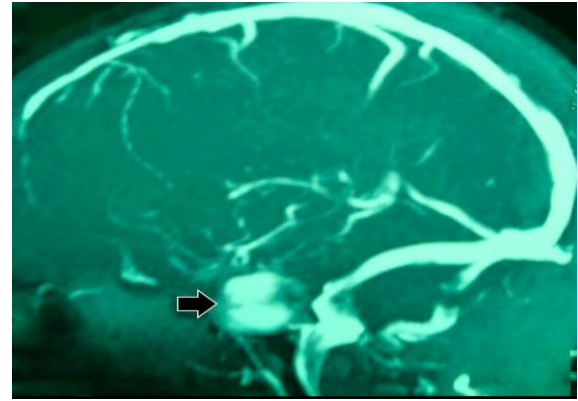
T2 hypersignal and FLAIR and a less intense periphery realizing the bulbous onion aspect measuring 31 \* 28 mm spread over 30mm exerting a mass effect on the cavernous sinus and the optic nerve (Figures 2 & 3). This aspect is in favor of a giant aneurysm of the partially thrombosed left internal carotid artery. The opinion of our neurosurgical colleagues was sought not advocating an immediate surgical indication, but a post-delivery arteriogram is necessary. From a biological point of view, the haemogram and the hydroelectrolytic and metabolic workup showed no abnormalities. Monitoring revealed progressive renal failure with a urea level of 0.69g /L vs. 0.64 vs. 0.39 and a creatinine of 16 mg / L vs. 14 mg / L vs. 13 mg / L. Impaired liver function with elevated transaminases (AST/ALT: 494 vs. 491 vs. 212) and LDH at 512 IU/L vs. 504 IU/L vs. 472 IU/L. Inflammatory and hemostasis tests were borderline normal and hepatitis serologies were negative. Cardiac ultrasound showed significant concentric hypertrophy of the left ventricle with good contractility, an ejection fraction of 55%, minimal mitral and aortic insufficiency, and a dilated aorta in its initial portion (aneurysm of the ascending aorta? The right ventricle is not dilated. The renal ultrasound evokes a bilateral renal angiodyplasia predominantly on the right. On ophthalmologic examination, our patient presents with limited abduction elevation, without diplopia in the left eye. The cornea and lens are clear with bilateral vascular formation, and a disused vessel appearance. During the hospitalization, the patient received dual therapy as antihypertensive treatment with improvement in biological status. Thus, she was discharged from the hospital to be followed up at the pregnancy risk consultation.

Three weeks after her hospitalization, the patient was admitted in emergency for a Hellyp syndrome in a pregnancy of 30 weeks of amenorrhea with a disturbed biological balance: Hemolysis, thrombocytopenia, collapsed hemostasis, disturbed renal and hepatic functions (Hb: 11g / dl, PQ: 96000 / mm<sup>3</sup>, WBC: 16000 / mm<sup>3</sup>, PT: 40%, APTT: 55sec, urea: 1.33g / l, creatinine: 26mg / L, AST / ALT: 227/299, LDH: 636IU / l).

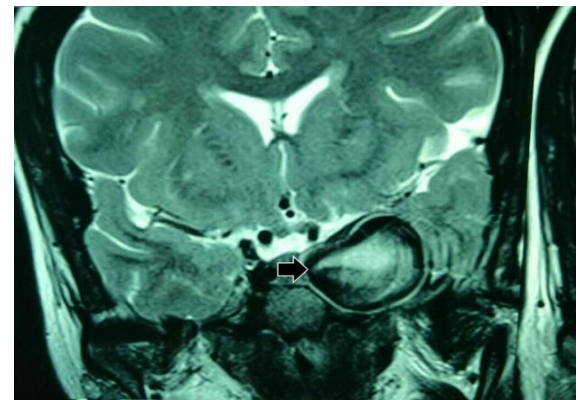
A code red cesarean section for maternal rescue is indicated. It allows the extraction of a deceased newborn at H1 of life. The post-operative course was simple and the patient was seen in internal medicine for the follow-up of her pathology.



**Figure 1: Left ptosis revealed on clinical examination**



**Figure 2: Aneurysm image on MRI**



**Figure 3: Aneurysm image on MRI**

## DISCUSSION

The pathogenesis of Takayasu disease is currently unclear. Nevertheless, several hypotheses are being explored. An infectious origin has been suggested, particularly because of the frequency of associated tuberculosis. Higher levels of antibodies to mycobacterial antigens, notably heat shock protein (HSP) 65, are more frequently found in Takayasu patients than in controls. An autoimmune origin is suggested by the association of Takayasu disease with other autoimmune diseases (Crohn's disease, ankylosing spondylitis, systemic lupus erythematosus). Finally, the elevation of interleukin-6 (IL-6) levels correlated with disease activity suggests the involvement of monocytes and T lymphocytes (Lc) in the pathophysiology of Takayasu disease [2]. In its pathophysiology, Takayasu disease induces transmural inflammation of the arterial wall and thus a decrease in lumen caliber. It affects the aorta and its branches, leading to secondary hypertension, retinopathy, heart disease, stroke and earlier death [3]. The risk of thrombosis is increased, which requires treatment.

Takayasu disease progresses in two phases:

- A so-called pre-occlusive phase where systemic symptoms appear in the foreground (fever, night sweats, weight loss, arthromyalgia, sometimes erythema nodosum).

- An occlusive phase where the consequences of the vascular inflammation and the healing process are responsible for stenoses and aneurysms which become symptomatic and which sometimes reveal the disease.

The search for the diagnosis of Takayasu disease is based primarily on vascular imaging. Arteriography is considered the gold standard. Arterial Doppler ultrasound allows the detection of vascular lesions of the supra-aortic trunks. In the pre-occlusive phase of the disease, it allows the detection of homogeneous and circumferential parietal thickening. CT angiography and MRI angiography can confirm this homogeneous and circumferential thickening of more than 3 mm in thickness, suggesting the diagnosis of inflammatory arteritis [4, 5]. This type of abnormality justifies the performance of an echocardiography in order not to ignore the presence of pulmonary arterial hypertension.

Today, the development of <sup>18</sup>F-fluorodeoxyglucose positron emission tomography (PET) suggests the possibility of performing morphofunctional analysis of patients with Takayasu disease, which may allow for early diagnosis or better assessment of disease activity in order to slow the development of lesions in the occlusive phase [2, 3].

The American College of Rheumatology diagnostic criteria are: Age of onset <40 years, Vascular clamping of the extremities, especially in the upper extremities, Decrease in at least one brachial pulse, Systolic blood pressure difference > 10 mmHg between the 2 arms, Blow to a subclavian artery or abdominal aorta, On arteriography, stenosis or occlusion of the aorta or its branches or proximal limb arteries. The presence of 3 or more criteria gives a sensitivity of 90.5% and a specificity of 97.8% for the diagnosis of Takayasu disease [6].

The Ishikawa diagnostic criteria modified by Sharma in 1996 require three major criteria: Stenosis or occlusion of the middle portion of the left or right subclavian artery on arteriography. Clinically, there is claudication, pulse suppression or asymmetric tension, fever, neck pain, amaurosis, visual disturbances, syncope, dyspnea, palpitations. This classification also includes ten minor criteria: SV > 20 mm / h, Sensitivity of the carotid arteries to palpation, Brachial BP > 140/90 mmHg or popliteal BP > 160 / 90mmHg, Aortic insufficiency or dilatation of the aortic annulus, Lesion of the pulmonary arteries, Stenosis or occlusion of the middle part of the left carotid artery on arteriography, Stenosis or occlusion of the distal third of the brachiocephalic trunk on arteriography, Lesion of the descending thoracic aorta on arteriography, Lesion of the abdominal aorta on arteriography, Coronary lesion before age 30 in the absence of dyslipidemia or diabetes. The presence of 2 major criteria or 1 major + 2

minor criteria or 4 minor criteria suggests a high probability of Takayasu disease (sensitivity 92.5%, specificity 95%) [5, 6].

Intracranial carotid aneurysms are a rare condition with serious risks. They are defined by a diameter greater than 24 mm and represent 5% of all intracranial aneurysms. Clinically, they may present with headache, intracranial hypertension syndrome, mass syndrome especially in intracavernous locations and rarely ischemic stroke. Arteriography is a key examination for the diagnosis and endovascular treatment of giant intracranial carotid artery aneurysms. Complications may be inaugural of the pathology such as subarachnoid hemorrhage, epistaxis, and exceptionally, otorrhagia. CT, MRI and MRA determine the degree of thrombosis of the aneurysm sac, the state of the adjacent vessels, allow the search for complications such as ischemic stroke, as well as the signs of rupture of the aneurysm: subarachnoid hemorrhage, aneurysmal dissection giving a pseudoaneurysm appearance. The arteriography specifies: The circulating part of the aneurysm, and the state of the polygon of Willis.

Fertility in women with Takayasu's arteritis is normal. Pregnancy does not seem to be the cause of arteritis. However, some obstetrical complications may occur during the course of the pregnancy. Pregnancy-induced hypertension and preeclampsia are the most frequent complications. Stroke and cardiac decompensation are rarer (5%). Most pre-eclampsias associated with Takayasu disease are severe and develop in the third trimester [7]. The prognosis of the pregnancy therefore depends on the risk of developing a complication secondary to the hypertension. The main fetal complication is intrauterine growth restriction (20%) [8].

Delivery is also a period of risk, particularly for hypertensive pressure, but also for vascular complications. Arterial stenosis of the lower limbs may make general anesthesia or spinal block anesthesia difficult. Epidural anesthesia is preferred if possible in these patients. Aortic insufficiency should lead to antibiotic prophylaxis of endocarditis during delivery [11].

Treatment of active Takayasu disease is based primarily on corticosteroids, which are continued in low doses during pregnancy and postpartum. If necessary, azathioprine is used in combination. Overall, the disease activity itself does not appear to increase during or after pregnancy.

It is therefore essential to monitor and ensure satisfactory blood pressure control during pregnancy in these patients, with a preference for calcium channel blockers (nifedipine) and/or methyl dopa. Angiotensin-converting enzyme inhibitors are contraindicated

because of possible renal stenosis in the mother, but also because of their proven toxicity on the renal system of the fetus during the 2nd and 3rd trimesters of pregnancy [9]. Concerning antiplatelet agents, their systematic prescription during Takayasu disease is not a current recommendation of expert groups. Aspirin can be continued during pregnancy if it has been prescribed previously. Its prescription should be proposed for the prevention of pre-eclampsia [10, 11].

## CONCLUSION

Pregnancy planning is essential in patients with Takayasu disease. A thorough workup of the vasculitis is necessary to detect the various vessel lesions in order to discuss appropriate treatment, medical or possibly revascularization (surgery or angioplasty). The main complication of this disease during pregnancy is severe preeclampsia and its complications that can lead to fetal death in utero. Early diagnosis with appropriate medical or surgical management is essential for a good prognosis. An interdisciplinary collaboration between obstetricians, cardiologists, rheumatologists and neurologists is necessary for an optimal maternal and fetal prognosis.

## REFERENCES

1. Quéméneur, T., Hachulla, E., Lambert, M., Perez-Cousin, M., Queyrel, V., Launay, D., ... & Hatron, P. Y. (2006). Takayasu arteritis. *Presse Medicale (Paris, France: 1983)*, 35(5 Pt 2), 847-856.
2. Pagnoux, C. (2008). Pregnancy and vasculitides. *Presse Medicale (Paris, France: 1983)*, 37(11), 1657-1665.
3. Lumbreras-Marquez, J., Castillo-Reyther, R. A., De-la-Maza-Labastida, S., & Vazquez-Alaniz, F. (2018). Takayasu arteritis a cause of hypertensive disorder of pregnancy: a case report. *Journal of Medical Case Reports*, 12(1), 1-4.
4. Vanoli, M., Daina, E., Salvarani, C., Sabbadini, M. G., Rossi, C., Bacchiani, G., ... & Itaka Study Group. (2005). Takayasu's arteritis: a study of 104 Italian patients. *Arthritis Care & Research*, 53(1), 100-107.
5. Lambert, M., Hachulla, E., Huglo, D., & Hatron, P. Y. (2009). Maladie de Takayasu: caractéristiques cliniques, prise en charge diagnostique, traitement et pronostic. *Médecine Nucléaire*, 33(8), 512-517.
6. Mukhtyar, C., Guillevin, L., Cid, M. C., Dasgupta, B., de Groot, K., Gross, W., ... & European Vasculitis Study Group. (2009). EULAR recommendations for the management of large vessel vasculitis. *Annals of the rheumatic diseases*, 68(3), 318-323.
7. Duley, L., Meher, S., Hunter, K. E., Seidler, A. L., & Askie, L. M. (2019). Antiplatelet agents for preventing pre-eclampsia and its complications. *Cochrane database of systematic reviews*, (10), CD004659.
8. Vaysse, C., Touboul, C., Vaysse, N., Delchier, M. C., & Vayssiere, C. (2009). Mort fœtale in utero durant la gestation compliquant une maladie de Takayasu: à propos d'un cas et revue de la littérature. *Journal de gynécologie obstétrique et biologie de la reproduction*, 38(7), 595-598.
9. Ben Hassine, L., Cherif, E., & Khalfallah, N. (2009). Traitement médical de la maladie de Takayasu. *La Revue de médecine interne (Paris)*, 30, S262-S264.
10. Maksimowicz-McKinnon, K., Clark, T. M., & Hoffman, G. S. (2007). Limitations of therapy and a guarded prognosis in an American cohort of Takayasu arteritis patients. *Arthritis & Rheumatism*, 56(3), 1000-1009.
11. Abularrage, C. J., Slidell, M. B., Sidawy, A. N., Kreishman, P., Amdur, R. L., & Arora, S. (2008). Quality of life of patients with Takayasu's arteritis. *Journal of vascular surgery*, 47(1), 131-137.