

## Periodontal Microsurgery: An Advanced Approach for Minimal Invasive Periodontal Therapy

Dr. Reema Shah<sup>1</sup>, Dr. Sameer Zope<sup>2\*</sup>, Dr. Girish Suragimath<sup>3</sup>, Dr. Siddhartha Varma<sup>2</sup>, Dr. Apurva Pisal<sup>4</sup>

<sup>1</sup>Post Graduate Student, Department of Periodontology, School of Dental Sciences, Krishna Institute of Medical Sciences Deemed to be University, NH4, Pune - Bangalore Highway, Agashivnagar, Malkapur, Maharashtra 415539, India

<sup>2</sup>Reader, Department of Periodontology, School of Dental Sciences, Krishna Institute of Medical Sciences Deemed to be University, NH4, Pune - Bangalore Highway, Agashivnagar, Malkapur, Maharashtra 415539, India

<sup>3</sup>Head of Department, Department of Periodontology, School of Dental Sciences, Krishna Institute of Medical Sciences Deemed to be University, NH4, Pune - Bangalore Highway, Agashivnagar, Malkapur, Maharashtra 415539, India

<sup>4</sup>Sr. Lecturer, Department of Periodontology, School of Dental Sciences, Krishna Institute of Medical Sciences Deemed to be University, NH4, Pune - Bangalore Highway, Agashivnagar, Malkapur, Maharashtra 415539, India

DOI: [10.36347/sjds.2022.v09i06.001](https://doi.org/10.36347/sjds.2022.v09i06.001)

| Received: 17.05.2022 | Accepted: 29.06.2022 | Published: 03.07.2022

\*Corresponding author: Dr. Sameer Zope

Reader, Department of Periodontology, School of Dental Sciences, Krishna Institute of Medical Sciences Deemed to be University, NH4, Pune - Bangalore Highway, Agashivnagar, Malkapur, Maharashtra 415539, India

### Abstract

### Review Article

The use of magnification and microsurgery to perform various procedures are recent developments in medical and dental field. The available literature specifically of periodontal surgical procedures was analysed and compiled, and it indicated that when magnification is incorporated in periodontal practice, it improves visual acuity, decreased patient morbidity, ergonomic benefits, rapid healing, and enhanced patient acceptance. The illumination and magnification provided by the operating microscope as well as the use of microsurgical instrumentation have allowed microsurgeons to perform procedures with more precision. Microsurgery is an interesting concept in the minds of many dental professionals, yet the inability of most clinicians to perform such procedures shows the dental professions lack of understanding of what microsurgery truly encompasses. The objective of the present paper is to offer a brief review on periodontal microsurgery, role of magnification systems, application of microsurgical principles in various periodontal surgical procedures, advantages of microsurgery over conventional surgery and to reinforce the use of microscope into periodontal practice.

**Keywords:** Ergonomics, magnification, minimally invasive, periodontal microsurgery, surgical microscope.

Copyright © 2022 The Author(s): This is an open-access article distributed under the terms of the Creative Commons Attribution 4.0 International License (CC BY-NC 4.0) which permits unrestricted use, distribution, and reproduction in any medium for non-commercial use provided the original author and source are credited.

## INTRODUCTION

In the last few decades, a plethora of changes have been achieved in dental sciences, both in terms of concepts and techniques. Regenerative and resective surgical procedures, periodontal plastic surgery and dental implants all demands clinical performance levels requiring progressively more intricate surgical skills that challenge the technical motor skills of periodontal surgeons. In the field of surgical periodontal therapy, "Periodontal microsurgery" is one of the many advances that have evolved [1].

Although the first accurate lenses were not made until about the year 1300, credit for the first microscope is usually given to Hans and Zacharias Jansen, a father and son who operated a Dutch lens-grinding business, around 1595 who produced both

simple (single lens) and compound (two lenses) microscopes [2]. Until the middle of the 19th century, Carl Zeiss, Ernst Abbe, and Otto Schott devoted significant time to develop the microscope, as we know it today. Their product was the genesis of the surgical operating microscope (SOM) that ultimately found its way into the practice of medicine [3].

In 1921, Dr Carl Nylen, also known as the father of microsurgery reported the use of a monocular microscope for operations to correct chronic otitis of the ear. The microscope was first introduced to dentistry in 1978 by Apotheker and Jako. In 1963, it was first introduced in the branch of endodontics and later in the year 1992, the field of periodontology adopted its use in various surgical procedures [4].

Daniel in 1979 broadly defined Microsurgery as surgery performed under magnification provided by the microscope. While, microsurgery was described as a methodology, a modification and refinement of existing surgical techniques using magnification to improve visualization that had implications and applications to all specialties by Serafin in 1980 [5].

### Microsurgical Triad

Three definitive benefits of illumination, magnification, and instrumentation (increased precision in delivery of surgical skills) rendered by operating microscope is collectively known as microsurgical triad (Fig 1) [6].

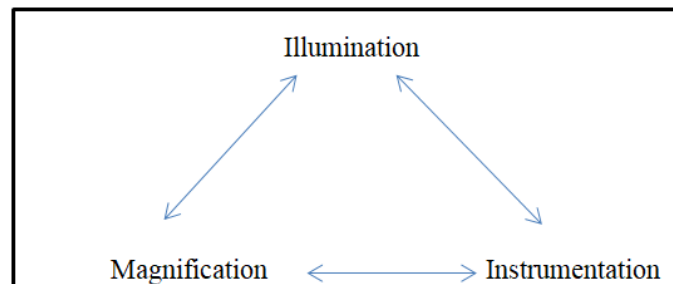


Fig 1: Microsurgical Triad

### Illumination

Collateral lighting systems are offered by most of the manufacturers particularly for higher magnification ranging from 4× and more. During the selection of an accessory lighting source, certain essential aspects need to be considered which includes total amount of quality, weight and brightness of the light, the ease of focusing and directing the light within the field of the magnifiers. Methods of focusing light on specific areas has improved due to the illumination achieved through fiberoptic technology which is a standard feature of surgical operating microscopes [1].

### Magnification

The second component of the microsurgical triad is considered as the magnification which can be achieved through various magnifying systems. A wide range of magnifying systems which could be either simple or complex including loupes and the operating microscope are available to the Dentist, but the use of magnification mode depends on the procedure and the results to be accomplished and also on the level of operators experience level [7].

### LOUPES

The most common form of magnification used in dentistry are loupes which were introduced to medicine by a German physician named, Saemisch in 1876. They are available in three types, such as simple, compound, or prism in design and it can be either in the form of eyeglasses or can be directly attached to a headset. These are fundamentally made of two monocular microscopes that are angled to focus on an object with side-by-side lenses. While working with the loupes there is no choice and opportunity for movement with a set working distance, which causes the eyes to converge to view an image creating difficulty in maintaining focus. It can further result in eyestrain, fatigue, neck and back strain due to poor posture and may sometimes lead to vision changes due to prolonged use of ill-fitted loupes.

On the other hand, converging multiple lenses are used with intervening air spaces in compound loupes to gain refracting power, magnification, depth of the field and working distance. It consists of two glass pieces, each of specific density which are bonded together using clear resin. The chromatic aberration of the adjacent piece is counteracted by the glass pieces, thus making it the desirable lenses to be used by the clinician. Compound loupes are commonly mounted in or on eye glasses, thus providing an improved ergonomic posture of an operator along with significant advancements in optical performance.

Prism Loupes are actually low-power telescopes which are considered as most advanced loupe magnification system. These loupes are the most optically advanced type of loupe magnification available which produces better magnification, larger fields of view, wider depths of field, and longer working distances compared to other loupes. An adjustable, high-quality sealed prism loupe with coated lenses which offers a magnification ranging between ×4 and ×4.5, mounted either on headband- or on front frame with a suitable working distance and a large field of view, seems to be the instrument of choice for the use in periodontal surgery [8].

### SURGICAL MICROSCOPES

Surgical microscopes are superior to loupes in terms of flexibility, visual access, optical magnification and clinician comfort. It generally comprises of Eyepieces, objective lens, binocular tube, light source, microscope body and stand. It is much more expensive than the loupes and may be difficult to use initially. However, with proper instructions, guidance and practice, operating microscopes becomes easy to use. Operating microscope fused with fully coated optics and achromatic lenses providing high resolution and high contrast stereoscopic vision works on “Galilean Principles”. There must be sufficient distance between the microscope and the site being viewed while working

with the surgical microscope for proper instrumentation. A microscope should have an extensive vertical or horizontal manoeuvrability which can either be mounted to a wall, ceiling or floor stand for use in the various areas of the oral cavity. Beam splitter for attaching documentation and/or co-observation modules, control panels and couplings are microscopic accessories that can be attached to the surgical microscope.

### **Ergonomics in microsurgery**

An undisturbed state of mind, good body comfort and relaxed posture, a stable instrument-holding position and a well-supported hand are all essential for an operating surgeon [7]. The operating surgeon must be seated with an upright body posture along with straight back and head, also thighs should be parallel to the floor keeping both the feet flat on the floor. All movements should be effective in producing a purposeful and a deliberate motion. To accomplish precise controlled movements of fingers, the wrist and the ulnar surface of the forearm should be supported by resting on a flat surface to reduce muscle tremor originating from both the unintentional and intentional actions of the body [8, 9].

The pen grip or internal precision grip are the most commonly advocated precision grip for microsurgical procedures which provides a greater stability due to the tripod formed by the fingers, while the middle finger holds the instrument in comparison to any other hand grip [8, 10].

### **Use of Microsurgery in Periodontics**

The end result of microsurgery is simply superior when compared to that of the conventional surgery. The differences observed in various aspects such as in cleaner incisions, closer wound apposition, reduced hemorrhage, and reduced trauma at the surgical site can be the reason microsurgery has gained acceptance among some periodontists that opens the horizons for better patient care. The coarseness of most Periodontal surgical manipulation is revealed when viewed under the microscope and permits less traumatic and less invasive surgery.

#### **1. Crown lengthening**

It seems logical to substantiate the fact that magnification is beneficial in Crown lengthening procedures due to limited comparative studies of crown lengthening and ridge augmentation with microsurgical methods [11, 12].

#### **2. Root surface debridement**

An essential component recognized for periodontal therapy that has gained universal importance is root surface debridement [13-16]. Several authors have emphasized that for improved outcome of periodontal treatment, thorough debridement of root surface is more crucial rather than the choice of surgical

modality [17, 18]. Root instrumentation when done under illumination have reported an effective and improved early healing index and post-operative pain. It can be done with micro ultrasonic instruments. It varies in size from about 0.2-0.6 mm in diameter. It has variable power settings ranging from 25,000 to more than 40,000 cycles per second which allows subgingival treatment in deep pockets with less chances of over instrumentation of the root surface [19]. These instruments deliver ultrasonically activated lavage in the working area as it has active working sides on all surfaces and thus can be used with minimal water spray. To conclude, the procedure of root surface debridement is enhanced through magnification which boosts the clinician's ability to differentiate the calculus from tooth surface and biofilm to the microscopic level.

### **3. In perio-aesthetics**

The continuous search for improved surgical procedures to address gingival deformities is a consequence of increasing demand for esthetics in the periodontal clinical practice. Innovative techniques have helped clinicians achieve predictability in root coverage. Periodontal plastic surgery is "technique-sensitive" and generally thought to be more demanding than other periodontal procedures. Hence, surgical microscope appears to be a natural evolution in this area of periodontics. Microsurgery has wide implications including the rotational, free gingival, double papilla, and sub epithelial connective tissue grafts for the coverage since it causes minimal trauma and enhances the wound healing process. The combination of small microsurgical instruments and delicate surgical techniques allow for extremely fine, crisp, and accurate incisions, gentle tissue handling, and precise repositioning of the wound margins with smaller needles and sutures [20]. Along with rapid wound healing, low morbidity and less discomfort, narrow incision lines, and small surgical wounds can add to better esthetic results. Mucogingival surgical procedures designed for the coverage of exposed root surfaces, performed using microsurgical approach, had improved the treatment outcomes substantially and to a clinically relevant level compared with clinical performance under routine macroscopic conditions [21].

### **4. In periodontal flap surgery**

In periodontics, microsurgery is the descendant of conventional periodontal surgery in an attempt to reduce the surgical trauma and to gain exposure of the underlying tissues, i.e., bone and the root surface. Periodontal flap margins can be elevated by using microsurgical techniques with uniform thickness that has a scalloped butt-joint. This facilitates precise adaptation of the tissue to the teeth or the opposing flap in an edentulous area, thus eliminating the gaps and dead spaces circumventing the need for new tissue formation and enhancing periodontal regeneration. The use of surgical microscope has become the indispensable part of periodontal surgical practice as it

increases surgical effectiveness [22, 23]. Due to more accurate and atraumatic handling of the soft tissues, improved initial healing in the sites with microsurgical approach have been revealed in many studies. Further, the coronal displacement of the flaps over the defects was found to be easier and had less tension with the microsurgical technique which facilitates healing and return of the mucogingival line to its original position. Studies with enamel matrix proteins have shown that enamel matrix derivative could exert better biologic activity in microsurgically treated sites because of reduced tissue trauma and vessel injury to improve vascularization and achieve primary wound closure, which allows optimal retention of enamel matrix derivatives [24].

### 5. Periodontal regeneration

In the last few decades, the use of microsurgical approach for the treatment of [25, 26] intrabony defects have been proposed by several authors as the existing surgical procedures and their clinical effectiveness for periodontal regeneration has been extensively studied. Improved illumination and magnification of microsurgical approach at the site of surgery, permits proper access to the intrabony defect and leads to the proper debridement with an increased accuracy and minimal trauma. Furthermore, bacterial contamination minimizes, as it has the competency to achieve and maintain a primary wound closure, thereby providing a more favourable condition for periodontal regeneration [27-30].

### 6. Mucogingival surgery

In today's practice, mucogingival surgeries are not only concerned with the treatment but also with the esthetic demands of the patients. During surgery, the damage to the tissues can be greatly reduced by atraumatic surgical approach. Therefore, extremely fine and accurate incisions; to promote stabilization and immobilization of the graft [31] and for the precise closure of wound margins, meticulous suturing is a fundamental that is performed to achieve an excellent result, both in terms of function and esthetics. Sites where esthetic demands complete and perfect coverage, the use of surgical microscope in mucogingival therapy might prove useful. An improved outcome of the root coverage procedures [32-36] and interdental papilla augmentation have been suggested when periodontal microsurgery is performed by a skilled and trained surgeon. A distinct advantage of using periodontal microsurgery over conventional macrosurgery have been shown for the treatment of gingival recession. Some of the advantages includes, increased vascularization of the grafts [33] relatively better percentages of root coverage [33, 37-39], a significant increase in width and thickness of keratinized tissue [20], an improved esthetic outcome, [32,40] and decreased patient morbidity.

### 7. In interdental papilla reconstruction

The lost interdental papilla which can create phonetic problems, saliva bubbles, and cosmetic deficiencies can be replaced by newly developed microsurgical techniques. Iatrogenic surgical removal, as part of tissue collapse following extraction, with periodontal pocket elimination surgery, periodontal bone loss, and orthodontic separation of overlapped teeth can lead to papillary deficiency. Periodontal microsurgery, makes it a realistic possibility also a significant leap in the field of perio-esthetics for the success in the treatment of black triangle [41].

### 8. In implant therapy and Sinus lift procedure

All phases of implant treatment ranging from implant placement to implant recovery can be performed using a microscope. Also, the management of peri-implantitis may be accomplished with more precision under magnification [42, 43]. Microsurgery has been proved as one of the novel applications in the sinus lift procedure with a success rate of 97% [44, 45]. The sinus membrane can be directly visualized using surgical microscope which minimizes the risk of perforations. It has been reported that an improvement of an altered sensation due to implants encroaching on the inferior alveolar nerve can be achieved by incorporating the microsurgical techniques even without unscrewing them. Although no studies establish that the postoperative pain is reduced following extraction or implant placement using microsurgery, there is a strong theoretical rationale to suggest that less surgical trauma results in less pain and faster healing [46].

### Advantages of the Surgical Microscope

The main advantage of using the surgical microscope is the postural correction of the clinician. It leads to the minimal discomfort to the clinicians back and neck. As constant adjustments are avoided, the operator experiences less tiredness of eyes. The other advantages include the procedural part. As it is a minimally invasive procedure, atraumatic tissue management along with accurate closure of primary wounds can be achieved. It increases the diagnostic skills of the clinician, thereby improving the surgical quality. A greater predictability for various regenerative and cosmetic procedures has been achieved after increased effectiveness of root surface debridement. It has also improved the digital documentation in the form of videos, slides, photographs, etc. With the improved quality of surgical treatments using surgical microscope, there is an increase in the personal and professional satisfaction. Thus, psychological advantage can also be seen as it reduces the anxiety of the patient [47].

### Disadvantages of the Surgical Microscope

Using a Surgical Microscope has its own disadvantages. It needs additional educational requirements such as understanding of the optics and its



surgical technique. It has limited surgical access and thus long adjustment period for clinical proficiency may be required. Initially it may increase the surgical time, also it increases the treatment cost [47].

## CONCLUSION

The data pursued from the reviewed literature justifies that periodontal microsurgery has shown an increase in clinician as well as patient acceptance and it seems to show promising clinical results. It can be said that the periodontal microsurgery is in its initial stages but will play a major role in the future. This skill requires practice to achieve proficiency. The small scale of microsurgery presents special challenges in dexterity and perception. Its implementation is more demanding and technique sensitive as compared to the conventional periodontal procedures. It appears to be an expected evolution for the specialty of periodontics in which periodontal microsurgery can be beneficial. New possibilities to improve periodontal care have been offered by microsurgery in a variety of ways. Its benefits include improved cosmetics, rapid healing, minimal discomfort, and enhanced patient acceptance.

## REFERENCES

1. Yadav, V. S., Salaria, S. K., Bhatia, A., & Yadav, R. (2018). Periodontal microsurgery: Reaching new heights of precision. *Journal of Indian Society of Periodontology*, 22(1), 5-11.
2. Stevenson, J. R. (2005). Founding fathers of microscopy. 22 May 2005. Department of microbiology, Miami University. Cited in Magnification and illumination in apical surgery. *Endodontic Topics*, 11, 56-77.
3. Vision Engineering. (2005). Vision Engineering: Microscope History, Science Technology. Cited in Magnification and illumination in apical surgery. *Endodontic topics*, 11, 56-77.
4. Nylen, C. O. (2005). The microscope in aural surgery: Its first use, and later development. Cited in Magnification and illumination in apical surgery. *Endodontic Topics*, 11, 56-77.
5. Serafin, D. (1980). Microsurgery: past, present, and future. *Plastic and reconstructive surgery*, 66(5), 781-785.
6. Belcher, J. M. (2001). A perspective on periodontal microsurgery. *International Journal of Periodontics and Restorative Dentistry*, 21(2), 191-196.
7. Tibbetts, L. S., & Shanelec, D. (2009). Principles and practice of periodontal microsurgery. *Int J Microdent*, 1(1), 2-12.
8. Barraquer, J. I. (1980). The history of the microscope in ocular surgery. *Microsurgery*, 1(4), 288-299.
9. Acland, R. (1989). *Practice Manual for Microvascular Surgery*. 2nd ed. St Louis: Mosby.
10. Bunke, H., Chater, N., & Szabo, Z. (1975). *The Manual of Microvascular Surgery*. San Francisco: Ralph K Daves Medical Centre.
11. Hegde, R., Sumanth, S., & Padhye, A. (2009). Microscope-enhanced periodontal therapy: a review and report of four cases. *J Contemp Dent Pract [Internet]*, 10(5), 88-100.
12. Cosyn, J., Pollaris, L., Van der Linden, F., & De Bruyn, H. (2015). Minimally Invasive Single Implant Treatment (MISIT) based on ridge preservation and contour augmentation in patients with a high aesthetic risk profile: one-year results. *Journal of clinical periodontology*, 42(4), 398-405.
13. Hirschfeld, L., & Wasserman, B. (1978). A long-term survey of tooth loss in 600 treated periodontal patients. *Journal of periodontology*, 49(5), 225-237.
14. Loos, B., Nylund, K., Claffey, N., & Egelberg, J. (1989). Clinical effects of root debridement in molar and non-molar teeth A 2-year follow-up. *Journal of clinical periodontology*, 16(8), 498-504.
15. Nordland, P., Garrett, S., Kiger, R., Vanooteghem, R., Hutchens, L. H., & Egelberg, J. (1987). The effect of plaque control and root debridement in molar teeth. *Journal of clinical periodontology*, 14(4), 231-236.
16. Pihlstrom, B. L., Ortiz-Campos, C., & McHugh, R. B. (1981). A randomized four-year study of periodontal therapy. *Journal of Periodontology*, 52(5), 227-242.
17. Lindhe, J., Westfelt, E., Nyman, S., Socransky, S. S., & Haffajee, A. D. (1984). Long-term effect of surgical/non-surgical treatment of periodontal disease. *Journal of clinical periodontology*, 11(7), 448-458.
18. Lindhe, J., & Nyman, S. (1984). Long-term maintenance of patients treated for advanced periodontal disease. *Journal of clinical periodontology*, 11(8), 504-514.
19. Kwan, J. Y. (2005). Enhanced periodontal debridement with the use of micro ultrasonic, periodontal endoscopy. *Journal of the California Dental Association*, 33(3), 241-248.
20. Andrade, P. F., Grisi, M. F., Marcaccini, A. M., Fernandes, P. G., Reino, D. M., Souza, S. L., ... & Novaes Jr, A. B. (2010). Comparison between micro and macrosurgical techniques for the treatment of localized gingival recessions using coronally positioned flaps and enamel matrix derivative. *Journal of periodontology*, 81(11), 1572-1579.
21. Tibbetts, L. S., & Shanelec, D. (2009). Principles and practice of periodontal microsurgery. *The International Journal of Microdentistry*, 1, 13-24.
22. Belcher, J. M. (2001). A perspective on periodontal microsurgery. *International Journal of Periodontics and Restorative Dentistry*, 21(2), 191-196.
23. Buncke, J. H. Jr., Chater, N. L., & Szabo, Z. (1975). *The Manual of Microvascular Surgery*. San Francisco, California: Ralph K. Daves Medical Center, Microsurgical Unit; p. 53.
24. Acland, R. D. (1989). *Practice Manual for Microvascular Surgery*. 2<sup>nd</sup> ed. St. Louis: CV Mosby.
25. Harrel, S. K., Wilson Jr, T. G., & Nunn, M. E. (2005). Prospective assessment of the use of enamel matrix proteins with minimally invasive surgery. *Journal of periodontology*, 76(3), 380-384.
26. Cortellini, P., Nieri, M., Pini Prato, G., & Tonetti, M. S. (2008). Single minimally invasive surgical technique with an enamel matrix derivative to treat multiple adjacent intra-bony defects: Clinical

- outcomes and patient morbidity. *Journal of clinical periodontology*, 35(7), 605-613.
27. Wachtel, H., Schenk, G., Böhm, S., Weng, D., Zuhr, O., & Hürzeler, M. B. (2003). Microsurgical access flap and enamel matrix derivative for the treatment of periodontal intrabony defects: a controlled clinical study. *Journal of Clinical Periodontology*, 30(6), 496-504.
  28. Cortellini, P., & Tonetti, M. S. (2009). Improved wound stability with a modified minimally invasive surgical technique in the regenerative treatment of isolated interdental intrabony defects. *Journal of Clinical Periodontology*, 36(2), 157-163.
  29. Fickl, S., Thalmair, T., Kebschull, M., Böhm, S., & Wachtel, H. (2009). Microsurgical access flap in conjunction with enamel matrix derivative for the treatment of intra-bony defects: A controlled clinical trial. *Journal of clinical periodontology*, 36(9), 784-790.
  30. Cortellini, P., & Tonetti, M. S. (2001). Microsurgical approach to periodontal regeneration. Initial evaluation in a case cohort. *Journal of Periodontology*, 72(4), 559-569.
  31. Camargo, P. M., Melnick, P. R., & Kenney, E. B. (2001). The use of free gingival grafts for aesthetic purposes. *Periodontology 2000*, 27(1), 72-96.
  32. Zuhr, O., Fickl, S., Wachtel, H., Bolz, W., & Hürzeler, M. B. (2007). Covering of gingival recessions with a modified microsurgical tunnel technique: case report. *International Journal of Periodontics and Restorative Dentistry*, 27(5), 457-463.
  33. Burkhardt, R., & Lang, N. P. (2005). Coverage of localized gingival recessions: comparison of micro- and macrosurgical techniques. *Journal of clinical periodontology*, 32(3), 287-293.
  34. Francetti, L., Del Fabbro, M., Testori, T., & Weinstein, R. L. (2004). Periodontal microsurgery: report of 16 cases consecutively treated by the free rotated papilla autograft technique combined with the coronally advanced flap. *International Journal of Periodontics & Restorative Dentistry*, 24(3), 272-279.
  35. Kumar, A., Bains, V. K., Jhingran, R., Srivastava, R., Madan, R., & Rizvi, I. (2017). Patient-centered microsurgical management of gingival recession using coronally advanced flap with either platelet-rich fibrin or connective tissue graft: A comparative analysis. *Contemporary clinical dentistry*, 8(2), 293-304.
  36. Agarwal, S. K., Jhingran, R., Bains, V. K., Srivastava, R., Madan, R., & Rizvi, I. (2016). Patient-centered evaluation of microsurgical management of gingival recession using coronally advanced flap with platelet-rich fibrin or amnion membrane: A comparative analysis. *European journal of dentistry*, 10(01), 121-133.
  37. Bittencourt, S., Del Peloso Ribeiro, É., Sallum, E. A., Nociti Jr, F. H., & Casati, M. Z. (2012). Surgical microscope may enhance root coverage with subepithelial connective tissue graft: A randomized-controlled clinical trial. *Journal of periodontology*, 83(6), 721-730.
  38. Jindal, U., Pandit, N., Bali, D., Malik, R., & Gugrani, S. (2015). Comparative evaluation of recession coverage with sub-epithelial connective tissue graft using macrosurgical and microsurgical approaches: A randomized split mouth study. *Journal of Indian Society of Periodontology*, 19(2), 203-207.
  39. Nizam, N., Bengisu, O., & Sönmez, Ş. (2015). Micro- and macrosurgical techniques in the coverage of gingival recession using connective tissue graft: 2 years follow-up. *Journal of Esthetic and Restorative Dentistry*, 27(2), 71-83.
  40. Rossi, R., Pilloni, A., & Morales, R. S. (2009). Qualitative assessment of connective tissue graft with epithelial component. A microsurgical periodontal plastic surgical technique for soft tissue esthetics. *European Journal of Esthetic Dentistry*, 4(2), 118-128.
  41. Francetti, L., Del Fabbro, M., Calace, S., Testori, T., & Weinstein, R. L. (2005). Microsurgical treatment of gingival recession: a controlled clinical study. *International Journal of Periodontics & Restorative Dentistry*, 25(2), 181-188.
  42. Shanelec, D. A. (2005). Anterior esthetic implants: microsurgical placement in extraction sockets with immediate plovisionals. *Journal of the California Dental Association*, 33(3), 233-240.
  43. Duello, G. V. (2005). The use of surgical microscopes in contemporary implant therapy. *Practical procedures & aesthetic dentistry: PPAD*, 17(10), 717-718.
  44. Steiner, G. G., Steiner, D. M., Herbias, M. P., & Steiner, R. (2010). Minimally invasive sinus augmentation. *Journal of Oral Implantology*, 36(4), 295-304.
  45. Engelke, W., Schwarzwäller, W., Behnsen, A., & Jacobs, H. G. (2003). Subantrosopic laterobasal sinus floor augmentation (SALSA): an up-to-5-year clinical study. *International Journal of Oral & Maxillofacial Implants*, 18(1), 135-143.
  46. Gennaro, P., Chisci, G., Gabriele, G., & Iannetti, G. (2014). Conservative surgical and microsurgical techniques for the management of dental implants that impinge on the inferior alveolar nerve. *British Journal of Oral and Maxillofacial Surgery*, 52(6), 566-568.
  47. Sachdeva, S., Goyal, J., Jaiswal, R., Gill, S., Chaudhry, S., & Kochar, D. (2015). Periodontal microsurgery: A leap in surgical intervention. *The Saint's International Dental Journal*, 1(2), 78-81.